

საქართველოს გრ.მუხადის ქირურგთა ასოციაცია
საქართველოს მედიცინის მეცნიერებათა აკადემია
თბილისის სახელმწიფო სამედიცინო უნივერსიტეტი

გურამ ტატიშვილის საქართველოს ქირურგიის მაცნე

№14-15

საერთაშორისო ინდექსირებადი, რეცენზირებადი
სამეცნიერო-პრაქტიკული ჟურნალი

თბილისი, 2026

გურამ ტატიშვილის საქართველოს ქირურგიის მაცნე

საერთაშორისო ინდექსირებადი, რეცენზირებადი სამეცნიერო-პრაქტიკული ჟურნალი
გამოიცემს 2016 წლიდან წელიწადში ორჯერ
ჟურნალი რეფერირებულია „ქართულ რეფერატულ ჟურნალში“
www.techinformi.ge (საქართველოს ტექნიკური უნივერსიტეტი, ინსტიტუტი ტექნიკური)
DOI: <https://doi.org/10.48412/GTBGS.2026.14-15>

მთავარი რედაქტორი: | დავით ჯიქია

სარედაქციო კოლეგია:	გ.არაბიძე ნ.ფრუიძე თ.ჩართოლანი	კ.ქაშიბაძე მ.ერემიშვილი გ. ლობჯანიძე
----------------------------	--------------------------------------	--

სარედაქციო საბჭო:	დ.აბულაძე მ.ადამეცი (ჩეხეთი) გ.ახალაძე (რუსეთი) ლ.ახმეტელი, თსსუ ზ.ბახუტაშვილი გ.გიორგობიანი რ.გრუსნერი (აშშ) გ.დათუაშვილი, თსსუ მ.ზიმლიცკი, თსსუ გ.თომაძე, თსსუ (თავმჯდომარე) მ.კილაძე, თსუ დ.კორძია, თსუ ი.კონრეიძე, თსსუ	ი.კუზანოვი, თსსუ ნ.ლომიძე, თსსუ კ.მარდალეიშვილი, თსსუ ი.ნატროშვილი, თსსუ გ.ნემსაძე ა.რეკორდარე (იტალია) მ.ტატიშვილი კ.ქუნთელია, თსსუ კ.ყიფიანი, თსსუ ბ.ჩაკვეტაძე თ.ჩხიკვაძე რ.ხეცურიანი, თსსუ შ.ჯაფარიძე, თსსუ
--------------------------	---	--

დამფუძნებლები: | საქართველოს გრ.მუხაძის ქირურგთა ასოციაცია,
საქართველოს მედიცინის მეცნიერებათა აკადემია,
თბილისის სახელმწიფო სამედიცინო უნივერსიტეტი

გამომცემელი: | საქართველოს გრ.მუხაძის ქირურგთა ასოციაცია

ჟურნალში შუქდება თანამედროვე ქირურგიის და მომიჯნავე დარგების სამეცნიერო-პრაქტიკული მნიშვნელობის კვლევების შედეგები, მათი კლინიკური და თეორიული ასპექტები, ახალი ტექნოლოგიები, სამედიცინო განათლების პრობლემები, შემთხვევები კლინიკური პრაქტიკიდან, ქირურგიის ისტორიის გამორჩეული მოვლენები, გრ.მუხაძის საქართველოს ქირურგთა ასოციაციის საქმიანობის ქრონიკა და სხვა აქტუალური თემები.

რედაქციის აზრი შეიძლება არ ემთხვეოდეს ავტორთა მოსაზრებას. ყველა უფლება ავტორებისგან მასალების მიღების შემდეგ ეკუთვნის ჟურნალ „გ.ტატიშვილის საქართველოს ქირურგიის მაცნეს“ რედაქციას. რედაქცია პასუხს არ აგებს სარეკლამო მასალების შინაარსზე. ჟურნალში გამოქვეყნებული მასალების სრული ან ნაწილობრივი აღწარმოება ან გამრავლება, მეტოდის მიუხედავად, დასაშვებია მხოლოდ გამომცემლის წერილობითი ნებართვით.

რედაქციის მისამართი: თბილისი, 0179, ჭავჭავაძის 33ბ, „პრემიუმ მედსერვისი“
www.surgery.edu.ge | geosurgery@gmail.com

პრეპრესი და ბეჭდვა: კობა კურტანიძე, თბილისი, 0180, ზ.ჯორჯაძის 43
kobakurtanidze@gmail.com

ტირაჟი: 500

UDC (უაკ)617(051)(479.22)ს-323

ISSN 2449-2221

© საქართველოს გრ.მუხაძის ქირურგთა ასოციაცია

Gr.Mukhadze Georgian Association of Surgeons
Academy of Medical Sciences of Georgia
Tbilisi State Medical University

GURAM TATISHVILI BULLETIN OF GEORGIA SURGERY

№14-15

International Indexed, Peer-reviewed
Scientific-Practical Journal

Tbilisi, 2026

GURAM TATISHVILI BULLETIN OF GEORGIA SURGERY

International Indexed, Peer-reviewed Scientific-Practical Journal

Published since 2016, twice a year

The journal is reviewed in Georgian Abstracts Journal

www.techinformi.ge (Institute Techinformi of the Georgian Technical University)

DOI: <https://doi.org/10.48412/GTBGS.2026.14-15>

Editor-in-chief:	Jikia D.	
Editorial team:	Arabadze G. Pruidze N. Silogava L.	Kashbadze K. Eremeishvili M. Lobzhanidze G.
Editorial board:	Abuladze D. Adamec M. (Czech) Akhaldze G. (Russia) Akhmeteli L., TSMU Bakhutashvili Z. Chakvetadze B. Chkhikvadze T. Datuashvili G., TSMU Giorgobiani G. Gruessner R. (USA) Japaridze S., TSMU Khetsuriani R., TSMU Kiladze M., TSU	Kipiani K., TSMU Kokhraidze I., TSMU Kordzaia D., TSU Kuntelia K., TSMU Kuzanov I., TSMU Lomidze N., TSMU Mardaleishvili K., TSMU Natroshvili I., TSMU Nemsadze G. Recordare A. (Italy) Tatishvili M. Tomadze G., TSMU (Chairman) Zimlitski M., TSMU
Founders:	Gr.Mukhadze Georgian Association of Surgeons, Academy of Medical Sciences of Georgia Tbilisi State Medical University	
Publisher:	Gr.Mukhadze Georgian Association of Surgeons	

The results of scientific-practical researches of the modern surgery and adjacent fields, their clinical and theoretical aspects, new technologies, problems of medical education, cases from clinical practice, exceptional events of the history of surgery, chronic of the activities of Gr. Mukhadze Scientific Society of Surgeons and other actual topics, are highlighted in the journal.

The opinion of the editorial team may not coincide with the authors' consideration. All the rights from the authors after getting the materials belong to the editorial team of the journal "G. Tatishvili Bulletin of Georgia Surgery". The editorial team is not responsible for the contents of the advertising materials. Full or partial reproduction or copying of the materials published in the journal, despite of the method, is allowed only through the publisher's written permission.

Editorial office address: 33b Chavchavadze Ave., Premium Med Service, Tbilisi, 0179, Georgia
www.surgery.edu.ge | geosurgery@gmail.com

Prepress and Printing: Koba Kurtanidze, 43 Z. Jorjadze st., Tbilisi, 0180, Georgia
kobakurtanidze@gmail.com

Copies: 500

UDC (უკვ)617(051)(479.22)ს-323

ISSN 2449-2221

© Gr.Mukhadze Georgian Association of Surgeons

სარჩევი | CONTENTS

რედაქტორის წინასიტყვაობა	6
REVIEW OF CHALLENGES AND SYSTEMIC GAPS IN ORGANIZING SURGICAL SERVICES IN REGIONAL CLINICS <i>Merab Tatishvili, Tamaz Chkhikvadze, David Jikia</i>	7
რეგიონულ კლინიკებში ქირურგიული მომსახურების ორგანიზების გამოწვევების და სისტემური ხარვეზების მიმოხილვა <i>მერაბ ტატიშვილი, თამაზ ჩხიკვაძე, დავით ჯიქია</i>	15
SURGICAL TREATMENT OF GIANT, COMPLEX VENTRAL HERNIAS <i>Givi Chikobava, Amiran Antadze, Nino Chikobava, Malkhaz Chubinidze</i>	16
გიგანტური, რთული ვენტრალური თიაქრების ქირურგიული მკურნალობა <i>გივი ჩიქობავა, ამირან ანთაძე, ნინო ჩიქობავა, მალხაზ ჩუბინიძე</i>	24
RARE COMPLICATION - DEVELOPMENT OF AN ABDOMINAL WALL PSEUDOCYST AFTER INCISIONAL HERNIA REPAIR WITH MESH: A CASE REPORT <i>Enzar Diasamidze, Elguja Ardia, Giorgi Antadze, Tamaz Gvenetadze</i>	25
იშვიათი გართულება - მუცლის კედლის ფსევდოციკისტის განვითარება ინციზიური თიაქრის ზალით კლასტიკის შემდეგ <i>ემზარ დიასამიძე, ელგუჯა არდია, გიორგი ანთაძე, თამაზ გვენეტაძე</i>	28
POSTOPERATIVE HEMORRHAGE CAUSED BY UNDIAGNOSED VON WILLEBRAND DISEASE: A CLINICAL CASE REPORT <i>Davit Vardosanidze, Besarion Iremashvili, Zaza Demetrashvili, Lali Akhmeteli, Liana Saginashvili</i>	29
ფონ ვილენბრანდის არადიაგნოსტირებული დაავადებით გამოწვეული პოსტოპერაციული სისხლდენა. კლინიკური შემთხვევის აღწერა <i>დავით ვარდოსანიძე, ბესარიონ ირემაშვილი, ზაზა დემეტრაშვილი, ლალი ახმეტელი, ლიანა საგინაშვილი</i>	33
SIMULTANEOUS PERFORATION OF THE ANTERIOR AND POSTERIOR WALLS OF THE STOMACH: A RARE CLINICAL CASE REPORT <i>Elguja Ardia, Avtandil Megreladze, Gia Tomadze, Teimuraz Sesitashvili</i>	34
ქუშის წინა და უკანა კედლის წყლულების ერთდროული პერფორაცია: იშვიათი კლინიკური შემთხვევის აღწერა <i>ელგუჯა არდია, ავთანდილ მეგრელაძე, გია თომაძე, თეიმურაზ სესიტაშვილი</i>	37
A RARE CASE OF GASTRIC VOLVULUS <i>Gia Azmaiparashvili, Gia Tomadze, Avtandil Megreladze, Baadur Kikalia, Manuchar Gvatadze, Mamuka Goletiani, Alexander Gvazava</i>	38
ქუშის შემოგრების იშვიათი შემთხვევა <i>გია აზმაიპარაშვილი, გია თომაძე, ავთანდილ მეგრელაძე, ბაადურ კიკალია, მანუჩარ გვათაძე, მამუკა გოლეტიანი, ალექსანდრე გვაზავა</i>	40
BILE DUCT INJURY AFTER LAPAROSCOPIC CHOLECYSTECTOMY AND METHODS OF PREVENTION OF THIS COMPLICATION - CASE REPORT <i>Nika Khetagurova, Irakli Pipia, Giorgi Kopadze, Anano Tvaladze, Grigol Nemsadze, Zaza Demetrashvili</i>	41
სანაღვლე სადინრის დაზიანება ლაპაროსკოპიული ქოლესისტექტომიის შემდეგ და ამ გართულების პრევენციის მიმოხილვა <i>(კლინიკური შემთხვევის აღწერა)</i> <i>ნიკა ხეტაგუროვა, ირაკლი ფიფია, გიორგი კოპაძე, ანანო თვალაძე, გრიგოლ ნემსაძე, ზაზა დემეტრაშვილი</i>	47
FEATURES OF OPEN SURGICAL TRACHEOSTOMY IN INTENSIVE CARE UNIT (ICU) PATIENTS <i>Theimuraz Sesitashvili, Gia Tomadze, Ana Tsirekidze, Avthandil Megreladze</i>	48
ღია ქირურგიული ტრაქეოსტომიის თავისებურებები რეანიმაციული განყოფილების პაციენტებში <i>თეიმურაზ სესიტაშვილი, გია თომაძე, ანა ცირეკიძე, ავთანდილ მეგრელაძე</i>	50
CARCINOID TUMOR OF THE APPENDIX (NEUROENDOCRINE TUMOR OF THE APPENDIX) IN THE SETTING OF ACUTE APPENDICITIS: A CLINICAL CASE OF A 19-YEAR-OLD PATIENT <i>Kakhaber Kikvidze, Sergio Abramian, Gia Chukhua, David Butkhuzi, Solomon Kerashvili</i>	51
აპენდიქსის კარცინოიდული სიმსივნე (ქიანაწალის ნეიროენდოკრინული სიმსივნე) მწვავე აპენდიციტის ფონზე: 19 წლის პაციენტის კლინიკური შემთხვევა <i>კახაბერ კიკვიძე, სერგო აბრამიანი, გია ჩუხუა, დავით ბუტხუზი, სოლომონ ქერაშვილი</i>	54
EN BLOC TUMOR RESECTION AND ILIAC ARTERY RECONSTRUCTION USING ILO-FEMORAL BYPASS IN A HEAVILY PRETREATED PATIENT WITH RECURRENT ENDOMETRIAL CANCER: A CASE REPORT <i>Shota Mebonia, George Jinchveladze, Guram Vardishvili, Ivane Kiladze, Sandro Tsikarishvili, Aleksandre Gelashvili</i>	55
რეტროპერიტონეალური სიმსივნის ამოკვეთა ერთ ბლოკში და სისხლძარღვოვანი რეკონსტრუქცია <i>თეძო-ზარაძის არტერიების უნტირებით ენდოპროთეზის სიმსივნის რეციდივის შემთხვევაში: შემთხვევის აღწერა</i> <i>შოთა მებონია, გიორგი ჯინჭველაძე, გურამ ვარდიშვილი, ივანე კილაძე, სანდრო წიქარიშვილი, ალექსანდრე გელაშვილი</i>	58
THE IMPACT OF COMPUTER-ASSISTED NAVIGATED TOTAL KNEE ARTHROPLASTY ON OPERATIVE TIME <i>George Tchumburidze, Lkhum Tchanturia, Irakli Gogokhia</i>	59
მუცლის სასრის კომპიუტერული ნავიგაციით ენდოპროთეზირების უპირატესობის გაკვლევა საოპერაციო დროის შაქტორზე <i>გიორგი ჭუმბურიძე, ლუხუმ ტანტურია, ირაკლი გოგოხია</i>	63
MULTIDISCIPLINARY MANAGEMENT OF AN OPEN DISTAL TIBIAL FRACTURE: A CASE REPORT <i>Nikoloz Avazashvili, Levan Chikvatia, Krupa Sara Thomas, Divina Mariya Puthoaran</i>	64
წვივის ძვლის ღია მოტეხილობის მკურნალობის ტაქტიკა (საინტენსივო შემთხვევის აღწერა) <i>ნიკოლოზ ავაშვილი, ლევან ჩიკვატია, კრუპა სარა ტომას, დივინა მარია პუტორან</i>	68
INNOVATIVE APPROACHES FOR OPTIMIZING THE TREATMENT OF ARTHROSIS WITH AUTOLOGOUS ADIPOSE TISSUE STROMAL-VASCULAR FRACTION (SVF) TRANSPLANTATION <i>Shalva Gabadadze, Givi Chikobava, Davit Kochiashvili, Alexandre Tsalughelashvili, Irakli Nadiradze, Malkhaz Pirpilashvili, Tamaz Kerdzevadze</i>	69
ინოვაციური მიდგომები ართროზის ავთვისებიანი ცხიმოვანი ქსოვილის სტრომულ-ვასკულური შრატის (SVF) ტრანსპლანტაციით მკურნალობის ოპტიმიზაციისთვის <i>შალვა გაბადაძე, გივი ჩიქობავა, დავით კოჩიაშვილი, ალექსანდრე ცალუღელაშვილი, ირაკლი ნადირაძე, მალხაზ ფირფილაშვილი, თამაზ კერძევაძე</i>	77

THE EFFECT OF BARIATRIC SURGERY ON LIPID PROFILE AND LIVER FUNCTION IN PATIENTS WITH TYPE 2 DIABETES <i>Tamar Shervashidze, Rusudan Kvanchakhadze, David Abuladze, Liana Jashi, Miranda Shervashidze, Iamze Taboridze</i>	78
ბარიატრიული ჰირურგიის ეფექტი ლიპიდურ პროფილსა და ღვიძლის ფუნქციაზე ტიპი 2 დიაბეტის მქონე პაციენტებში <i>თამარ შერვაშიძე, რუსუდან კვანჭახაძე, დავით აბულაძე, ლია ჯაში, მირანდა შერვაშიძე, იამზე თაბორიძე</i>	82
A CASE OF MALIGNANT PERITONEAL MESOTHELIOMA AND ACUTE KIDNEY FAILURE FOLLOWING VIRAL INFECTION IN A MANGANESE MINER <i>Nino Chagiasvili, Nino Potckhverashvili, Gia Tomadze, Marita Gugunava, Tamar Chagiasvili</i>	83
პირუსული ინფექციის შემდეგ მანიფესტირებული აკუტის ნეფრიტი პერიტონეალური მემბრანული მემბრანული მემბრანის და თირკმლის მწვავე უკმარისობის შემთხვევა მანგანუმის საბალოზე მომუშავე პირთან (შემთხვევის აღწერა) <i>ნინო ჭაღიაშვილი, ნინო ფოცხვერაშვილი, გია თომაძე, მარიატა გუგუნავა, თამარ ჭაღიაშვილი</i>	86
HEART FAILURE WITH PRESERVED LEFT VENTRICULAR EJECTION FRACTION IN PATIENTS WITH NORMAL SINUS RHYTHM AND ATRIAL FIBRILLATION: THE COMPARISON OF RISK FACTORS, SYMPTOMS, LABORATORY FINDINGS, AND ECHOCARDIOGRAPHIC PARAMETERS OF RIGHT VENTRICULAR DYSFUNCTION <i>Sergo Kobalava, Mikheil Tsverava</i>	87
მარცხენა პარაჰუტის შენახული კუმოზული უსუნთქვით მიმდინარე გულის ქრონიკული უკმარისობა პაციენტებში სინუსური რიტმის და წინაგულთა ფიბრილაციის დროს <i>სერგო კობალავა, მიხეილ წვერავა</i>	99
PERINDOPRIL IN PATIENTS WITH HEART FAILURE REDUCED EJECTION FRACTION - HFrEF <i>Natia Nazghaidze, Solomon Zeikidze, Archil Chukhruidze, Zviad Kereselidze, Shalva Petriashvili</i>	100
პერინდოპრილი გულის უკმარისობის მქონე პაციენტებში შემცირებული განდევნის ურატებით - HFrEF <i>ნათია ნაზღაიძე, სოლომონ ზეიციძე, არჩილ ჩუხრუიძე, ზვიად კერესელიძე, შალვა პეტრიაშვილი</i>	106
HEART FAILURE AND ISCHEMIA <i>George Shaburishvili, Nikoloz Shaburishvili, Solomon Zeikidze</i>	107
გულის უკმარისობა და იშემია <i>გიორგი შაბურიშვილი, ნიკოლოზ შაბურიშვილი, სოლომონ ზეიციძე</i>	115
აპოპტოზის ჯორბენადის მოგონება	116
IN MEMORIAM AVTANDIL JORBENADZE	118
აპაფიტიკოსი მიხაილ ივანეს ძე ღვაჭიშვილი - სამედიცინო წარმომადგენელი	119
LETTER OF CONDOLENCE - ACADEMICIAN MIKHAIL IVANOVICH DAVYDOV	119

რედაქტორის წინასიტყვაობა

მოგესალმებით, წარმოგიდგინთ „გ. ტატიშვილის საქართველოს ქირურგიის მაცნეს“ გაერთიანებულ მე-14–15 ნომერს. გამოცემა ძალზე მრავალფეროვანია, ჟურნალში განხილულია მნიშვნელოვანი სისტემური და კლინიკური საკითხები.

ნომერი იხსნება სისტემური მიმოხილვით, რომელიც წარმოაჩენს რეგიონულ კლინიკებში ქირურგიული სერვისის კრიზისს (ქირურგ-სპეციალისტთა დეფიციტი, ანესთეზიოლოგიური ინფრასტრუქტურის სისუსტე, ემიგრაცია), რაც გლობალური პრობლემაა, თუმცა საქართველოში განსაკუთრებულ სიმძაფრეს იძენს.

ნომერში წარმოდგენილია „გიდმედის“ კლინიკური ჯგუფის, გიგანტური ვენტრალური თიაქრების დროს მუცლის წინა კედლის სეპარაციული რეკონსტრუქციული პლასტიკის (წინა, უკანა, ჰიბრიდული), ხუთწლიანი გამოცდილება (54 პაციენტი). ასევე, გთავაზობთ ბადით ჰერნიოპლასტიკის შემდეგ მუცლის კედლის ფსევდოკისტის განვითარების მეტად საინტერესო შემთხვევას. საყურადღებოა, ფონ ვილბერანდის დაავადების ფონზე განვითარებული პოსტოპერაციული სისხლდენის კლინიკური შემთხვევის აღწერა და შეფასება.

ნომერი მდიდარია იშვიათი კლინიკური სიტუაციებით: კუჭის წინა და უკანა კედლის ერთდროული პერფორაცია; კუჭის ვოლვულუსი, პოსტ-ნისენური ანამნეზის ფონზე; სანაღვლე სადინრის E3 დაზიანება ლაპარასკოპიული ქოლეცისტექტომიის შემდეგ მირიზის სინდრომის ფონზე; აპენდიქსის ნეიროენდოკრინული სიმსივნე 19 წლის პაციენტში და სხვ. თითოეული შემთხვევა — კლინიკური მსჯელობის, ანატომიური ცოდნისა და ინტერდისციპლინური თანამშრომლობის კარგი მაგალითია.

იმედს ვიტოვებთ, რომ ეს ნომერი ყველა პრაქტიკოსი ქირურგისთვის ღირებულ სამეცნიერო-კლინიკურ მასალას წარმოგიდგინებს.

„გურამ ტატიშვილის საქართველოს ქირურგიის მაცნეს“
მთავარი რედაქტორი დავით ჯიქია

REVIEW OF CHALLENGES AND SYSTEMIC GAPS IN ORGANIZING SURGICAL SERVICES IN REGIONAL CLINICS

Merab Tatishvili^{1,4}, Tamaz Chkhikvadze^{2,4}, David Jikia^{3,4}

¹Tbilisi State Medical University, Georgia; ²Alexandre Aladashvili clinic, Tbilisi, Georgia; ³Sagarejo Multiprofile Medical Center of "Geo Hospitals", Sagarejo, Georgia; ⁴Gr.Mukhadze Georgian Association of Surgeons, Georgia

Contact person: David Jikia, djikia@gh.ge

DOI: <https://doi.org/10.48412/GTBGS.2026.14-15.7-15>

Rezume

Background: Regional clinical centers hold a critical but often overlooked position in national surgical systems. These facilities are expected to provide a wide range of surgical care. This includes everything from emergency laparotomy to elective oncological procedures. However, they routinely operate amid structural underfunding, workforce attrition, and insufficient infrastructure. Georgia, a South Caucasus country in a post-Soviet healthcare transition, is a relevant case study. Following the introduction of Universal Health Coverage (UHC) in 2013, surgical access improved. Still, deep geographic and qualitative disparities between Tbilisi's tertiary centers and regional hospitals have remained or worsened.

Aim: This review aimed to synthesize existing evidence on the organizational structure, operational challenges, and outcome disparities of surgical services at regional clinical centers, with particular attention to the Georgian healthcare context and its alignment with international findings.

Methods: A systematic search was conducted across five electronic databases: PubMed, Scopus, Web of Science, Cochrane Library, and EMBASE. This was supplemented by grey literature from the World Health Organization, the Georgian National Center for Disease Control (NCDC), and the Georgian Ministry of Health. Searches took place in March 2026 and included publications from January 2005 to March 2026. Eligibility was limited to studies addressing surgical service organization, workforce, infrastructure, or outcomes at the non-tertiary regional level. The PRISMA 2020 framework guided all parts of study selection, data extraction, and quality appraisal. Quality was assessed using the Newcastle-Ottawa Scale (NOS) for observational studies, AMSTAR-2 for reviews, and Cochrane Risk of Bias for trials and prospective cohorts.

Results: Of the 3,921 initially identified records, 21 studies met the inclusion criteria. Studies were conducted in 34 countries across Africa, South/East Asia, Eastern Europe, and high-income comparators. Three Georgian-specific sources were identified, but all lacked methodological rigor. Key findings converged around five themes: critical deficits in regional surgeon numbers; infrastructure gaps affecting anesthesia and critical care; high unmet need in rural and peri-urban areas; limits and possibilities of task-sharing; and the economic case for investing in regional surgery. Georgian data, though limited, matched international patterns: fewer than 20% of elective procedures took place outside Tbilisi, and about 25% of trained surgeons worked abroad.

Conclusion: Widespread, interconnected structural failures limit surgical services in regional centers. Georgia's post-UHC experience shows that better financial access to surgery alone is not enough. There must also be investment in human resources, infrastructure, and quality oversight at the regional level. Evidence-based recommendations include setting regional capacity targets, creating a specialist retention program, mandating audit systems, and introducing a tiered referral protocol into UHC policy.

Key words: regional surgical services; healthcare systems organization; surgical workforce; LMICs; Georgia healthcare; post-Soviet health reform; surgical access disparities

INTRODUCTION

Surgical care has often been considered the prerogative of specialized medical centers in cities, which, paradoxically, has led to a greater or lesser degree of neglect of surgical infrastructure and service needs at the regional/district level worldwide for a long time. However, a large proportion of emergencies occur at the regional level. For example, trauma, perforation of internal organs, obstetric complications, etc., are represented by a smaller percentage in the coverage areas of specialized centers. The consequences of this discrepancy are very serious and measurable.

The Lancet Commission on Global Surgery (2015) concluded: "The global burden of disease amenable to surgical intervention, such as trauma, cancer, and complications from childbirth, is substantial and growing. Despite this, there are currently gross disparities in access to safe surgical care worldwide. Surgery is an integral, indivisible component of a properly functioning health system, and all people should have access to safe, high-quality surgical and anesthesia care with financial protection when needed." [1]. The Commission estimates that up to 5 billion people worldwide lack access to safe and affordable surgical services, and this severe challenge falls disproportionately

on rural and remote populations. Alkire et al. (2015) estimated that an additional 143 million surgical procedures are needed each year, most of which are concentrated in low- and middle-income countries, and that the failure to provide them results in an annual GDP loss equivalent to USD 12.3 trillion over the decade. These figures have lent urgency to a conversation that had previously sat at the margins of global health policy.

If we consider it systematically, regional clinical centers serve the population of regions/districts. They function as an intermediate link between specialized urban clinics and primary care centers. The main function of these regional centers is not only control, but also the provision of appropriate emergency services. Unfortunately, this often exceeds their capabilities. International evidence identifies common problems: too few surgeons per capita, limited anesthetic services, unreliable supply chains for surgical items, insufficient intensive care beds, and limited perioperative quality monitoring.

Georgia is a unique case in post-Soviet healthcare change. Since its independence in 1991, Georgia's health system has seen several reforms. In 2013, universal healthcare coverage expanded the right to publicly funded surgical care. Surgical volumes rose, and by 2018, over 80% of the population had health insurance. Still, the geography of surgical services within Georgia saw little real change. Data from the NCDC show elective surgical procedures remain focused in Tbilisi. Regional centers account for fewer than one-fifth of these procedures, though they serve more than half the population.

Several factors explain this gap. There is a post-Soviet history of centralized hospitals and specialized hierarchies. Medical workforce emigration hits regional areas hardest. Hospitals outside the capital continue to deteriorate physically. Current reimbursement models have not changed to support regional surgical delivery. These issues are common to Eastern European and Caucasian post-Soviet settings. However, a lack of peer-reviewed Georgian data makes analysis difficult and highlights an important evidence gap.

This review was prompted by recognition of serious, understudied problems in Georgia's regional surgical services. By bringing together international findings and Georgia's experiences, we aim to offer a practical framework. This can help clinicians, health administrators, and policymakers working in this context.

AIM

The main purpose of this systematic review was to assess the evidence on how surgical services are organized and the challenges faced in regional centers. A second objective was to place findings in the context of the Georgian health system. We aimed to answer three key questions:

- What structural and organizational factors most consistently predict inadequate surgical service delivery at the regional level?

- What evidence exists for effective interventions — whether workforce, infrastructure, or policy-based — in improving regional surgical capacity?
- To what extent do Georgian-specific data corroborate or diverge from international patterns, and what policy implications follow?

MATERIALS AND METHODS

Study Design and Reporting

This systematic review was conducted and reported in accordance with the Preferred Reporting Items for Systematic Reviews and Meta-Analyses (PRISMA) 2020 statement (Page et al., 2021). A prospective review protocol was registered prior to initiating the search. Given the heterogeneity of study designs and outcome definitions identified during preliminary scoping, a quantitative meta-analysis was not deemed appropriate; findings are therefore presented as a narrative synthesis structured around thematic domains.

Eligibility Criteria

Studies were eligible for inclusion if they: (a) addressed the organisation, delivery, capacity, or outcomes of surgical services at a regional, district, or sub-national non-tertiary clinical facility; (b) reported at least one quantifiable outcome related to surgical workforce, infrastructure, volume, quality, or access; (c) were published in English, Russian, or Georgian between January 2005 and March 2026; and (d) represented original research, systematic reviews, or formally validated institutional reports.

Studies were excluded if they: (a) focused exclusively on a single surgical specialty technique without reference to service-level organization; (b) were conducted solely in tertiary or academic medical centers without sub-analysis of regional services; (c) involved exclusively pediatric populations unless the service-level finding had direct adult-care applicability; or (d) were conference abstracts without accompanying peer-reviewed publication.

Information Sources and Search Strategy

Electronic searches were conducted across PubMed/MEDLINE, Scopus, Web of Science, the Cochrane Central Register of Controlled Trials (CENTRAL), and EMBASE. Searches were performed on 15 March 2026. The search strategy employed MeSH headings and free-text terms, including combinations of: 'surgical services', 'hospital organisation', 'regional hospital', 'district hospital', 'surgical capacity', 'surgical workforce', 'global surgery', 'healthcare access', 'post-Soviet healthcare', 'Georgia (country)', 'Caucasus', 'LMICs', 'rural surgery', and 'health system reform'. Boolean operators (AND/OR) and truncation were used systematically. Reference lists of included studies and relevant reviews were manually screened for additional eligible sources.

Grey literature was searched via the WHO Global Health Observatory, the World Bank Open Data repository, the Georgian National Center for Disease Control and

Table 1. Summary of Included Studies

First Author, Year	Country	Study Design	Population / Setting	Key Outcome(s)	Quality Score
Kingham et al., 2009	Sub-Saharan Africa (multi-country)	Cross-sectional survey	District hospitals; general surgeons	Surgical capacity gaps; shortage of trained surgeons; inadequate infrastructure	NOS: 6/9
Meara et al., 2010	LMICs (global)	Systematic review & modelling	Regional hospitals in LMICs	5 billion people lack access to safe, affordable surgical care	AMSTAR-2: Moderate
Alkire et al., 2015	Global (LMICs)	Economic modelling study	District/regional facilities	143 million additional procedures needed annually; GDP loss from surgical neglect	NOS: 7/9
Saluja et al., 2020	Ethiopia, Uganda, Zambia	Mixed-methods	District hospitals; surgical task-sharing	Task-sharing feasibility; outcomes comparable to specialist care for selected procedures	NOS: 6/9
Ozgediz & Riviello, 2008	LMICs (global)	Narrative review	Rural and regional hospitals	'Neglected global surgical crisis'; untreated surgical conditions cause substantial mortality	NOS: 5/9
Holmer et al., 2015	Global (194 countries)	Cross-sectional database analysis	National and regional surgical workforce data	Specialist surgical density <20 per 100,000 in many LMICs; strong correlation with outcomes	NOS: 7/9
Raykar et al., 2015	Global (Lancet Commission)	Commission report / modelling	District and regional level care	Surgery as essential for UHC; phased scale-up plan proposed	AMSTAR-2: High
Chu et al., 2009	Uganda (rural)	Retrospective cohort	Regional referral hospital surgical unit	High perioperative mortality; lack of monitoring equipment and anaesthesia as key factors	NOS: 6/9
Bhangu et al. (Global-Surg), 2016	Multi-country (73 countries)	International prospective cohort	Regional hospitals, mixed income settings	30-day mortality post-abdominal surgery 2x higher in LMICs vs HICs; anaesthesia & ICU deficits	Cochrane RoB: Low
Hider et al., 2019	Eastern Europe / Caucasus	Policy analysis	Post-Soviet health-care systems	Underfunded surgical services; rural-urban disparities; physician emigration	NOS: 5/9
Verguet et al., 2015	Sub-Saharan Africa	Cost-effectiveness analysis	District / first referral level	Surgical scale-up highly cost-effective; USD 10–100 per DALY averted	NOS: 6/9
Grimes et al., 2011	Ghana, Tanzania	Cross-sectional	Regional hospitals; surgical volume analysis	Low surgical volume; high unmet need; inadequate supply chains for surgical consumables	NOS: 6/9
Mukhopadhyay et al., 2017	India (rural/regional)	Cross-sectional & qualitative	District hospitals; primary surgical care	Staffing, infrastructure, and supply shortfalls comparable to Sub-Saharan settings	NOS: 6/9
Soreide et al., 2019	Norway (rural)	Retrospective cohort	Regional general surgery; rurality index	Rural-urban disparities in surgical access even within HICs; centralisation vs. local access tension	NOS: 7/9
Tansley et al., 2019	Sub-Saharan Africa	Systematic review	Surgical capacity building programmes	Training & mentorship increase surgical output; sustain impact beyond initial programme	AMSTAR-2: Moderate
Biccard et al., 2018	Africa (25 countries)	Prospective cohort (AfroSurg)	Regional referral hospitals	Postoperative mortality 2.9x higher in Africa vs global; critical care lack a dominant factor	Cochrane RoB: Low
Dare et al., 2014	Global (LMICs)	Modelling / burden of disease	Surgical and obstetric capacity	83 million people/year suffer due to lack of surgical care; disproportionate in rural regions	NOS: 6/9
NCDC Georgia Reports, 2018–2022	Georgia	National administrative data	Regional clinical centres; national registry	Surgical volume concentrated in Tbilisi; rural regions account for <20% of elective procedures	Descriptive only
Tsiskaridze et al., 2021	Georgia	Cross-sectional survey	Healthcare workforce; medical emigration	~25% of trained surgeons work outside Georgia; regional hospitals most affected	NOS: 5/9
Japaridze & Kvaratskhelia, 2020	Georgia	Policy review	Universal healthcare programme impact on surgery	UHC increased surgical coverage overall; rural access gap persists; emergency surgery underreported	NOS: 5/9

Table 2. PRISMA Flow Diagram (Tabular Representation)

PRISMA Stage	Records (n)	Notes / Reason for Exclusion
Identification – Database search	3,847	PubMed (1,621), Scopus (1,048), Web of Science (734), Cochrane (212), EMBASE (232)
Identification – Grey literature	74	WHO reports, Georgian NCDC publications, MoH policy documents, conference abstracts
After duplicate removal	2,891	956 duplicates removed
Title/Abstract screening	2,891	2,647 excluded (irrelevant topic, non-surgical focus, paediatric-only, non-regional setting)
Full-text assessed for eligibility	244	
Excluded at full-text	223	Reasons: (a) Exclusively tertiary/urban setting, n=87; (b) Single procedure focus unrelated to service organisation, n=54; (c) Insufficient outcome data, n=39; (d) Non-peer-reviewed without validation, n=28; (e) Language barrier without translation available, n=15
Studies included in synthesis	21	Quantitative synthesis: 18 studies; qualitative synthesis: 3 studies; Georgian-specific sources: 3

Public Health (NCDC), the Georgian Ministry of Labor, Health and Social Affairs official publications portal, and the European Observatory on Health Systems and Policies. The latter provided health system profile data for Georgia that, while not primary research, offered indispensable contextual framing (Richardson et al., 2014).

Study Selection

Studies were selected based on a review of titles and abstracts. Inconsistencies were then corrected after reviewing the full text. Potentially interesting texts were processed according to pre-agreed criteria summarized in Table 2.

Data Extraction

A standardized data extraction form was applied to all included studies, capturing: lead author and year; country and setting; study design and population; primary and secondary outcomes; key quantitative findings; and methodological quality appraisal score. For studies reporting Georgian-specific data, an additional extraction field documented the institutional source and data validation method.

Quality Assessment

Observational studies were appraised using the Newcastle-Ottawa Scale (NOS), which rates studies across three domains: selection of study groups, comparability, and outcome assessment (a maximum of 9 stars). Systematic reviews were evaluated with AMSTAR-2. Prospective cohort studies with defined protocols were assessed using the Cochrane Risk of Bias tool (RoB 2.0). Quality scores are reported in Table 1. Studies scoring below 4/9 on the NOS (or equivalent threshold on other tools) were retained in the synthesis but flagged in the discussion as potentially unreliable.

Synthesis Approach

Given substantial heterogeneity in study design, population, setting, and outcome definitions, a formal me-

ta-analysis was not conducted. Instead, a thematic narrative synthesis was employed, following the framework proposed by Popay et al. (2006). Themes were developed inductively from the data and iteratively refined through reviewer consensus. Quantitative findings are reported as extracted from primary sources and juxtaposed across studies to identify convergent and divergent patterns.

RESULTS

Study Identification and Selection (PRISMA Flow)

The initial database search retrieved 3,847 records. An additional 74 records were identified through grey literature and manual reference checking. After de-duplication (n = 956 removed), 2,891 unique records underwent title and abstract screening. Of these, 2,647 were excluded as clearly irrelevant — primarily because they addressed exclusively tertiary care, single-technique surgical outcomes, or non-human research. A total of 244 full-text articles were retrieved for eligibility assessment.

Full-text review led to the exclusion of 223 studies, the most common reasons being: exclusive focus on tertiary or academic settings without regional sub-analysis (n = 87); single-procedure orientation without service-level generalisability (n = 54); insufficient quantitative outcome data for meaningful synthesis (n = 39); grey literature sources lacking methodological validation (n = 28); and language barrier despite translation efforts (n = 15). The final synthesis incorporated 21 sources: 18 peer-reviewed studies or systematic reviews, and 3 Georgian-specific institutional or administrative sources. Table 2 presents the full PRISMA flow in tabular form, and Table 1 provides a structured overview of included studies.

Characteristics of Included Studies

Included studies spanned a broad geographic and methodological range. In terms of design, the corpus included: six cross-sectional surveys or capacity assessments; four systematic reviews or commission reports;

four prospective multi-center cohort studies (including two large international collaborative studies — GlobalSurg and AfroSurg); two retrospective cohort analyses; two economic modeling studies; two policy or health systems analyses; and one mixed-methods study. Geographically, 11 studies focused on Sub-Saharan Africa, three on South or Southeast Asia, two on high-income comparator settings (Norway, United Kingdom), one on a broad Eastern Europe/Caucasus policy domain, and three specifically on Georgia. Study populations ranged from individual regional hospitals to national and multi-country datasets. Sample sizes spanned from single-site audits of a few hundred cases to multi-country datasets exceeding 11,000 patients. Table 1 summarizes the included studies.

Key Findings by Thematic Domain

Theme 1: Surgical Workforce Deficits at the Regional Level

The most consistently documented finding across all included studies was the inadequacy of surgical workforce density at regional, district, and non-tertiary facility levels. Holmer et al. (2015), in a landmark cross-national analysis covering 194 countries, demonstrated that specialist surgical density falls below 20 surgeons per 100,000 population in the majority of LMICs, with the lowest densities systematically concentrated outside major urban centers. The Lancet Commission on Global Surgery (Meara et al., 2015; Raykar et al., 2015) set a minimum benchmark of 20 surgical, anesthetic, and obstetric providers per 100,000 population — a threshold unmet by 77 countries at the time of publication and largely unaddressed in subsequent assessments.

In the Georgian context, Tsiskaridze et al. (2021) conducted a survey of the domestic surgical workforce. They estimated that approximately 25% of Georgian-trained surgeons are currently employed outside the country, with regional hospitals experiencing the most acute retention failures. This figure is consistent with documented patterns of healthcare worker emigration from post-Soviet states, where salary differentials, limited professional development, and inadequate equipment create structural push factors that disproportionately affect the periphery. Hider et al. (2019), analyzing Eastern European and Caucasian health systems broadly, characterized rural and regional surgeon shortages as 'a defining feature' of the post-Soviet surgical system, driven by the historic concentration of specialist training and practice in capital cities.

Theme 2: Infrastructure and Anesthesia Deficits

Inadequate anesthetic capacity was identified as a critical bottleneck across multiple study designs and geographic contexts. Chu et al. (2009), in a retrospective analysis of perioperative mortality at a regional referral hospital in Uganda, attributed the majority of preventable deaths to intraoperative monitoring failures and anesthetic complications arising from equipment deficits rather than surgical technique error per se. The GlobalSurg Collaborative (Bhangu et al., 2016), drawing on 73-country

data, found that 30-day postoperative mortality following abdominal surgery was more than twice as high in LMICs compared to high-income countries, with multivariable analysis identifying anesthesia provider ratio and ICU bed availability as the two strongest institutional predictors.

Biccard et al. (2018), through the AfroSurg network, replicated these findings in 25 African countries, reporting a postoperative mortality rate nearly three times the global average in African regional hospitals, with a critical care deficit as the dominant explanatory variable. Grimes et al. (2011) documented comparable findings in Ghana and Tanzania, where unreliable oxygen supply, absent pulse oximetry, and shortages of essential anesthetic agents rendered routine elective surgery perioperatively high-risk. For Georgia, published anesthetic capacity data from regional hospitals are absent from the peer-reviewed literature; however, NCDC administrative data suggest that a significant proportion of regional centers lack continuous anesthetic specialist coverage, and that anesthesia for major cases is frequently deferred pending specialist availability from Tbilisi.

Theme 3: Unmet Surgical Need and Geographic Inequity

Dare et al. (2014) estimated that 83 million people globally suffer annually from conditions for which surgical care is indicated but not received, with the burden concentrated in rural and peri-urban populations. Alkire et al. (2015) calculated that this unmet need results in an annual economic loss of USD 12.3 trillion over the decade, primarily through premature mortality, disability-adjusted life years, and loss of productive capacity. These global estimates find partial corroboration in Georgian administrative data: NCDC reports from 2018 to 2022 indicate that elective surgical procedures are performed in Tbilisi in more than 80% of cases nationally, despite the capital housing approximately 28% of the Georgian population.

Japaridze and Kvaratskhelia (2020) assessed the impact of Georgia's UHC program on surgical access. They found that emergency surgical admissions increased significantly in regional hospitals following the 2013 reform — a finding consistent with the program's removal of out-of-pocket barriers — but that elective surgical backlogs in regional centers grew proportionally, suggesting that demand materialized faster than capacity was built. The geographic concentration of surgical volume in the capital reflects not only workforce maldistribution but also patient-driven referral preferences rooted in longstanding perceptions of quality differentials between regional and Tbilisi-based institutions.

Theme 4: Task-Sharing and Workforce Innovation

A growing body of evidence, primarily from Sub-Saharan Africa, has examined the potential of task-sharing as a strategy to extend surgical capacity in resource-limited regional settings. Saluja et al. (2020), in a mixed-methods study across Ethiopia, Uganda, and Zambia, demonstrated that non-physician clinicians trained in selected operative procedures achieved outcomes statistically comparable to

specialist surgeons for common conditions, including herniorrhaphy, appendectomy, and cesarean section. Tansley et al. (2019), in a systematic review of capacity-building interventions, found that structured mentorship and training programs sustained increases in surgical volume beyond the duration of the initial intervention in 70% of reviewed programs.

The applicability of task-sharing models to Georgia requires careful contextualization. Unlike Sub-Saharan settings where physician-level training resources are fundamentally scarce, the Georgian system retains a broadly physician-based healthcare tradition and sufficient medical school output. The dominant barrier is not a lack of medical graduates per se, but rather the failure to retain trained surgeons in regional posts and the absence of continuing professional development infrastructure outside Tbilisi. Task-sharing in the Georgian context is therefore more likely to take the form of supervised scope-of-practice expansion for regional general surgeons into sub-specialist domains, rather than the delegation of operative tasks to non-physician providers.

Theme 5: Economic Argument for Regional Surgical Investment

Verguet et al. (2015) conducted a cost-effectiveness analysis of surgical scale-up at the district and first-referral level in Sub-Saharan Africa, finding that investment in regional surgical capacity averted disability-adjusted life years for USD 10 to 100 per DALY — a threshold widely considered highly cost-effective by international standards. Soreide et al. (2019), examining rural-urban surgical disparities in Norway, demonstrated that even in a well-resourced, high-income country, geographic distance to surgical care meaningfully increased morbidity for time-sensitive conditions, including acute appendicitis and perforated ulcers, suggesting that centralization models incur measurable health costs that economic analyses must account for. These findings collectively reinforce the argument that underinvestment in regional surgical capacity is not fiscally neutral — it transfers costs onto emergency services, generates preventable long-term disability expenditure, and imposes indirect economic losses through workforce incapacitation.

Discussion

Interpretation of Core Findings

The convergence of evidence across 21 heterogeneous studies — spanning four continents, a range of income settings, and multiple methodological approaches — is striking and clinically important. It suggests that the structural challenges confronting regional surgical services are not idiosyncratic failures of particular health systems but predictable consequences of identifiable policy and investment decisions. At their core, these challenges involve three mutually reinforcing dynamics: the concentration of surgical training and specialist careers in urban centers; the chronic underfunding of regional hospital infrastruc-

ture; and the absence of quality monitoring mechanisms that would otherwise create accountability pressure for improvement.

The fact that these same dynamics recur whether one examines a rural Ugandan district hospital (Chu et al., 2009), a Ghanaian regional facility (Grimes et al., 2011), or a Georgian regional clinical center (NCDC, 2018–2022) points toward structural drivers that transcend specific cultural, geographic, or economic contexts. This convergence is analytically useful because it implies that effective interventions in one setting may offer transferable lessons, adjusted for context, to others.

The Georgian Healthcare Context in International Perspective

Georgia's position within this international landscape is that of a country caught between the formal policy achievements of UHC expansion and the persistent reality of delivery inequity. The 2013 UHC reform was, by multiple accounts, a landmark advance: it eliminated the most severe financial barriers to access to surgical care, particularly for emergency and oncological conditions. Japaridze and Kvaratskhelia (2020) documented tangible improvements in emergency surgical admission rates, and qualitative reports suggest reduced catastrophic household expenditure on surgical episodes in the post-reform period.

However, the reform addressed the demand side of surgical access without proportional investment in the supply side — particularly at the regional level. The result is structurally analogous to what Meara et al. (2015) described as 'coverage without capacity': a system in which formal entitlement to surgical care exists but is undermined by geographic inaccessibility, workforce shortages, and quality uncertainty. The NCDC data pattern, with fewer than 20% of elective procedures performed outside Tbilisi, is not merely a statistical artifact. It reflects a rational patient and clinician response to real quality differentials: when regional centers lack the specialist staff, anesthetic reliability, and ICU capacity to manage complex cases safely, both patients and referring physicians default to Tbilisi — creating a self-reinforcing cycle of underutilization and further disinvestment at the regional level.

The workforce emigration finding reported by Tsiskaridze et al. (2021) adds a further dimension. An estimated 25% of Georgian-trained surgeons working abroad is a substantial figure for a country of approximately 3.7 million people; even if partially attributable to the documented trend of Georgian diaspora healthcare professionals, it represents a significant loss of trained human capital that the regional system, in particular, cannot absorb. International evidence (Holmer et al., 2015; Hider et al., 2019) consistently shows that physician emigration from post-Soviet states disproportionately depletes the regional rather than the capital-city workforce, as those who emigrate are often precisely the younger, more adaptable professionals who might otherwise have populated regional posts.

Systemic and Healthcare Organizational Considerations

Analyzing the Georgian situation through the lens of health system frameworks reveals several systemic tensions that complicate straightforward policy prescription. First, the UHC reimbursement model, as currently structured, reimburses procedures at national tariff rates that may not adequately reflect the higher per-unit cost of providing safe surgical care at lower-volume regional institutions. This creates a financial disincentive for regional hospitals to perform complex surgery and incentivizes referral upstream — a pattern documented in analogous settings by Ozgediz and Riviello (2008) under the rubric of the 'neglected surgical crisis'.

Second, the regulatory and accreditation framework for regional surgical departments in Georgia remains weakly developed. Unlike Tbilisi-based institutions — many of which are now subject to international accreditation processes as part of medical tourism development — regional hospitals are rarely subjected to formal surgical quality audit or external review. This absence of quality accountability removes an important lever for improvement and makes it structurally difficult to detect, let alone address, deteriorations in perioperative safety at the regional level. The GlobalSurg and AfroSurg collaborative studies (Bhangu et al., 2016; Biccard et al., 2018) demonstrated that standardized outcome data collection at regional facilities is both feasible and actionable — findings that have direct relevance for a Georgian national audit initiative, should one be pursued.

Third, the spatial organization of surgical care in Georgia has not been systematically evaluated against population need. A rigorous needs assessment, comparing the geographic distribution of surgically remediable conditions with the current distribution of surgical capacity, would be essential groundwork for rational regional planning. Such assessments have been conducted in several African contexts (Grimes et al., 2011; Dare et al., 2014) with direct policy impact; their absence in Georgia represents a missed planning opportunity.

Limitations

This review has several notable limitations that must be acknowledged. Most fundamentally, the scarcity of peer-reviewed, methodologically rigorous surgical data from Georgia itself severely constrains the strength of conclusions that can be drawn about the Georgian context specifically. The three Georgian-specific sources incorporated into this review were administrative or policy documents with limited methodological reporting; none met the threshold for a Newcastle-Ottawa score of 6 or higher. This is not a criticism of those sources per se — they represent the best available evidence — but it underscores the urgent need for original primary research on the organization of the Georgian surgical system.

Second, the international literature, while now substantial, remains skewed toward Sub-Saharan African and South Asian settings, with Eastern European and Caucasian post-Soviet contexts substantially underrepresented. The

extrapolation of findings from, for example, rural Uganda to regional Georgia must be done with caution, given the different historical trajectories, baseline physician density, and health system structural characteristics involved.

Third, the narrative synthesis approach, while appropriate given study heterogeneity, is less statistically robust than formal meta-analysis. Thematic conclusions reflect reviewer judgment in pattern recognition across studies, and alternative thematic structures could reasonably have been imposed on the same data. We have attempted to mitigate this by maintaining close fidelity to quantitative findings within each theme.

Practical Implications for Clinicians

For clinicians practicing at the regional level in Georgia, this review affirms several evidence-based practical imperatives. First, the development and use of local complication and outcome tracking — however rudimentary — is both feasible and valuable. The AfroSurg experience (Biccard et al., 2018) demonstrated that simple perioperative mortality recording at regional hospitals, when aggregated, generates actionable evidence for system-level improvement. Georgian regional surgeons do not need to wait for national policy directives to begin this process. Second, structured clinical mentorship between Tbilisi-based tertiary specialists and regional surgical teams, modeled on evidence from the African task-sharing literature (Tansley et al., 2019), could meaningfully expand regional operative scope without requiring additional staffing.

Third, advocacy for regional surgical infrastructure investment — framed in the economic terms demonstrated by Verguet et al. (2015) and Alkire et al. (2015) — is itself a clinical responsibility. The evidence that regional surgical investment is cost-effective is now robust enough to constitute a policy-relevant argument that clinicians are well-positioned to make.

Conclusion

Regional surgical services globally are constrained by predictable, intersecting, and — critically — addressable structural failures. This systematic review has synthesized 21 studies from diverse geographic and methodological contexts to identify five thematic pillars of this challenge: workforce density deficits, infrastructure and anesthetic gaps, geographic inequity of access, the potential and limits of task-sharing, and the compelling economic case for regional surgical investment. Georgia's documented experience, while limited in peer-reviewed depth, is consistent with these international patterns: a UHC reform that broadened formal access without proportional regional infrastructure investment has produced a coverage-without-capacity dynamic, with surgical care remaining effectively inaccessible to large portions of the population outside Tbilisi.

Based on this evidence, the following recommendations are advanced for Georgia:

- **Establish national benchmarks for regional surgical capacity** — including minimum surgeon density, anesthetic specialist coverage, and essential equipment standards — aligned with Lancet Commission thresholds and monitored through the NCDC.
 - **Develop a structured specialist retention program** for regional posts, incorporating financial incentives, continuing medical education access, and career progression pathways comparable to Tbilisi-based positions.
 - **Implement a mandatory regional surgical audit system**, beginning with perioperative mortality and 30-day re-admission tracking, to create accountability and generate the primary data currently absent from Georgian surgical literature.
 - **Revise the UHC reimbursement model** to reflect the genuine cost of safe regional surgical practice, removing the current financial disincentives for complex case management outside Tbilisi.
 - **Commission a national surgical needs assessment** mapping surgically remediable disease burden against current regional service capacity, to enable evidence-based resource allocation.
- The organization of surgical services in regional clinical centers is not a peripheral concern in health systems — it is a core determinant of preventable mortality and morbidity for the majority of the Georgian population. The evidence assembled here makes that case with sufficient clarity to warrant urgent policy attention.

ACKNOWLEDGEMENTS:

Manuscript preparation was supported by AI-assisted drafting (Claude, Anthropic) and language editing tools (Grammarly). All content, citations, and analytical interpretations were independently verified and approved by the authors.

References:

1. Alkire, B. C., Raykar, N. P., Shrima, M. G., Weiser, T. G., Bickler, S. W., Rose, J. A., ... Meara, J. G. (2015). Global access to surgical care: A modelling study. *The Lancet Global Health*, 3(6), e316–e323. [https://doi.org/10.1016/S2214-109X\(15\)70115-4](https://doi.org/10.1016/S2214-109X(15)70115-4)
2. Bhangu, A., & GlobalSurg Collaborative. (2016). Mortality of emergency abdominal surgery in high-, middle- and low-income countries. *British Journal of Surgery*, 103(8), 971–988. <https://doi.org/10.1002/bjs.10151>
3. Biccard, B. M., Madiba, T. E., Kluyts, H. L., & African Surgical Outcomes Study (ASOS) Investigators. (2018). Perioperative patient outcomes in the African Surgical Outcomes Study: A 7-day prospective observational cohort study. *The Lancet*, 391(10130), 1589–1598. [https://doi.org/10.1016/S0140-6736\(18\)30001-1](https://doi.org/10.1016/S0140-6736(18)30001-1)
4. Chu, K., Rosseel, P., Gielis, P., & Ford, N. (2009). Surgical task shifting in sub-Saharan Africa. *PLoS Medicine*, 6(5), e1000078. <https://doi.org/10.1371/journal.pmed.1000078>
5. Dare, A. J., Grimes, C. E., Gillies, R., Greenberg, S. L. M., Hagander, L., Meara, J. G., & Leather, A. J. M. (2014). Global surgery: Defining an emerging global health field. *The Lancet*, 384(9961), 2245–2247. [https://doi.org/10.1016/S0140-6736\(14\)60237-5](https://doi.org/10.1016/S0140-6736(14)60237-5)
6. Grimes, C. E., Law, R. S., Borgstein, E. S., Mkwandawire, N. C., & Lavy, C. B. D. (2011). Systematic review of met and unmet need of surgical disease in rural sub-Saharan Africa. *World Journal of Surgery*, 36(1), 8–23. <https://doi.org/10.1007/s00268-011-1330-1>
7. Hider, P., Mishra, P., & Tomlinson, J. (2019). Health system reforms in post-Soviet Eastern Europe and the Caucasus: Patterns, progress and persistent challenges. *International Journal of Health Planning and Management*, 34(1), e46–e61. <https://doi.org/10.1002/hpm.2630>
8. Holmer, H., Lantz, A., Kunjumen, T., Finlayson, S., Hoyler, M., Siyam, A., ... Hagander, L. (2015). Global distribution of surgeons, anaesthesiologists, and obstetricians. *The Lancet Global Health*, 3(Suppl 2), S9–S11. [https://doi.org/10.1016/S2214-109X\(15\)70060-4](https://doi.org/10.1016/S2214-109X(15)70060-4)
9. Japaridze, M., & Kvaratskhelia, N. (2020). Universal health coverage and surgical access in Georgia: Policy review and implementation challenges. *Georgian Medical News*, (302), 145–152.
10. Kingham, T. P., Kamara, T. B., Cherian, M. N., Gosselin, R. A., Simkins, M., Meissner, P., ... Kushner, A. L. (2009). Quantifying surgical capacity in Sierra Leone: A guide for improving surgical care. *Archives of Surgery*, 144(2), 122–127. <https://doi.org/10.1001/archsurg.2008.540>
11. Meara, J. G., Leather, A. J. M., Hagander, L., Alkire, B. C., Alonso, N., Ameh, E. A., ... Yip, W. (2015). Global Surgery 2030: Evidence and solutions for achieving health, welfare, and economic development. *The Lancet*, 386(9993), 569–624. [https://doi.org/10.1016/S0140-6736\(15\)60160-X](https://doi.org/10.1016/S0140-6736(15)60160-X)
12. Mukhopadhyay, A., Glover, A. L., Bhatt, S., Iyer, A. A., & Sreevalsan-Nair, J. (2017). Surgical capacity in India's rural district hospitals: A cross-sectional assessment. *World Journal of Surgery*, 41(6), 1413–1421. <https://doi.org/10.1007/s00268-016-3856-0>
13. National Centre for Disease Control and Public Health of Georgia (NCDC). (2022). *Health statistics of Georgia, 2018–2022*. Tbilisi: NCDC Publishing.
14. Ozgediz, D., & Riviello, R. (2008). The 'other' neglected diseases in global public health: Surgical conditions in sub-Saharan Africa. *PLoS Medicine*, 5(6), e121. <https://doi.org/10.1371/journal.pmed.0050121>
15. Page, M. J., McKenzie, J. E., Bossuyt, P. M., Boutron, I., Hoffmann, T. C., Mulrow, C. D., ... Moher, D. (2021). The PRISMA 2020 statement: An updated guideline for reporting systematic reviews. *BMJ*, 372, n71. <https://doi.org/10.1136/bmj.n71>
16. Popay, J., Roberts, H., Sowden, A., Petticrew, M., Arai, L., Rodgers, M., & Britten, N. (2006). *Guidance on the conduct of narrative synthesis in systematic reviews: A product from the ESRC Methods Programme*. Lancaster University.
17. Raykar, N. P., Yorlets, R. R., Liu, C., Greenberg, S. L. M., Meara, J. G., & Shrima, M. G. (2015). A qualitative study exploring contextual challenges to surgical care provision at district hospitals in 8 countries. *BMJ Global Health*, 1(2), e000075.

<https://doi.org/10.1136/bmjgh-2016-000075>

18. Richardson, E., Berdzuli, N., & Mossialos, E. (2014). Georgia: Health system review. *Health Systems in Transition*, 16(4), 1–184. *European Observatory on Health Systems and Policies*.
19. Saluja, S., Ng-Kamstra, J., Carroll, E., Watson, R. A., Gyamfi, A., & Meara, J. G. (2020). Task-sharing for surgical care in three African countries: A systematic mixed-methods review. *BMJ Global Health*, 5(4), e002181. <https://doi.org/10.1136/bmjgh-2019-002181>
20. Soreide, K., Desserud, K. F., Korner, H., Watson, R. A., & Driscoll, P. A. (2019). Rural access to surgical care and outcomes: Lessons from Norway for global health. *World Journal of Surgery*, 43(2), 365–373. <https://doi.org/10.1007/s00268-018-4815-7>
21. Tansley, G., Aziz, S., Christie, S. A., & Saluja, S. (2019). Systematic review of interventions to improve surgical capacity in low- and middle-income countries. *BMJ Global Health*, 4(1), e001282. <https://doi.org/10.1136/bmjgh-2018-001282>
22. Tsiskaridze, A., Kereselidze, M., & Macharashvili, N. (2021). Medical workforce emigration from Georgia: Scale, patterns, and healthcare system implications. *Georgian Medical News*, (318), 201–208.
23. Verguet, S., Alkire, B. C., Bhatt, S., Bhutta, Z. A., Black, R. E., Gawande, A. A., ... Jamison, D. T. (2015). Timing and cost of scaling up surgical services in low- and middle-income countries from 2012 to 2030: A modelling study. *The Lancet Global Health*, 3(Suppl 2), S28–S37. [https://doi.org/10.1016/S2214-109X\(15\)70086-0](https://doi.org/10.1016/S2214-109X(15)70086-0)

რეგიონულ კლინიკებში ქირურგიული მომსახურების ორგანიზების გამომწვევების და სისტემური ხარვეზების მიმოხილვა

მერაბ ტატიშვილი^{1,4}, თამაზ ჩხიკვაძე^{1,2}, დავით ჯიქია^{3,4}

¹თბილისის სახლმწიფო სამედიცინო უნივერსიტეტი, საქართველო; ²ალექსანდრე ალადაშვილის კლინიკა, თბილისი, საქართველო; ³შპს „ჯეოპოსპიტალის“ საგარეჯოს მრავალპროფილური სამედიცინო ცენტრი; ⁴საქართველოს გრ.მუხაძის ქირურგთა ასოციაცია, საქართველო

პასუხისმგებელი პირი: დავით ჯიქია, djikia@gh.ge

DOI: <https://doi.org/10.48412/GTBGS.2026.14-15.7-15>

რეზიუმე შესავალი: ქირურგიული დახმარება ხშირად განიხილება როგორც საქალაქო სპეციალიზებული სამედიცინო ცენტრების პრერეგაცივა, რამაც, თითქოს პარადოქსულად, ხანგრძლივი დროის მანძილზე განაპირობა ქირურგიული ინფრასტრუქტურის და მთლიანად სერვისის საჭიროებების მეტ-ნაკლები ხარისხით უგულვებელყოფა რეგიონულ დონეზე, მთელს მსოფლიოში. თუმცა, გადაუდებელი მდგომარეობების დიდი ნაწილი, სწორედ რეგიონულ დონეზე ვლინდება. მაგალითად, ტრავმები, შინაგანი ორგანოების პერფორაცია, სამედიცინო გართულებები და სხვ. ნაკლები პროცენტითაა წარმოდგენილი სპეციალიზებული ცენტრების დაფარვის ზონებში. ამ შესაბამისი შედეგები ძალზე მძიმეა და გაზომვადი. საქართველოში პოსტსაბჭოთა პერიოდში განხორციელდა რამდენიმე რეფორმა, რამაც გააუმჯობესა წვდომა ქირურგიულ მომსახურებაზე. ამის მიუხედავად თბილისის ცენტრებსა და რეგიონულ საავადმყოფოებს შორის ღრმა გეოგრაფიული და თვისებრივი უთანასწორობა შენარჩუნდა ან ზოგ შემთხვევაში გაუარესდა.

მიზანი: ამ მიმოხილვის მიზანი იყო არსებული მტკიცებულებების მოძიება რეგიონულ კლინიკებში ქირურგიული სერვისის საორგანიზაციო სტრუქტურის, გამოწვევებისა და შედეგების შესახებ.

მეთოდები: ძიება ჩატარდა ხუთ ელექტრონულ მონაცემთა ბაზაში: PubMed, Scopus, Web of Science, Cochrane Library და EMBASE. ამას დაემატა ჯანდაცვის მსოფლიო ორგანიზაციის, საქართველოს დაავადებათა კონტროლის ეროვნული ცენტრის (NCD) და საქართველოს ჯანდაცვის სამინისტროს ვებ-გვერდებზე განთავსებული ლიტერატურა. 2026 წლის მარტში ჩატარდა და მოიცავდა პუბლიკაციებს 2005 წლის იანვრიდან 2026 წლის მარტამდე. შესარჩევი კრიტერიუმები შემოიფარგლებოდა ქირურგიული მომსახურების ორგანიზაციის, სამუშაო ძალის, ინფრასტრუქტურის შესახებ ინფორმაციით. შერჩევის, მონაცემთა მოპოვებისა და ხარისხის შეფასების ყველა ნაწილი მოქცა PRISMA 2020 ჩარჩოში. ხარისხი შეფასდა ნიუკასლ-ოტავას შკალის (NOS) გამოყენებით.

შედეგები: თავდაპირველად მოძიებული 3,921 ჩანაწერიდან 21 კვლევა აკმაყოფილებდა ჩართვის კრიტერიუმებს. კვლევები ჩატარდა აფრიკის, სამხრეთ/აღმოსავლეთ აზიის, აღმოსავლეთ ევროპის 34 ქვეყანაში და მალალი შემოსავლის მქონე შედარებით ქვეყნებში. გამოვლინდა საქართველოსთვის სპეციფიკური 3 წყარო, თუმცა ყველა მათგანს აკლდა მეთოდოლოგიური სიზუსტე. ძირითადი დასკვნები გაერთიანდა 5 თემად: რეგიონული ქირურგიის რაოდენობის კრიტიკული დეფიციტი; ინფრასტრუქტურის ხარვეზები, რომლებიც გავლენას ახდენს ანესთეზიასა და კრიტიკულ მკურნალობაზე; მალალი დაუკმაყოფილებელი საჭიროება სოფლის და ქალაქის გარეუბნებში; დაავადებების განაწილების შეზღუდვები და შესაძლებლობები; და რეგიონულ ქირურგიაში ინვესტირების ეკონომიკური დასაბუთება. საქართველოს მონაცემები, თუმცა შეზღუდული, შესაბამისობა საერთაშორისო ტენდენციებს: მაგალითად, გეგმიური პროცედურების მხოლოდ 20%-ზე ნაკლები ტარდება თბილისის გარეთ.

დასკვნა: ფართოდ გავრცელებული, ურთიერთდაკავშირებული სტრუქტურული ჩავარდნები რეგიონულ ცენტრებში ქირურგიულ მომსახურებას ზღუდავს. გამოცდილება აჩვენებს, რომ აუცილებელია ინვესტიციების განხორციელება ადამიანურ რესურსებში, ინფრასტრუქტურასა და ხარისხის ზედამხედველობაში რეგიონულ დონეზე.

მტკიცებულებებზე დაფუძნებული რეკომენდაციები: რეგიონული კლინიკის შესაძლებლობების სამიზნეობის იდენტიფიცირება, სპეციალისტების შენარჩუნების პროგრამის შექმნა, სავალდებულო აუდიტის სისტემების შექმნა და სხვ.

საკვანძო სიტყვები: რეგიონული ქირურგიული სერვისები; ქირურგიული კადრები; დაბალი და საშუალო შემოსავლის მქონე ქვეყნები; საქართველოს ჯანდაცვა; პოსტსაბჭოთა ჯანდაცვის რეფორმა; ქირურგიულ ხელმისაწვდომობის უთანასწორობა.

SURGICAL TREATMENT OF GIANT, COMPLEX VENTRAL HERNIAS

Component Separation Technique (CST) of large, giant postoperative hernias of the anterior abdominal wall. 5 years of experience of Gidmed LLC

Givi Chikobava, Amiran Antadze, Nino Chikobava, Malkhaz Chubinidze.

Joint Georgian-Israeli Clinic "Gidmed"

Contact person: Givi Chikobava, givi_chikobava@hotmail.com

DOI: <https://doi.org/10.48412/GBGS.2026.14-15.16-24>

Resume

Objective: To evaluate the effectiveness and implementation of a new surgical method for the treatment of large, recurrent, and complex ventral hernias (hernia defect horizontal diameter >8–10 cm)—namely, anterior abdominal wall component separation reconstructive plasty (anterior, posterior, and hybrid approaches)—at “Guidmed” Clinic.

Materials and Methods: The essence of the method consists of the elimination of giant and complex hernias through separation of the anatomical components of the anterior abdominal wall, followed by reconstructive component separation with mesh reinforcement. Over the past five years, 54 patients underwent surgical treatment using anterior component separation technique (ACST), posterior component separation technique (PCST), or a hybrid approach.

The study evaluated the necessary conditions for surgical management of complex hernias (as surgery is not indicated in all cases), the essential factors contributing to hernia development, and the required technical aspects of anterior, posterior, and hybrid component separation reconstruction. The clinic developed its own hybrid component separation reconstructive technique. Between 2019 and 2025, 54 operations were performed at “Guidmed” Clinic for large, complex, and postoperative ventral hernias ($w > 8-10$ cm). Of these, 32 were performed using anterior component separation (ACST); 10 using posterior component separation reconstruction (GCST), including 6 according to the Carbonell method and 4 according to the Novitsky method; and 12 using a hybrid approach (sublay technique combined with fasciotomy). Recurrence occurred in 3 cases.

Conclusion: Anterior, posterior, and hybrid component separation reconstructive techniques are all acceptable, modern, and reliable methods for the surgical treatment of large and complex ventral hernias ($w > 8-10$ cm). However, the choice of technique should be individualized based on the patient’s general condition, comorbidities, age, disease duration, surgeon’s expertise, and optimal timing of surgery. In cases of recurrence, regardless of the method used in the initial operation, posterior component separation—particularly GCST and TAR techniques—should be preferred for reoperation.

Key words: hernia, giant hernia, complex ventral hernia, CST (component separation technique)

INTRODUCTION:

Surgical treatment of hernias spans more than a century. However, despite this, it remains problematic today, especially the surgical treatment of large and postoperative ventral hernias, because it is often associated with a sharp reduction in the total volume of the abdominal cavity, which in turn leads to a disruption in the normal functioning of vital systems and, no less importantly, difficulties in operating. In the USA, on average, 1 million surgeries are done per year due to hernias of the anterior abdominal wall. The increase in quantity was caused by the generally higher number of laparotomies, which was driven by advances in diagnostic technologies, anesthesiology, and postoperative intensive care. In the same USA, according to registry data, 11-19% of hernias develop after laparotomy per year, which is an average of 350,000 operations. For comparison, 400,000 cholecystectomies are performed each year. (According to registry data, 15% of the population on our planet develops a hernia, and 13% develops calculous cholecystitis) [1, 2, 3].

A big part of the operations is done with the diagnosis of postoperative and recurrent hernias. According to many authors’ data, the rate is 10-60%, and the majority of recurrences occur during the first year after surgery. The recurrence rate after surgery for large giant hernias is 53%. Therefore, great importance is attached to modern tactics [4] and the mastery of complex surgical techniques to meet the main requirement: reducing postoperative recurrence and improving quality of life [5, 6].

The history of surgical treatment of hernias includes several stages. In the first stage, plastic surgery was performed using the patient's own tissues, based on the mandatory tightening of the latter. This latter was proportional to the size of the hernial orifice, of course, plastic surgery of large hernias using only local tissues was often impossible, because internal pressure of abdomen was sharply increased by such plastic surgery, which used to end up with the possible development of abdominal compartment syndrome and fatal complications (respiratory failure, distress, cardiovascular failure, thromboembolism, obstruction, etc.). That is why managing the operation of so-called




Figure 1. Usher F. (Hernia repair with Marlex mesh Usher, Francis C. et al. Surgery, Volume 46, Issue 4, 718 - 724)

big, giant, mainly post-surgical recurrent hernias was frequently impossible [7, 8].

Second stage, in other words, a new era in plastic surgery of Hernia began in 1950 (non-massive), when Francis Usher first used an organic prosthesis to close a ventral hernia defect. After this, with the development of prosthetic material production and improvements in its quality, its use began in USA and then in Europe in the 1970s. Today, up to 4 million meshes are used worldwide each year for this purpose [9] (Figure 1).

Lichtenstein and his clinic have made great contributions to improving the tactics and procedures for the sur-

gical treatment of hernias. They distinguish the following forms of ventral hernia mesh repair (Figure 2):

Onlay - The mesh is sutured to the external surface of the rectus muscle aponeurosis.

Inlay - The mesh is sutured to the inner surface of the aponeurosis, between the rectus muscle and the aponeurosis.

Underlay - The mesh is sutured beneath the rectus muscle, between the muscle and the posterior layer of the aponeurosis (which is often inseparable from the parietal peritoneum and therefore referred to as the "sublay").

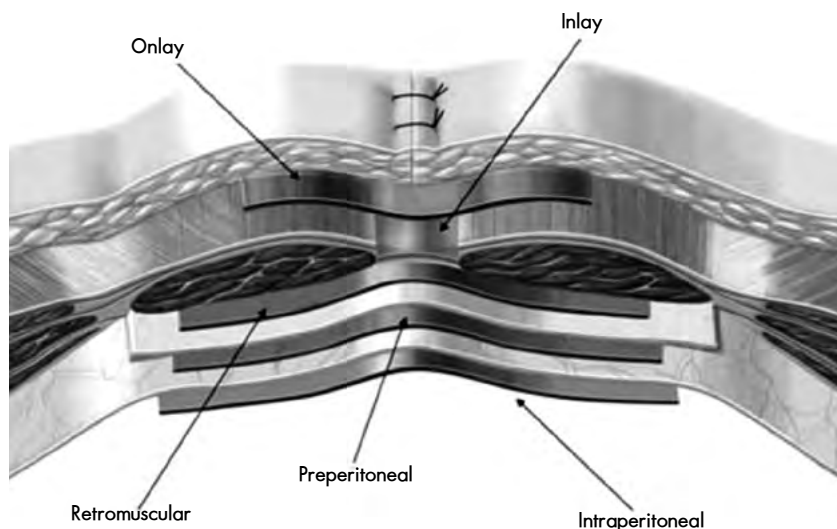


Figure 2. EurahS terminology of mesh positions during ventral hernia (F.E. Muysoms et al., 2012)

Sublay - The mesh is sutured beneath the posterior aponeurotic layer of the rectus muscle, between it and the parietal peritoneum.

Interperitoneal - The mesh is sutured on the inner side of the parietal peritoneum.

Our work concerns large (giant), postoperative hernias - the so-called "complex hernias". The classification proposed by Chevrelle and Rath in 2000 was recognized and adopted by the EHS Incisional Hernia Classification. According to this classification, the characteristic parameter of the hernia size was the transverse, horizontal, and not the longitudinal (vertical) size of the hernial orifice. According to this classification (according to transversal size of the hernias after surgery), W1 - 4-5 cm - small and average size, W2 - 4-8 cm average and big; W3 - more than 10 cm - big (giant); Hernias according to localization - Middle (M), Lateral (L), Merged (Combined ML); Also, the increase in the number of laparoscopic surgeries in the 20th century led to the addition of so-called trocar site hernias, and if they are multiple, they are classified as complex hernias. In 2009, the XXXVI Conference of the Eu-

ropean Association of Herniologists included multiple hernias of the anterior abdominal wall in the group of complex hernias [10, 11, 12] (picture 3 - A,B,C and picture 4).

Later, the study of the frequency and clinical course of operations has allowed us to explain the mechanisms of complications with postoperative hernias (hernia disease is caused by a violation of the complex muscle-fascia-muscle synergism, resulting from inhibition of collagen metabolism combined with mechanical impact). As a result, the development of a hernia occurs due to damage to the fascia. [14.] Today, it is no longer controversial that for the operation of large, postoperative hernias, it is not enough to know only the transverse size of the hernial orifice; in addition, the degree of abdominal reduction (displacement of visceral organs into the hernia sac), genetic predisposition, immunodepression, duration of the disease, concomitant diseases, and increased intra-abdominal pressure (IAP) are of great importance. Therefore, most surgeons believe that a combination of factors causes hernia development, and it is now called hernia disease. Classical methods of operation for a giant hernia

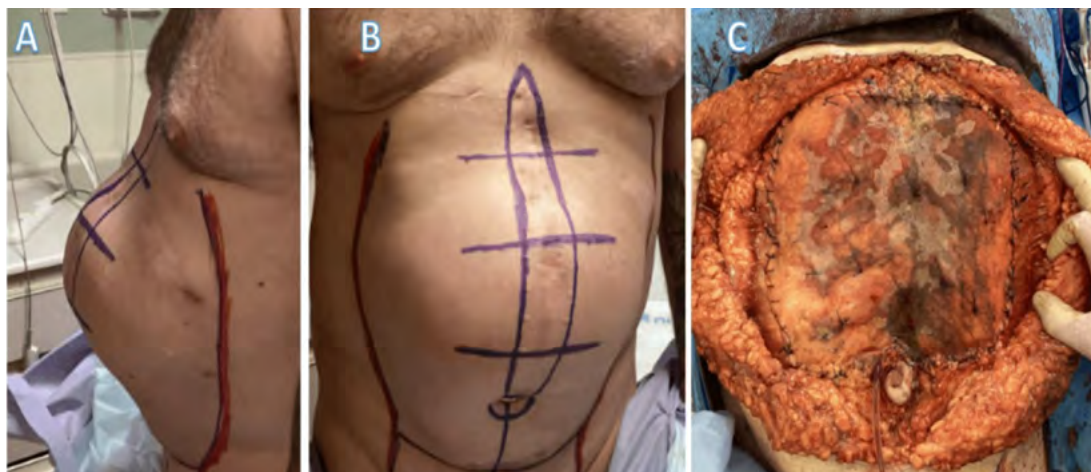


Figure 3.

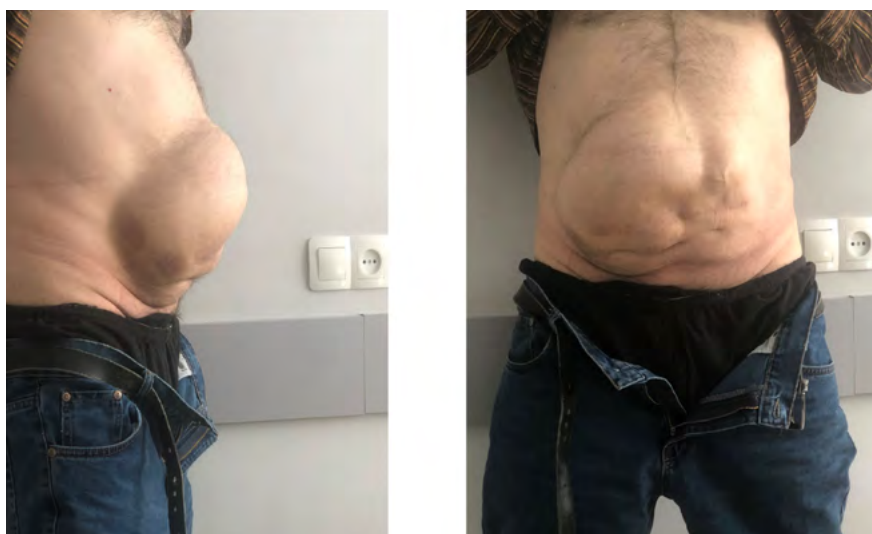

Figure 4.

include the sublay and onlay techniques. In such a case, plastic surgery with tightening does not yield the desired result because the return of the protruding organs into the abdominal cavity increases intra-abdominal pressure, or, in other words, intra-abdominal hypertension, which leads to the development of compartment syndrome and organ dysfunction [15, 16]. In this regard, the inlay method of surgery, as a non-stretching plastic of the anterior abdominal wall, was considered a relatively better method, although the intra-abdominal pressure (IAP) with this method cannot always remain within the desired limits (its optimal values are 8-13 mm.Hg; However, some surgeons believe that the operation can be completed with a thickness of 18 mmHg (this corresponds to 30 mm of water column).

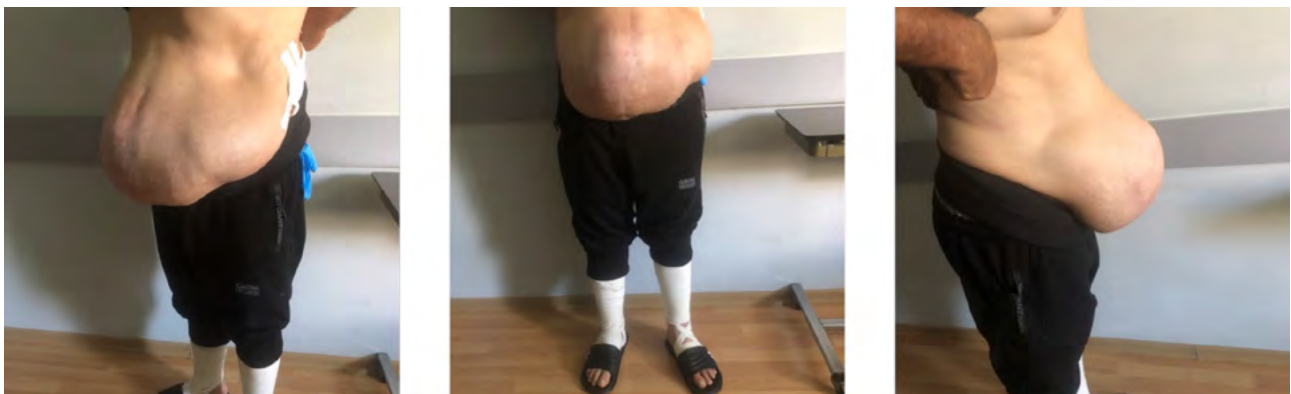

Figure 5.

Considering reliability and anatomical and functional properties, an intervention is acceptable when we restore the muscular-aponeurotic apparatus of the anterior abdominal wall, close to the true anatomical structure, by implanting a mesh of appropriate size while maintaining the normal volume of intra-abdominal pressure. This approach is now called separation reconstruction of the anterior abdominal wall (Abdominal wall reconstruction - VWR). This method is based on the separation of the anatomical components of the anterior wall and the surgical technique (components separation technique - CSI) [18]. A distinction is made between anterior (anterior components separation technique - ACST) and posterior (posterior components separation technique - PCST) separation [19, 20, 21]. A Mexican plastic surgeon proposed the first one - Ramirez [22, 23] with a mesh and without a mesh (Figure 6).

Moreover, the second one, posterior wall separation, is relatively new. It was proposed in 2008 that Carbonell A and a group of authors were the first to publish their work in the journal *Hernia*, where, along with the division of the anterior abdominal wall components, dissection of the deep layers was provided, and it was called the posterior separation method as a whole [24]. Unlike standard dissection of the retromuscular space, here, regardless of the size and number of hernial orifices, the muscles are completely dissected, the space between the internal oblique and transverse muscles is precisely identified and

The third stage of ventral hernia repair has arrived. Previous surgeries failed to restore the anatomical and functional integrity of the anterior abdominal wall muscles. The rectus muscles remain laterally stretched and immobile, and, as a result, atrophy and lose function. Over time, the structure and metabolism of the muscles and connective tissue change. Unfortunately, chronic inflammation develops at the site of implant-tissue contact, preventing the formation of connective tissue and leaving the muscle tissue incomplete. Therefore, in cases of large and postoperative hernias, it is very difficult to achieve the desired results with the generally accepted hernioplasty techniques (Onlay and Inlay) [17] (Figure 5).

entered smoothly, with maximum preservation of the epigastric perforant nerves and blood vessels.

In 2012-2013, the group of USA surgeons under the leadership of Novitsky Y.W. developed and put into practice a relatively modernized surgical method called trans-versus abdominis release (TAR) [25]. Unlike the Carbonell method, it requires a vertical dissection of the lateral edge of the posterior rectus sheath and the transverse muscle, thereby achieving maximum mobility of the rectus, transverse, and aponeurotic-fascial plate (Figure 7).

Nowadays, this method is considered a leading approach for prosthetic repair of large ventral hernias. Most authors agree that posterior abdominoplasty reduces the number of recurrences and other complications and maintains functional integrity [26]. However, over time, the transverse muscle atrophies, while the internal oblique and rectus muscles hypertrophy (in a compensatory manner). When comparing anterior and posterior separations, wound complications, bleeding, hematoma, and seroma are of particular concern during ACST. However, according to data from some surgeons, there is no significant difference in recurrence rates between ACST and PCST [27] (Figure 8, 9).

Therefore, it remains unequivocal that treating giant and postoperative hernias only with the TAR method, due to the complex surgical intervention and large volume of the operation, will probably not be correct.

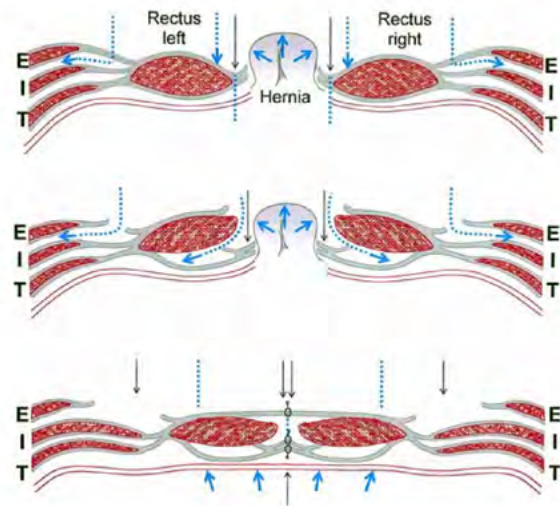


Figure 6. Components of anatomic separation technique by Ramirez modified after "Reoperative Aesthetic and Reconstructive Plastic Surgery" by James C. Grotting, Vol. II, 1995. Transversal view. E - external oblique muscle, I - internal oblique muscle, T - transversus abdominis muscle.

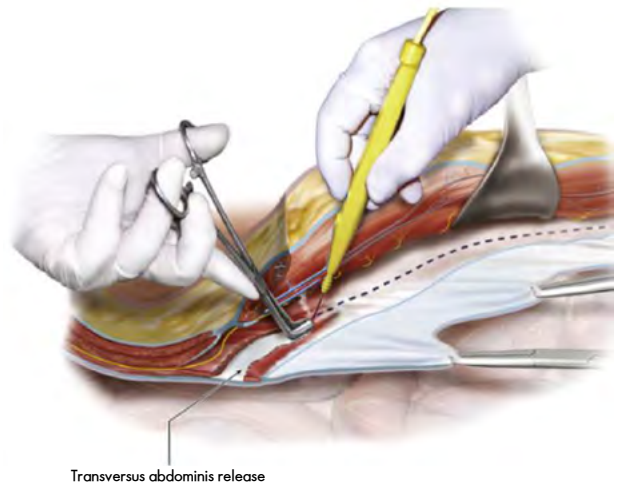


Figure 7. The transversus abdominis muscle is divided (Reprinted with permission from Novitsky Y.W.).

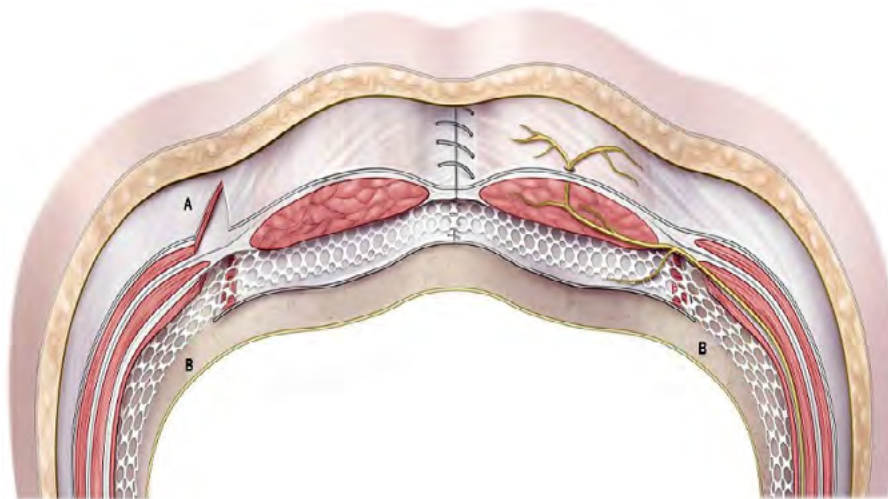


Figure 8. Schematic drawing of endoscopic component separation technique (A) and transversus abdominis release (B) (Scheuerlein, Hubert & Thiessen, Andreas & Schug-Paß, Christine & Köckerling, Ferdinand. (2018). What Do We Know About Component Separation Techniques for Abdominal Wall Hernia Repair?. *Frontiers in Surgery*, 5. 24. 10.3389/fsurg.2018.00024)

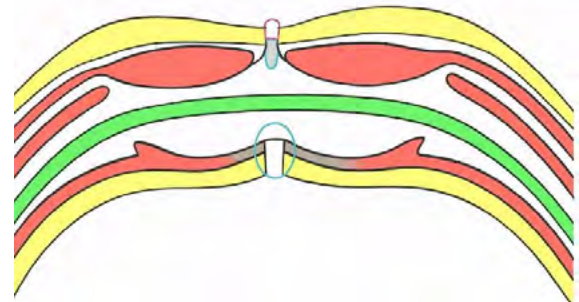
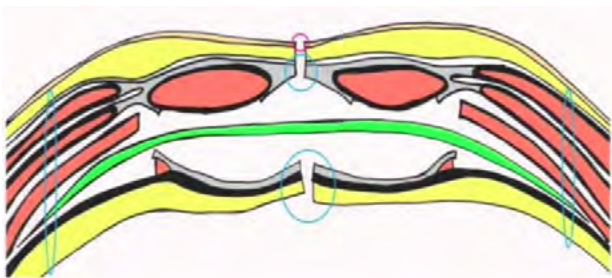


Figure 9. Diagram of TAR separation plastic and mesh arrangement (green) - (a) ACST (Anterior Component Separation Technique); (b) PCST (Posterior Component Separation Technique)

Therefore, today, many surgeons, taking into account the patient's age, comorbidities, and risks, favor hybrid separation reconstruction, which includes elements of both anterior and posterior separation, as well as sublay and inlay. Moreover, recent data indicate that many surgeons believe that operations performed with different CST variants yield approximately the same results when assessing quality-of-life parameters. In this regard, they are approximately equal.

As a result of modern data analysis, the optimal method for large and postoperative hernias has been identified: anterior wall reconstruction with separate prosthetic material, where the prosthesis is placed intramuscularly or, in exceptional cases, intraperitoneally, if an appropriate adhesive-coated mesh is available. TAR plastic surgery, which has been increasingly used recently, is a technically challenging surgical intervention that requires impeccable surgical technique, detailed knowledge of abdominal anatomy and its variants, and meticulous adherence to the sequence of surgical stages. All methods of TAR plastic surgery are effective, but today it is clear that PCST (Pectus Carinatum Surgery Technique) has advantages over ACST (Anterior Wall Ramirez) plastic surgery. PCST has difficulties and challenges for wider use, so many surgeons prefer ACST (Ramirez reconstruction), but in case of hernia recurrence, they definitely prefer PCST. The issue is complex, so further studies are necessary to provide medical evidence for the concept of separating plastic. Especially since during PCST and intraperitoneal mesh placement, the intra-abdominal pressure (IAP) is evenly distributed over every cm² of the anterior wall and, compared to ACST, the weak areas of the plastic are more protected; however, at present, the consensus is that W1 and W2 can be repaired laparoscopically and with ACST whenever possible, while complex hernias larger than 10 cm, i.e., W3, can only be repaired with GCST [28].

Purpose of work: Introduction of a relatively new surgical procedure, separation reconstruction, for the surgical treatment of large, giant postoperative hernias at the clinic "Gidmedi". Comparative analysis of anterior, posterior, and hybrid abdominal wall separation reconstruction—5-year follow-up of 54 patients after surgery, comparative analysis of results, short-term and long-term outcomes.

Patients and type of surgeries: In 2019-2024, we performed surgery on 54 patients with giant, postoperative, recurrent hernias of the anterior abdominal wall. (w>8-10cm) Age from 30 to 74, men - 32, women - 17.

Types of plastic:

1. Anterior separation reconstruction was performed in 32 patients, 7 of them with the Ramirez method, 25 of them with the Ramirez method added to fasciotomy with our modification;
2. Posterior separation reconstruction - 10, 6 of them with the Carbonell method and 4 of them with the Novitsky method;

3. With the hybrid method – 12, by the Sublay or Ramirez method, plus fasciotomy.

All operations were performed according to current requirements, namely:

1. Intra-abdominal pressure was measured before, during, and after the operation with a catheter inserted into the bladder;
2. In all cases, the muscles constituting the anterior wall were repositioned, i.e., returned to their normal anatomical-topographic location, and
3. inea alba was restored.

The postoperative period was satisfactory: In 1 case, the wound was complicated by hematoma, in 3 cases by seroma. In 2 patients, recurrence occurred (the operation was performed with anterior separation). In one, it was caused by a violation of the mesh's integrity along its entire length; in the other, by mesh shrinkage and detachment on one side. In both cases, posterior separation reconstruction was performed, with positive results. We also performed posterior reconstruction separation (TAR) plasty (not the Sabley method plasty performed by us - complicated by intestinal adhesions and microperforations).

Anterior separation

Ramirez's method, or in other words, Spiegel's, which involves incising the skin up to the crescent line and dissecting the subcutaneous fatty tissue and aponeurosis. If intra-abdominal pressure (IAP) does not decrease to 20 mmHg, the aponeuroses of both rectus muscle sheaths are dissected along their entire length. 30 x 30 cm mesh is placed on the line, and it is fixed on the aponeurosis with knotted sutures, with necessary fixation on the edges of the dissected aponeurosis.

Posterior separation

1. With the Carbonell method. After the hernia sac is isolated and incised, the rectus muscles on both sides are dissected from the posterior layer and the parietal peritoneum (in cases of long-standing or giant hernias, separation of the inferior rectus sheath and the parietal peritoneum is usually impossible). The lateral edge of the sheath is incised laterally and with an upper direction, and the internal oblique and transversus abdominis muscles are bluntly separated (using the fingers). A 30 x 30 cm mesh is placed (after suturing the peritoneum) lower to the rectus muscle and laterally from it, on both sides, between the transverse and internal oblique muscles; the mesh is fixed with several transmuscular sutures.
2. With Novitsky method - initially, similar to Carbonell's method, but after dissecting the lateral edges of the rectus muscle in an upward direction, the transverse muscle is very carefully dissected (by cutting small parts with a dissector), which leads to the maximum reduction of tension in the anterior abdominal wall and, as a result, a decrease in intra-abdominal pressure. The mesh is fixed with three strips cut out on both edges of

a 30x30 cm mesh, which protrude over the external aponeurosis and are secured to it with knotted sutures.

Hybrid method

We performed the following procedure: mostly mesh transplantation using the Sabley or Ramirez method, plus fasciotomy; the aponeurosis covering both rectus muscle sheaths was vertically dissected, and additional mesh pieces were placed. This prevented extensive layering of the skin and subcutaneous tissue, thereby protecting the patient from extensive damage to blood vessels and nerve trunks.

The necessary conditions for applying all the rules were the following:

1. Intra-abdominal pressure should not exceed the permissible norm (18-24 mm Hg);
2. Restoration of the linea alba;
3. Return of the muscular-fascial apparatus of the anterior wall to the geographical anatomical boundaries and maximum restoration of elasticity;
4. Maximum sparing of perforating blood vessels and nerve fibers.

CONCLUSIONS AND RECOMMENDATIONS:

1. A modern and reliable method for the surgical treatment of large and postoperative, complex hernias ($W > 10$ cm) should be considered for the reconstruction of the anterior abdominal wall with separation of the constituent muscles and aponeurosis.
2. The type of separation reconstruction should be determined based on a detailed study of the patients' vital systems (metabolic disorders: obesity-mass index, diabetes, respiratory, cardiovascular, and respiratory system conditions, age).
3. The patient should be aware that the recurrence rate increases after each operation (estimated at 39%-80% for the 3rd operation), and the surgeon should not always offer the patient surgery for a giant hernia ($W > 10$ cm). There are hernias whose plastic surgery is not correct and should not be performed.
4. The main criteria for the surgical treatment of giant hernias, whether anterior, posterior, or hybrid separation, are: 1. Maintaining intra-abdominal pressure (15-30 mmHg) within the normal range; 2. Restoring the linea alba; 3. Restoring the anatomical geography of the muscles and aponeurotic apparatus that make up the anterior abdominal wall, and restoring maximum elasticity.
5. Before, during, and after separation reconstruction surgery, constant monitoring of intra-abdominal pressure is crucial. In our case, 18-24 mmHg (for reference, 18 mmHg corresponds to 30 water column) was the optimal pressure.
6. Separate reconstruction, especially posterior TAR-plasty, is a technically difficult operation and requires meticulous execution of an approved protocol, which is possible with good knowledge of the anatomy and topography of the anterior abdominal wall and reliable experience of the surgeon.
7. Depending on the patient's general condition, concomitant diseases, and the size of the domain (visceral organ reduction), the surgeon chooses the type of separation plastic surgery (anterior, posterior, or hybrid). However, in the case of recurrence, we agree that it is better to perform reconstructive plastic surgery via posterior separation.
8. Anterior abdominal wall reconstruction performed using the posterior separation technique (GCST, TAR) often provides better results in terms of muscle repositioning, linea alba restoration, and aesthetic effect compared to ACST plastic surgery.
9. Anterior abdominal wall plastic surgery with anterior separation plus fasciotomy (the Ramirez and Sabley procedure plus longitudinal incisions of the external aponeurotic plate of the rectus muscle - "Gidmedi" modification) is a justified surgery in aggravating circumstances (age, concomitant diseases), because we achieve the desired result in a relatively short time and with less trauma.
10. Plastic surgery, in addition to fasciotomy, allows us to protect the aponeurosis from extensive tearing, which in itself protects us from extensive damage to perforated blood vessels and nerve fibers.
11. All three methods of separation have complications. Anterior separation has complications more frequently, posterior separation has fewer, but more difficult outcomes (adhesions of the internal organs of the abdominal cavity with the development of erosions, perforations, and fistulas - 1)
12. The involvement of an anesthesiologist along with the surgical team is very important. Complete and continuous anesthesia is necessary for the first three days.
13. The modern method of surgical treatment of giant hernias - separation, reconstructive plastic of the anterior abdominal wall is truly considered the most reliable and acceptable operation today. All its types (anterior, posterior, and hybrid methods) are acceptable, taking into account the patient's general condition and the qualification of the surgical team. In Europe and USA, these operations are classified as category 5 in terms of complexity and are priced at the level of a hemicolectomy. In our country, it is equated with a linea alba hernia, and its meager funding does not correspond to the cost of a 5-hour, technically difficult operation. This is precisely why surgeons are less interested in these operations. Separate Diagnosis-related group (DRG) codes with adequate costing are necessary for such operations.

References:

1. Deerenberg, E. B., Timmermans, L., Hogerzeil, D. P., et al. (2015). A systematic review of the surgical treatment of large incisional hernia. *Hernia*, 19, 89–101. <https://doi.org/10.1007/s10029-014-1321-x>
2. Rutkow, I. M. (2003). Demographic and socioeconomic aspects of hernia repair in the United States in 2003. *Surgical Clinics of North America*, 83(5), 1045–1051. [https://doi.org/10.1016/S0039-6109\(03\)00132-4](https://doi.org/10.1016/S0039-6109(03)00132-4)
3. Kingsnorth, A. N. (2006). The management of incisional hernia. *Annals of the Royal College of Surgeons of England*, 88(3), 252–260. <https://doi.org/10.1308/003588406X106324>
4. Eriksson, A., Rosenberg, J., & Bisgaard, T. (2014). Surgical treatment for giant incisional hernia: A qualitative systematic review. *Hernia*, 18(1), 31–38. <https://doi.org/10.1007/s10029-013-1066-y>
5. Kim, Z., & Kim, Y. J. (2011). Components separation technique for large abdominal wall defect. *Journal of the Korean Surgical Society*, 80(Suppl. 1), S63–S66. <https://doi.org/10.4174/jkss.2011.80.Suppl1.S63>
6. Yurasov, A. V., Shestakov, A. L., Kurashvili, D. N., & Abovyan, L. A. (2014). Modern concept of surgical treatment of patients with postoperative anterior abdominal wall hernias. *Bulletin of Experimental and Clinical Surg.*, 7(4), 405–413. [In Russian].
7. Charyshkin, A. L., & Frolov, A. A. (2013). Quality of life assessment in patients after hernioplasty for large and giant postoperative ventral hernias. *Modern Problems of Science and Education*, 5. [In Russian].
8. Klokov, V. A. (2012). The significance of tension-free hernioplasty in the prevention of thromboembolic complications in patients with postoperative ventral hernias. *Siberian Medical Journal (Irkutsk)*, 2, 20–22. [In Russian].
9. Perez, J. E., Schmidt, M. A., Narvaez, A., Welsh, L. K., Diaz, R., Castro, M., Ansari, K., Cason, R. W., Bilezikian, J. A., Hope, W., Gueron, A. D., Yoo, J., & Levinson, H. (2021). Evolving concepts in ventral hernia repair and physical therapy: Prehabilitation, rehabilitation, and analogies to tendon reconstruction. *Hernia*, 25, 1–13. <https://doi.org/10.1007/s10029-020-02304-5>
10. Botezatu, A. A., Railianu, R. I., & Evald, A. M. (2011). Results of treatment of anterior abdominal wall hernias using combined hernioplasty techniques. In *Proceedings of the VIII Sc. Conf. "Current Issues in Herniology"* (pp. 39–41). Moscow. [In Russian].
11. Slater, N. J., Montgomery, A., Berrevoet, F., Carbonell, A. M., Chang, A., Franklin, M., Kercher, K. W., Lammers, B. J., Parra-Davila, E., Roll, S., Towfigh, S., van Geffen, E., Conze, J., & van Goor, H. (2014). Criteria for definition of a complex abdominal wall hernia. *Hernia*, 18(1), 7–17. <https://doi.org/10.1007/s10029-013-1168-6>
12. Ivanov, I. S., Lazarenko, V. A., Ivanov, S. V., Goryainova, G. N., & Tarabrin, D. V. (2013). Analysis of the ratio of collagen types I and III in the skin and aponeurosis in patients with ventral hernias. *Bulletin of Experimental and Clinical Surgery*, 3, 331–334. [In Russian].
13. Vorst, A. L., Kaoutzian, C., Carbonell, A. M., & Franz, M. G. (2015). Evolution and advances in laparoscopic ventral and incisional hernia repair. *World Journal of Gastrointestinal Surgery*, 7(11), 293–305. <https://doi.org/10.4240/wjgs.v7.i11.293>
14. Pershikov, B. B., & Loginov, B. I. (2018). Posterior separation: Indications, technique, and results. *Modern Problems of Science and Education, Surgery Series*, 15. [In Russian].
15. Cheatham, M. L. (2009). Abdominal compartment syndrome. *Current Opinion in Critical Care*, 15(2), 154–162. <https://doi.org/10.1097/MCC.0b013e3283297934>
16. McAdory, R. S., Cobb, W. S., & Carbonell, A. M. (2009). Progressive preoperative pneumoperitoneum for hernias with loss of domain. *The American Surgeon*, 75(6), 504–509. <https://doi.org/10.1177/000313480907500609>
17. Roth, J. S., Brathwaite, C., Hacker, K., Fisher, K., & King, J. (2015). Complex ventral hernia repair with a human acellular dermal matrix. *Hernia*, 19(2), 247–252. <https://doi.org/10.1007/s10029-014-1245-5>
18. Burenkov, A. A., Blagolev, N. C., & Ivanov, T. B. (2022). Evolution of separation plasty methods. *Surgical Practice*, 3(45). [In Russian].
19. Malkov, I. S., Filippov, V. A., Shaimardanov, R. Sh., Korobkov, V. N., Gubaev, R. F., & Erhu, E. E. (2017). Experience in performing posterior separation plasty for giant postoperative ventral hernias. *Kazan Medical Journal*, 98(4), 636–640. <https://doi.org/10.17750/KMJ2017-636>
20. Egiev, V. N., Kuliev, S. A., & Evsyukova, I. V. (2017). Results of posterior separation plasty in patients with midline ventral hernias. *Clinical and Experimental Surgery*, 2, 29–32. <https://doi.org/10.24411/2308-1198-2017-00030>
21. Vinnik, Y. S., Nazaryants, Y. A., Petrushko, S. I., Gorbunov, N. S., & Miller, S. V. (2010). Method of combined plasty for giant postoperative abdominal hernias (Russian Federation Patent No. 2405494). [In Russian].
22. Ramirez, O. M., Ruas, E., & Dellon, A. L. (1990). "Components separation" method for closure of abdominal-wall defects: An anatomic and clinical study. *Plastic and Reconstructive Surgery*, 86(3), 519–526. <https://doi.org/10.1097/00006534-199009000-00023>
23. Carbonell, A. M., Cobb, W. S., & Chen, S. M. (2008). Posterior components separation during retromuscular hernia repair. *Hernia*, 12(4), 359–362. <https://doi.org/10.1007/s10029-008-0356-2>
24. Novitsky, Y. W., Elliott, H. L., Orenstein, S. B., & Rosen, M. J. (2012). Transversus abdominis muscle release: A novel approach to posterior component separation during complex abdominal wall reconstruction. *American Journal of Surgery*, 204(5), 709–716. <https://doi.org/10.1016/j.amjsurg.2012.02.008>
25. Novitsky, Y. W., Fayezizadeh, M., Majumder, A., Neupane, R., Elliott, H. L., & Orenstein, S. B. (2016). Outcomes of posterior component separation with transversus abdominis muscle release and synthetic mesh sublay reinforcement. *Annals of Surgery*, 264(2), 226–232. <https://doi.org/10.1097/SLA.0000000000001673>
26. Samartsev, V. A., Gavrilov, V. A., Parshakov, A. A., & Kuznetsova, M. V. (2017). Posterior separation hernioplasty (TAR) for incisional ventral hernias W3. *Perm Medical Journal*, 34(1), 35–42. [In Russian].
27. Alkhatib, H., Tastaldi, L., Krpata, D. M., Petro, C. C., Fafaj, A., Rosenblatt, S., Rosen, M. J., & Prabhu, A. S. (2020). Outcomes of transversus abdominis release (TAR) with permanent synthetic retromuscular reinforcement for bridged repairs in massive ventral hernias: A retrospective review. *Hernia*, 24(2), 341–352. <https://doi.org/10.1007/s10029-019-02046-z>

გიგანტური, რთული ვენტრალური თიაქრების ქირურგიული მკურნალობა

მუცლის წინა კედლის დიდი ზომის, გიგანტური პოსტოპერაციული თიაქრების სეპარაციული პლასტიკა (CST). შპს „გიდმედის“ 5 წლიანი გამოცდილება

გივი ჩიქობავა, ამირან ანთაძე, ნინო ჩიქობავა, მალხაზ ჩუბინიძე

საქართველო-ისრაელის ერთობლივი კლინიკა „გიდმედი“

პასუხისმგებელი პირი: გივი ჩიქობავა, givi_chiqobava@hotmail.com

DOI: <https://doi.org/10.48412/GTBGS.2026.14-15.16-24>

რეზიუმე | **მიზანი:** დიდი ზომის, რეციდიული რთული ვენტრალური თიაქრების (თიაქრის კარის ჰორიზონტალური დიამეტრი 8-10სმ-ზე მეტი) ოპერაციული მკურნალობის ახალი მეთოდის - მუცლის წინა კედლის სეპარაციული რეკონსტრუქციული პლასტიკის (წინა, უკანა, ჰიბრიდული) ეფექტურობისა და დანერგვის შესახებ კლინიკა „გიდმედში“.

მასალა და მეთოდები: მეთოდის არსი შემდგომში მდგომარეობს - გიგანტური, რთული თიაქრების ლიკვიდაცია და პლასტიკა მუცლის წინა კედლის შემადგენელი ანატომიური კომპონენტების გამოყოფით და შემდგომი სეპარაციული რეკონსტრუქციული პლასტიკა, ბადის გამოყენებით. ბოლო 5 წლის განმავლობაში 54 პაციენტს ჩაუტარდა წინა ACST (anterior components separation technique), უკანა PCST (posterior components separation technique) და შერეული წესით. შესწავლილი იქნა რთული თიაქრის ოპერაციული მკურნალობის აუცილებელი პირობები (ყველა შემთხვევაში არ შეიძლება ოპერაციის გაკეთება), თიაქრის განვითარების აუცილებელი ფაქტორები, აუცილებელი ტექნიკა წინა, უკანა და ჰიბრიდული წესით სეპარაციული რეკონსტრუქციისა. დამუშავდა კლინიკის საკუთარი მეთოდი შერეული სეპარაციული რეკონსტრუქციისა, 2019 წლიდან 2025 წლამდე კლინიკა „გიდმედში“ წარმოებულ იქნა 54 ოპერაცია დიდი ზომის, რთული და პოსტოპერაციული თიაქრების ($w > 8-10$ სმ) გამო. აქედან 32 მუცლის წინა სეპარაციული (ACST) პლასტიკის წესით; 10 - უკანა სეპარაციული რეკონსტრუქციით (GCST), 6 - კარბონელის და 4 - ნოვიცკის წესით; 12 - ჰიბრიდული წესით (საბლეს მეთოდი + ფასციოტომია), 3 შემთხვევაში განვითარდა რეციდივი.

დასკვნა: დიდი და რთული თიაქრების ($w > 8-10$ სმ) ქირურგიული მკურნალობის თანამედროვე, სწორ და სანდო მეთოდად სამივე წესი - მუცლის წინა კედლის წინა, უკანა და ჰიბრიდული სეპარაციული რეკონსტრუქცია მისაღებია, მაგრამ თვითნებური წესი უნდა განისაზღვროს პაციენტის ზოგადი მდგომარეობის, თანმხლები დაავადებების, ასაკის, დაავადების ხანგრძლიობის, ქირურგიის კვალიფიკაციის და ოპერაციისათვის საჭირო ოპტიმალური დროის მიხედვით. რეციდივის შემთხვევაში არა აქვს მნიშვნელობა რომელი წესითაა წინა ოპერაცია შესრულებული, განმეორებითი ოპერაციისას უპირატესობა უნდა მიენიჭოს მუცლის წინა კედლის უკანა სეპარაციულ პლასტიკას, GCST და TAR პლასტიკას.

საკვანძო სიტყვები: ვენტრალური თიაქარი, რეციდიული რთული ვენტრალური თიაქარი, მუცლის წინა კედლის სეპარაციული რეკონსტრუქციული პლასტიკა

RARE COMPLICATION - DEVELOPMENT OF AN ABDOMINAL WALL PSEUDOCYST AFTER INCISIONAL HERNIA REPAIR WITH MESH: A CASE REPORT

Emzar Diasamidze¹, Elguja Ardia², Giorgi Antadze³, Tamaz Gvenetadze¹

¹David Aghmashenebeli University of Georgia, ²Petre Shotadze Tbilisi Medical Academy,

³Batumi Shota Rustaveli State University

Contact person: Emzar Diasamidze, dr.diasamidze@mail.ru

DOI: <https://doi.org/10.48412/GTBGS.2026.14-15.25-28>

Rezume

Introduction: Seromas commonly form after incisional hernia repair, particularly when surgeons use prosthetic materials. While most cases resolve spontaneously, some can be prolonged or recurrent, necessitating repeated intervention.

Case presentation: We present a case of seroma that developed following incisional hernia repair with mesh. Despite conservative treatment involving repeated aspiration and subsequent surgical drainage, the fluid reaccumulated and formed an encapsulated mass, necessitating re-operation several months later. The organised seroma was excised without removing the mesh, and the patient was discharged without complications.

Conclusion: Prolonged and irreversible seroma formation after incisional hernia repair can lead to the development of a chronic encapsulated pseudocyst. Early recognition, careful monitoring, and timely surgical intervention can prevent long-term morbidity without the need to remove the mesh in non-infected cases.

Key words: Incisional hernia; Seroma; Pseudocyst; Mesh repair; Postoperative complications; Surgical management

INTRODUCTION

An incisional hernia is a common complication following abdominal surgery, with an incidence ranging from 10% to 20% depending on the surgical technique used, how well the wound heals, and patient-related factors such as obesity, infection, and other health conditions [1]. Mesh repair, particularly in the sublay (retro-rectus) position, has become the gold standard for hernia repair due to its favourable biomechanical properties and lower recurrence rate than onlay or inlay techniques [2, 3].

However, despite the advantages of mesh repair, postoperative complications can occur. One of the most common of these is seroma formation, which is the accumulation of non-infected fluid in the 'dead space' created by surgical dissection. It has an incidence ranging from 5% to 25% [4]. Seroma formation can delay healing, cause discomfort, and increase the risk of infection. In rare cases, it can lead to the development of chronic encapsulated seromas (pseudocysts), which are often refractory to conservative management.

The pathophysiology of seroma formation involves mechanical and biological factors. Surgical dissection and tissue devascularisation create potential sites for fluid accumulation, and a foreign body reaction to the mesh, as well as local inflammatory responses, can increase fluid exudation. While most seromas resolve spontaneously or following simple aspiration, persistent or organised seromas often necessitate surgical intervention [6].

We present the case of a patient who developed a recurrent postoperative seroma following sublay mesh repair of an incisional hernia. The patient underwent multiple interventions, including aspiration, surgical drainage,

and, finally, organised excision of the fluid capsule without mesh removal. This report highlights the challenges associated with managing chronic seromas and reviews the existing literature on their prevention and treatment.

CASE PRESENTATION

A 75-year-old female patient was admitted to our surgical department with a symptomatic incisional hernia at the site of a previous midline laparotomy incision. The hernial defect measured approximately 12 x 5 cm. Preoperative examinations revealed no pathology that would affect the outcome, and there were no signs of infection or intestinal obstruction.

The patient underwent elective incisional hernia surgery under general anaesthesia. Following adhesiolysis and excision of the hernia sac, the posterior rectus sheath was closed, a polypropylene mesh was placed in the sublay position, and the anterior fascia was closed. A drainage tube was left in the wound and removed after 3 days, when the amount of fluid released decreased to 20 ml/day. The early postoperative period was uneventful, and the patient was discharged on the fourth postoperative day.

Approximately one week after discharge, the patient developed progressive swelling and mild discomfort at the surgical site. An ultrasound examination revealed fluid accumulation consistent with a postoperative seroma. Conservative treatment was initiated, including local puncture and aspiration under sterile conditions. However, despite several aspiration attempts, the seroma reaccumulated. As conservative measures proved ineffective, the patient was readmitted and underwent surgical drainage under gen-

eral anaesthesia. Around 3,000 ml of clear serous fluid was evacuated, and a drain was inserted. Bacteriological examination of the fluid revealed no microflora, and cytological examination revealed no atypical cells. The patient was discharged in a stable condition.

During follow-up a few weeks later, recurrent oedema developed at the same site. Imaging confirmed persistent fluid accumulation without signs of infection (figure 1).

Over time, the seroma became encapsulated and organised, forming a pseudocyst-like cavity (figure 2). Following several months of observation and the failure of conservative measures, a third surgical procedure was performed.

At the time of surgery, a fibrous capsule containing serous fluid was present ventrally to the mesh. The capsule was carefully excised without removing the mesh, as a fibrous layer was observed between the prosthetic material and the posterior wall of the cyst (figure 3, 4, 5). There was no evidence of infection or pathological inclusions. The patient was discharged home after surgery without complications, and no recurrence of seroma or hernia was noted after three months of follow-up.

DISCUSSION

Seroma formation is one of the most common complications following mesh hernia repair. This is primarily due

to tissue trauma, lymphatic damage, and the creation of 'dead space' during dissection [7]. Although the sublay technique is associated with a lower rate of wound complications than the onlay technique, seromas can still occur due to the need for extensive retrorectal dissection.

PATHOPHYSIOLOGY

A seroma is an accumulation of sterile serous fluid resulting from inflammatory exudation and lymphatic leakage. If this accumulation is not resolved over time, it can stimulate the formation of fibrous tissue around it, leading to encapsulation and the formation of a chronic seroma or pseudocyst [9]. The capsule is composed of fibrous connective tissue lined with inflammatory cells and can persist despite repeated aspiration.

MANAGEMENT

The management of postoperative seroma depends on its size, symptoms, and persistence.

1. Small, asymptomatic seromas may be observed as many resolve spontaneously within weeks.
2. Symptomatic or large seromas are treated with needle aspiration or percutaneous drainage.
3. If these measures fail, sclerotherapy using agents such as doxycycline or ethanol may be employed, although studies have shown mixed results [10].

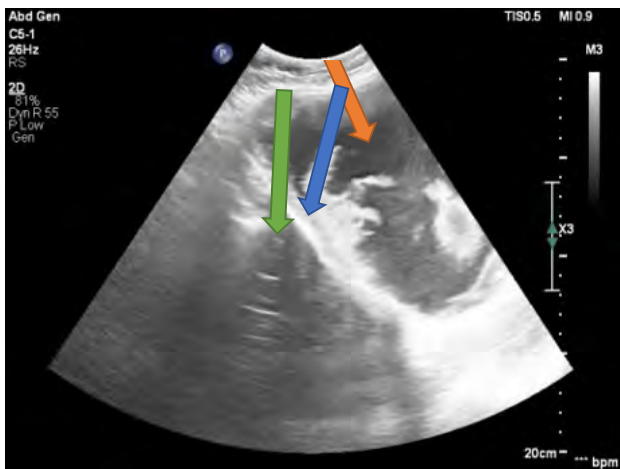


Figure 3. Cyst, blue arrow indicates the mesh, orange arrow indicates the cyst cavity, green arrow indicates the abdominal cavity

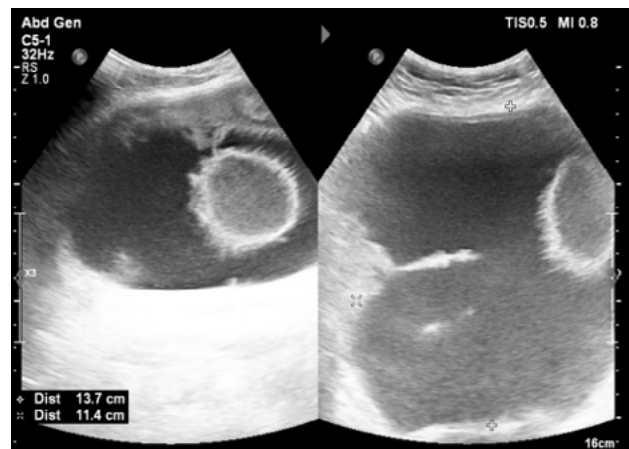


Figure 2. Ultrasound data of the cyst

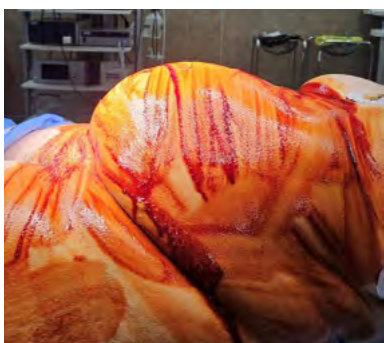

Figure 3. Mass on the anterior abdominal wall

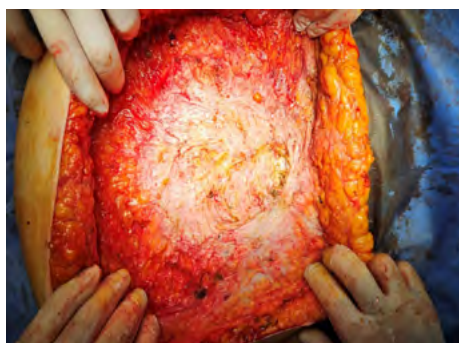


Figure 4. Anterior abdominal wall after cyst excision

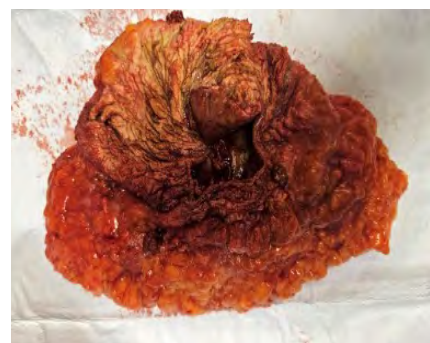

Figure 5. Macroscopic image of excised cyst

4. Persistent or organised seromas require surgical excision of the capsule.

In our patient, despite repeated aspiration and one surgical drainage procedure, the seroma reaccumulated and organised over several months. A successful outcome was ultimately achieved through the complete excision of the fibrous capsule while preserving the mesh, as it was not infected. Mesh removal is indicated only if infection or mesh migration is suspected [11].

PREVENTION

Preventive strategies include achieving haemostasis, minimizing tissue trauma, and ensuring adequate drainage. Using closed suction drains in large dissection sites

may reduce the incidence of seromas, although their routine use remains controversial [12]. Some studies have suggested the use of fibrin glue.

CONCLUSION

The recurrence of seroma or the formation of a chronic cyst after incisional hernia repair is a rare but challenging complication. While most seromas respond to conservative treatment, those that are persistent or encapsulated often require surgical intervention. If there is no infection, the mesh can be retained. During the intraoperative period, surgeons should focus on preventive measures and provide close postoperative surveillance to ensure early detection and appropriate management.

References:

1. Luijendijk, R. W., Hop, W. C., van den Tol, M. P., de Lange, D. C., Braaksma, M. M., Ujzermans, J. N., Boelhouwer, R. U., de Vries, B. C., Salu, M. K., Wereldsma, J. C., & Bruijninx, C. M. (2000). A comparison of suture repair with mesh repair for incisional hernia. *New England Journal of Medicine*, 343(6), 392–398. <https://doi.org/10.1056/NEJM200008103430603>
2. Maskal, S. M., Miller, B. T., Ellis, R. C., Beffa, L. R., Prabhu, A. S., Rosen, M. J., Krpata, D. M., Huang, L. C., & Petro, C. C. (2025). A modern comparison of suture repair versus mesh repair for incisional hernia: A study protocol for a randomized controlled trial. *Trials*, 26(1), 450.
3. Sahoo, R., Gupta, K. P., Naik, N. K., Voona, A., & Ganesh, A. S. (2025). A comparison study between retro-rectus and onlay mesh repair outcomes for ventral hernia in a tertiary care center. *International Journal of Abdominal Wall and Hernia Surgery*, 8(2), 82–89.
4. Albino, F. P., et al. (2013). Seroma prevention strategies after abdominoplasty: A systematic review and meta-analysis. *Aesthetic Surgery Journal*, 33(10), 1316–1325. <https://doi.org/10.1177/1090820X13514503>
5. Kafeel, U., Imtiaz, K., Butt, M. S., Saad, M., Yaseen, R., & Sufyan, M. (2025). Comparative study of abdominal wall closure method–Hughes technique versus conventional mass closure in reducing incisional hernia. *Indus Journal of Bioscience Research*, 3(1), 739–744.
6. Hawn, M. T., et al. (2011). Postoperative complications after incisional hernia repair: An analysis of 10,000 cases from the NSQIP database. *Journal of the American College of Surgeons*, 212(1), 70–79. <https://doi.org/10.1016/j.jamcollsurg.2010.09.012>
7. Hillejan, K. (2023). *Seroma after ventral hernia repair: Risk factors, diagnostic, prevention and management (Master's thesis, Lithuanian University of Health Sciences)*.
8. Kckerling, F., Alam, N. N., Narang, S. K., Daniels, I. R., & Smart, N. J. (2015). Biological meshes for inguinal hernia repair: Review of the literature. *Frontiers in Surgery*, 2, 48. <https://doi.org/10.3389/fsurg.2015.00048>
9. Loo, W. T., et al. (2016). Chronic encapsulated seroma (pseudocyst) following mesh repair of incisional hernia: A rare complication. *Hernia*, 20(2), 319–323. <https://doi.org/10.1007/s10029-015-1441-8>
10. Cunningham, H. B., Weis, J. J., Taveras, L. R., & Huerta, S. (2019). Mesh migration following abdominal hernia repair: A comprehensive review. *Hernia*, 23(2), 235–243. <https://doi.org/10.1007/s10029-018-1834-9>
11. Di Vita, G., et al. (2013). Management of chronic seroma after prosthetic repair of incisional hernia. *Annali Italiani di Chirurgia*, 84(4), 447–450.
12. Brown, R. H., et al. (2017). The role of drains in open ventral hernia repair with mesh: A prospective randomized controlled trial. *Hernia*, 21(4), 641–649. <https://doi.org/10.1007/s10029-017-1593-0>
13. Kral, J. G. (2018). Quilting sutures in abdominoplasty reduce seroma formation. *Plastic and Reconstructive Surgery*, 142(3), 774–782. <https://doi.org/10.1097/PRS.0000000000004631>

ინციზიური თიაქრის ბადით ჯანმრთელობის მართვასთან დაკავშირებული რისკების მართვა: შემთხვევის მიმოხილვა

ემზარ დიასამიძე¹, ელგუჯა არდია², გიორგი ანთაძე³, თამაზ გვენეტაძე¹

¹საქართველოს დავით აღმაშენებლის სახელობის უნივერსიტეტი; ²პეტრე შოთაძის სახელობის თბილისის სამედიცინო აკადემია; ³ბათუმის შოთა რუსთაველის სახელმწიფო უნივერსიტეტი

პასუხისმგებელი პირი: ემზარ დიასამიძე, dr.diasamidze@mail.ru

DOI: <https://doi.org/10.48412/GTBGS.2026.14-15.25-28>

რეზიუმე შესავალი: ინციზიური თიაქრების აღდგენის შემდეგ ხშირად ვითარდება სერომები, განსაკუთრებით მაშინ, თუ გამოყენებულია საპროთეზო მასალები. შემთხვევათა უმრავლესობაში სერომა სპონტანურად ქრება, თუმცა ზოგჯერ შეიძლება პროცესი გახანგრძლივდეს ან განვითარდეს რეციდივი, რაც განმეორებით ჩარევას მოითხოვს.

შემთხვევის პრეზენტაცია: წარმოგიდგინოთ სერომის შემთხვევა, რომელიც განვითარდა ინციზიური თიაქრის ბადით აღდგენის შემდეგ. განმეორებითი ასპირაციის, შემდგომი ქირურგიული დრენირებითა და კონსერვატიული თერაპიის მიუხედავად, სითხე ხელახლა დაგროვდა და ჩამოყალიბდა ინკაფსულირებული მასა, რაც რამდენიმე თვის შემდეგ ახალი ოპერაციის ჩვენება გახდა. ორგანიზებული სერომა ამოიკვეთა ბადის მოცილების გარეშე. პაციენტი გაეწერა დამაკმაყოფილებელ მდგომარეობაში.

დასკვნა: ინციზიური თიაქრის აღდგენის შემდეგ სერომის ხანგრძლივმა და შეუქცევადმა ფორმირებამ შეიძლება გამოიწვიოს ქრონიკული ინკაფსულირებული ფსევდოკისტის განვითარება. ადრეული ამოცნობა, ფრთხილი მონიტორინგი და დროული ქირურგიული ჩარევა ავადობის გახანგრძლივებას ბადის მოხსნის საჭიროების გარეშე, არაინციზიურულ შემთხვევებში.

საკვანძო სიტყვები: ინციზიური თიაქარი; სერომა; ფსევდოკისტა; ბადის რეპარაცია; პოსტოპერაციული გართულებები; ქირურგიული მართვა

POSTOPERATIVE HEMORRHAGE CAUSED BY UNDIAGNOSED VON WILLEBRAND DISEASE: A CLINICAL CASE REPORT

Davit Vardosanidze, Besarion Iremashvili, Zaza Demetrashvili, Lali Akhmeteli, Liana Saginashvili

Tbilisi State Medical University, Department of Surgery №1

Contact person: Besarion Iremashvili, iremashvilbvi@gmail.com

DOI: <https://doi.org/10.48412/GTBGS.2026.14-15.29-33>

Rezume

Postoperative hemorrhage remains one of the most dangerous complications in the immediate postoperative period. Among its causes, von Willebrand disease (VWD) occupies a significant place. Management becomes particularly challenging when surgeons encounter previously undiagnosed coagulopathy during urgent surgery. Von Willebrand disease is an inherited bleeding disorder characterized by quantitative or qualitative defects of von Willebrand factor (VWF). VWF mediates primary platelet adhesion to damaged endothelium, supports platelet aggregation, initiates thrombus formation, and stabilizes coagulation factor VIII in plasma. Timely recognition of VWD in surgical practice remains difficult because routine preoperative coagulation tests—including PT, PT%, INR, APTT, TT, and fibrinogen—often remain within normal limits and fail to raise diagnostic suspicion. We report the case of a 77-year-old male who underwent emergency open mesh hernioplasty for an incarcerated indirect inguinal hernia. During the postoperative period, the patient developed a progressively enlarging subcutaneous hematoma that required surgical re-exploration. Intraoperatively, the surgical team identified no active bleeding source or technical cause. Subsequent hematologic evaluation confirmed Type 1 von Willebrand disease. Targeted conservative hemostatic therapy controlled the bleeding and led to clinical improvement.

Key words: Postoperative hemorrhage, von Willebrand Disease, inguinal hernia

INTRODUCTION

Postoperative hemorrhage occupies a leading position among life-threatening complications encountered in surgical practice [5, 6, 11]. Owing to its aggressive nature, postoperative bleeding can rapidly and dramatically deteriorate a patient's condition, frequently resulting in hypovolemic shock and acute anemia. Such complications often necessitate repeated surgical intervention and transfusion of blood components, impair reparative processes, weaken anti-infective defense mechanisms, worsen overall treatment outcomes, increase rates of disability and mortality, prolong hospitalization, and significantly raise the cost of care.

Despite advances in modern surgical technology, the introduction of high-precision minimally invasive techniques, and the improved effectiveness of contemporary therapeutic measures, postoperative bleeding remains a relevant and challenging clinical problem.

The reported incidence of postoperative hemorrhage varies widely in the international literature, reflecting the influence of numerous contributing factors. These include: the nature of the primary disease, the profile and complexity of the surgical procedure, technical intraoperative difficulties, the trophic condition of tissues in the surgical field, the extent of inflammatory or neoplastic involvement, patient age, severity of comorbidities, the necessity of perioperative anticoagulant or antiplatelet therapy, and

the urgency of the operation—which may limit the time available for comprehensive preoperative assessment and optimization.

In addition to the above factors, one should give particular attention to disorders of hemostasis, which significantly increase the risk of postoperative bleeding [5, 6, 11]. Among these, von Willebrand disease (VWD) represents a distinct clinical entity characterized by impaired coagulation and platelet adhesion. It therefore deserves special consideration as a potential underlying cause of unexpected hemorrhagic complications in the postoperative period.

Although VWD is considered relatively common, its true prevalence remains insufficiently defined [7]. According to various literature sources, reported prevalence ranges from 0.6% to 2% in the general population [2, 7, 8]. The distribution of individual VWD subtypes, however, demonstrates even greater variability across statistical reports [1, 2, 8, 9].

The pathophysiology of VWD is complex. Three major types of the disease are recognized [1, 7, 9]:

- **Type I** — accounting for 70–80% of cases, is inherited in an autosomal dominant pattern and is characterized by a quantitative deficiency of von Willebrand factor (VWF). In this form, the protein's structure and functional integrity are preserved [1, 5].
- **Type II** — observed in 7–25% of patients, is also typically inherited in an autosomal dominant manner. In this subtype, plasma VWF levels are usually normal or

near normal, but the protein is functionally abnormal. The literature describes more than 20 variants of Type II, the clinically most relevant include Type 2A-AD, 2B-AD, 2M-AD, and 2N-AR. [1, 5, 9].

- **Type III** — the most severe and least common form, accounting for 5–20% of cases, is inherited in an autosomal recessive pattern and is characterized by a near-complete or complete absence of VWF. This subtype poses the highest bleeding risk, as even minimal trauma or surgical intervention can lead to life-threatening hemorrhage [4].

VWD is primarily a hereditary coagulation disorder, but in rare cases it may develop as an acquired condition secondary to other diseases—most commonly lymphoproliferative, myeloproliferative, or autoimmune disorders. This form, known as acquired von Willebrand syndrome, results from either reduced synthesis of VWF or accelerated clearance of VWF from the circulation [2, 3, 9, 10].

The underlying cause of hereditary VWD is a mutation in the gene that regulates VWF synthesis [2]. Von Willebrand factor is a multimeric glycoprotein essential for primary hemostasis, mediating platelet adhesion to damaged vascular endothelium, promoting subsequent platelet aggregation, and initiating thrombus formation.

Additionally, VWF plays a crucial role in transporting and stabilizing coagulation factor VIII, thereby supporting normal plasma levels of factor VIII [2, 3, 7, 9].

The pathognomonic clinical manifestation of VWD is spontaneous or prolonged bleeding, occurring either without provocation or following physiological and pathological triggers such as trauma, surgery, or dental procedures. Patients frequently exhibit easy bruising (ecchymoses) and have a marked predisposition to recurrent epistaxis, menorrhagia, hematuria, and melena or hematochezia [5, 6].

Notably, a subset of patients may have no prior history of clinically significant bleeding episodes, and therefore may remain undiagnosed with VWD until a hemostatic challenge occurs [2].

Routine coagulation studies—such as prothrombin time (PT), prothrombin activity (PT%), international normalized ratio (INR), activated partial thromboplastin time (APTT), thrombin time (TT), and plasma fibrinogen concentration—are frequently within normal limits, or altered only minimally. As a result, standard coagulation profiles often fail to raise diagnostic suspicion and are generally insufficient for early recognition of VWD.

Accurate laboratory diagnosis relies on specific assays, including:

1. von Willebrand factor antigen (vWF:Ag);
2. Ristocetin cofactor activity of von Willebrand factor (vWF: RCo);
3. Factor VIII procoagulant activity (FVIII: C).

When indicated, additional studies may include:

- von Willebrand factor collagen-binding activity (vWF: CB)
- VWF multimer analysis
- Platelet aggregation studies using major inducers (ristocetin, thrombin, adrenaline, ADP, and collagen).

Because genetic defects cause VWD, it is not a curable disorder. Management is symptom-directed and indicated primarily in situations of active bleeding or when invasive procedures are planned, including surgical or dental interventions [6, 8]. The therapeutic objective is to increase plasma VWF levels using vasopressin analogues (e.g., desmopressin) in cases of quantitative deficiency, or to provide factor replacement therapy when functional defects are present [5, 6, 8]. To prevent premature fibrinolysis and enhance clot stability, antifibrinolytic agents are also employed [5, 6, 8].

CLINICAL CASE PRESENTATION

A 77-year-old male was brought to the Emergency Department of a University Clinic by the national emergency medical response team (service 112) as an urgent case. Upon admission, the patient was conscious, cooperative, fully oriented, and hemodynamically stable, and was complaining of persistent, severe pain in a large mass located in the left inguinal region. The patient also reported intermittent, colicky, moderate abdominal pain, dry mouth, abdominal distension, nausea, multiple episodes of vomiting containing gastric chyme, and generalized weakness.

According to the patient's history, a large left inguinal hernia had developed over the past nine years. The hernia reportedly enlarged with increases in intra-abdominal pressure, frequently descending into the scrotum, and, while supine, could be manually reduced completely back into the abdominal cavity. Approximately four hours prior to hospital admission, following a severe coughing episode caused by accidental aspiration of water, the hernia became irreducibly incarcerated, after which the aforementioned symptoms progressively developed, prompting emergency hospitalization.

Physical Examination:

The patient had a normosthenic body habitus. The tongue was dry, the abdomen was distended, participating minimally in respiration. Auscultation revealed intermittent hyperactive bowel sounds, while percussion demonstrated pronounced tympany, with preserved hepatic dullness. On superficial and deep palpation, the abdomen was soft but diffusely tender, without signs of peritoneal irritation. In the left inguinal region, there was a fixed, firm, markedly tender mass with a smooth surface, measuring 13.0x9.5x7.5 cm, with its distal third extending into the scrotum. could no longer reduce the hernia manually into the abdominal cavity, and the cough impulse was negative. A nasogastric tube drained enteric fluid consistent with small bowel contents. Plain abdominal X-ray demonstrated multiple air-fluid levels consistent with mechanical small bowel obstruction. Ultrasonography of the inguinal region revealed small bowel loops within the hernia sac, along with a small amount of free fluid.

Laboratory Findings:

Complete Blood Count (CBC): WBC: $30.34 \times 10^9/L$, NEUT: 92.8%, RBC: $7.90 \times 10^{12}/L$, HGB: 14.1 g/dL,

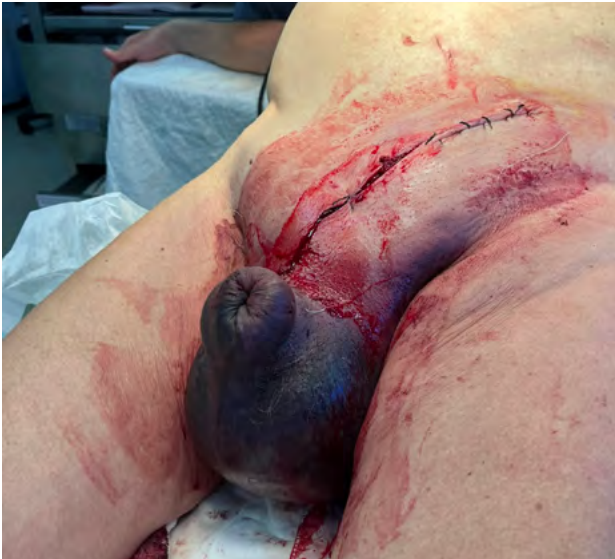

Figure 1. Postoperative hematoma prior to the second surgical intervention.

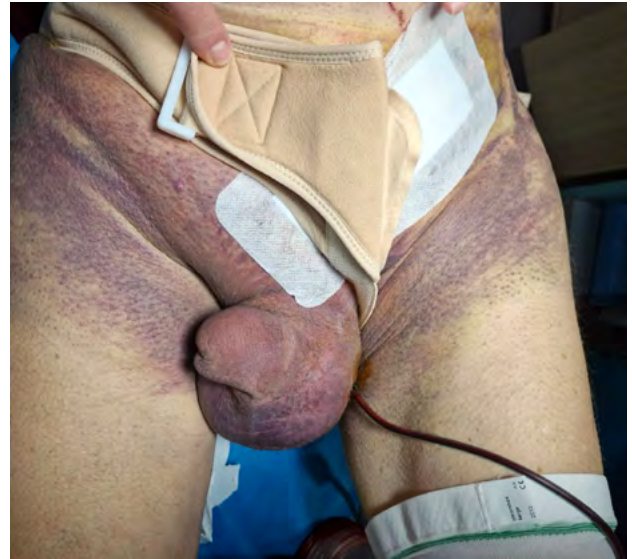

Figure 2. Ten days after the second surgical intervention.

HCT: 48.0%, MCV: 60.80 fL, MCH: 17.90 pg, PLT: $694.00 \times 10^9/L$, PCT: $0.67 \times 10^{-2} L/L$;

Arterial Blood Gas (ABG): pH: 7.40, pCO_2 : 35.40 mmHg, pO_2 : 99.10 mmHg, HCO_3 (act): 21.50 mmol/L, HCO_3 (standard): 22.30 mmol/L, BE (B): -2.60 mmol/L, BE (act): -3.30 mmol/L, $ctCO_2$: 22.60 mmol/L, SaO_2 : 97.60%, FOHb: 94.70%, FCOHb: 1.90%, FMetHb: 1.10%, Lac: 1.57 mmol/L, Na^+ : 136.00 mmol/L, K^+ : 3.93 mmol/L, Cl^- : 103.00 mmol/L, Ca^{2+} : 1.08 mmol/L, Glucose: 110 mg/dL;

Coagulation profile: PT = 14.20 sec, PT% = 70.60%, INR = 1.24.

Based on the clinical evaluation, the surgical team diagnosed: unilateral or unspecified inguinal hernia with obstruction, without gangrene (ICD-10 - K40.3). After appropriate preoperative preparation, the team performed an emergency operation under balanced anesthesia (WAA408): reconstructive surgery for inguinal hernia (NCSP - JASB10).

Upon opening the hernia sac, the surgeons identified approximately 150 mL of yellowish, odorless serous fluid and loops of small intestine. They aspirated the fluid. After confirming bowel viability, they freely reduced the intestinal loops into the abdominal cavity. The surgeons then performed hernia repair using the Lichtenstein technique. The operation proceeded without technical difficulties or intraoperative complications, and the surgeons achieved complete hemostasis.

During the postoperative period, the patient developed a progressively enlarging subcutaneous hematoma at the operative site. Despite the immediate application of local hypothermia, the hematoma gradually expanded over several hours, first involving the scrotum and left inguinal region and eventually the entire hypogastrium (Figure 1, Figure 2).

These postoperative changes strongly suggested ongoing vascular bleeding and prompted wide re-exploration of the herniotomy and hernioplasty area. Intraoperatively, the surgeons identified no discrete source of active

bleeding other than diffuse, low-intensity oozing from the postoperative tissues. This finding raised suspicion of a possible coagulopathy.

Subsequent additional investigations, performed in collaboration with a hematologist, confirmed the presence of Type 1 von Willebrand Disease (VWD). Administration of antifibrinolytic therapy and agents stimulating von Willebrand Factor (VWF) synthesis successfully achieved hemostasis.

DISCUSSION

Identifying VWD can be particularly challenging in urgent or emergency surgery if clinicians have not previously diagnosed it. In such cases, the limited time available before surgical intervention often makes comprehensive preoperative evaluation difficult, particularly in emergency operations. From a diagnostic and preoperative preparation standpoint, the specificity of VWD lies in the fact that standard coagulation tests (e.g., routine coagulation panel) frequently fail to detect this disorder. This pattern in the presented case: the preoperative coagulation profile did not reveal abnormalities (PT = 14.20 sec, PT% = 70.60%, INR = 1.24), and the marked thrombocytosis (PLT = $694 \times 10^9/L$, PCT = $0.67 \times 10^{-2} L/L$) instead suggested an increased risk of thrombosis, rather than bleeding.

Therefore, in suspecting VWD, a thorough and precise medical history (anamnesis) becomes critically important. However, this step also has inherent limitations. Prior to surgery, a patient may fail to recall or may underestimate previous episodes of abnormal bleeding, providing incomplete or misleading information. Additionally, a subset of VWD patients may never have experienced clinically significant bleeding or may never have received an official diagnosis, despite having the disease.

In the presented case, as later confirmed through external sources, the patient had experienced prior bleeding episodes but had intentionally concealed this history. He had never sought medical attention and had not under-

gone evaluation, which delayed recognition of the underlying coagulopathy.

In cases of postoperative bleeding at the surgical site, clinicians typically first suspect a procedural technical error. Consequently, this often compels the surgeon to perform a repeat and essentially "unnecessary" reoperation, even though von Willebrand Disease-caused bleeding requires an entirely different, conservative treatment approach. Suspicion of a coagulopathy usually arises only after intraoperative re-exploration fails to reveal a technical cause of bleeding. Must also emphasize that additional surgical trauma inflicted during reoperation may further aggravate the bleeding.

CONCLUSION

- In general surgery, VWD represents a significant risk factor for life-threatening postoperative hemorrhage.

- Normal routine coagulation test results do not exclude the presence of VWD or the possibility of massive post-operative bleeding.
- Since standard coagulation tests cannot reliably detect VWD promptly, obtaining a thorough, detailed bleeding history is paramount.

PRACTICAL RECOMMENDATIONS FOR SURGEONS

- If intraoperative re-exploration fails to reveal an active source of bleeding — Consider von Willebrand Disease!
- Questions aimed at identifying prior bleeding episodes, including their character and circumstances, must be incorporated into every surgical patient's mandatory preoperative assessment questionnaire.
- When VWD is suspected, and before the disease type and specific targeted therapy are clarified, it is advisable to administer cryoprecipitate and antifibrinolytic agents promptly.

References:

1. James, P. D., Connell, N. T., Ameer, B., Di Paola, J., Eikenboom, J., Giraud, N., et al. (2021). ASH ISTH NHF WFH 2021 guidelines on the diagnosis of von Willebrand disease. *Blood Advances*, 5(1), 280–300. <https://doi.org/10.1182/bloodadvances.2020003265>
2. Kaur, V., Elghawy, O., Deshpande, S., & Riley, D. (2024). Von Willebrand disease: A guide for the internist. *Cleveland Clinic Journal of Medicine*, 91(2), 119–127. <https://doi.org/10.3949/ccjm.91a.22033>
3. Kuter, D. J. (2024). Von Willebrand disease. *Harvard Medical School*. (Reviewed by J. L. Spivak, Johns Hopkins University School of Medicine.)
4. Pielaci ski, K., Pu a, B., & Szczepanik, A. B. (2021). Totally extraperitoneal inguinal hernia repair in patients with hemophilia and von Willebrand disease: Prospective controlled study. *Videosurgery and Other Miniinvasive Techniques*, 16(3), 552–559. <https://doi.org/10.5114/witm.2021.103953>
5. Miesbach, W. (2020). Perioperative management for patients with von Willebrand disease: Defining the optimal approach. *European Journal of Haematology*, 105(4), 365–377. <https://doi.org/10.1111/ejh.13462>
6. Brignardello-Petersen, R., El Alayli, A., Husainat, N., Kalot, M., Shahid, S., Aljabirii, Y., Britt, A., Alturkmani, H., El-Khechen, H., Motaghi, S., Roller, J., Dimassi, A., Abughanimeh, O., Madoukh, B., Arapshian, A., Grow, J. M., Kouides, P., Laffan, M., Leebeek, F. W. G., O'Brien, S. H., Tosetto, A., James, P. D., Connell, N. T., Flood, V., & Mustafa, R. A. (2022). Surgical management of patients with von Willebrand disease: Summary of 2 systematic reviews of the literature. *Blood Advances*. <https://doi.org/10.1182/bloodadvances.2021005666>
7. Du, P., Bergamasco, A., Moride, Y., Truong Berthoz, F., Özen, G., & Tzivelekis, S. (2023). Von Willebrand disease epidemiology, burden of illness and management: A systematic review. *Journal of Blood Medicine*, 14, 189–208. <https://doi.org/10.2147/JBM.S389241>
8. Connell, N. T., Flood, V. H., Brignardello-Petersen, R., Abdul-Kadir, R., Arapshian, A., Couper, S., Grow, J. M., Kouides, P., Laffan, M., Lavin, M., Leebeek, F. W. G., O'Brien, S. H., Ozelo, M. C., Tosetto, A., Weyand, A. C., James, P. D., Kalot, M. A., Husainat, N., & Mustafa, R. A. (2021). ASH ISTH NHF WFH 2021 guidelines on the management of von Willebrand disease. *Blood Advances*, 5(1), 301–325. <https://doi.org/10.1182/bloodadvances.2020003264>
9. Sabih, A., & Babiker, H. M. (2023). Von Willebrand disease. *StatPearls*. <https://www.ncbi.nlm.nih.gov/books/NBK459222/>
10. Petricevic, M., Knezevic, J., Samoukovic, G., Bradaric, B., Safradin, I., Mestrovic, M., Papestiev, V., Hodalin, A., Madzar, T., Mihalj, M., Rotim, A., & Biocina, B. (2020). Diagnosis and management of acquired von Willebrand disease in heart disease: A review of the literature. *Thoracic and Cardiovascular Surgeon*, 68(3), 200–211.
11. Popivanov, G., Vasilev, V., Cirocchi, R., Kjossev, K., Tabakov, M., Penkov, M., & Mutafchiyski, V. (2019). A rare case of life-threatening extra-peritoneal bleeding after open inguinal hernia repair requiring damage control surgery. *Giornale di Chirurgia*, 40(3), 188–192.

ფონ ვილბრანდის არადიაგნოსტიკური დაავადებით გამოწვეული კოსტოპერაციული სისხლდენა. კლინიკური შემთხვევის აღწერა

დავით ვარდოსანიძე, ბესარიონ ირემაშვილი, ზაზა დემეტრაშვილი, ლალი ახმეტელი, ლიანა საგინაშვილი

თბილისის სახელმწიფო სამედიცინო უნივერსიტეტის ქირურგიის N1 დეპარტამენტი

პასუხისმგებელი პირი: ბესარიონ ირემაშვილი, iremashvilivi@gmail.com

DOI: <https://doi.org/10.48412/GTBGS.2026.14-15.29-33>

რეზიუმე

პოსტოპერაციულ პერიოდში განვითარებულ სიცოცხლისთვის საშიშ გართულებათა შორის განსაკუთრებული ადგილი უკავია ფონ ვილბრანდის დაავადებით (VWD) გამოწვეულ სისხლდენებს. მათი მართვა განსაკუთრებით რთულდება იმ პაციენტებში, რომელთაც ოპერაციამდე საერთოდ არ იცოდნენ თუ იყვნენ დაავადებული ამ კოაგულოპათიით. ფონ ვილბრანდის დაავადება მემკვიდრეობითი კოაგულოპათიაა, რომელიც ხასიათდება ფონ ვილბრანდის ფაქტორის (VWF) რაოდენობის, სტრუქტურის ან ფუნქციის დეფექტებით. VWF წარმოადგენს გლიკოპროტეინს, რომელიც უზრუნველყოფს სისხლძარღვის დაზიანებული ენდოთელის ზედაპირზე თრომბოციტების პირველად ადჰეზიას, მათ შემდგომ აგრეგაციას და თრომბის წარმოქმნის პროცესს. ის ასევე უზრუნველყოფს სისხლის შედედების VIII ფაქტორის ტრანსპორტირებას და მისი დონის სტაბილიზაციას პლაზმაში. დაავადების დროულ გამოვლენას ართულებს ის გარემოება, რომ ოპერაციის წინ ჩატარებული კოაგულოგრამის ისეთი სტანდარტული ტესტების მონაცემები როგორცაა: პროთრომბინის დრო (PT), პროთრომბინული აქტივობა (PT%), საერთაშორისო ნორმალიზებული ფარდობა (INR), აქტივირებული პარციალური თრომბოპლასტინის დრო (APTT), თრომბინის დრო (TT), ფიბრინოგენის კონცენტრაცია (Fibrinogen) ხშირ შემთხვევაში ნორმის ფარგლებშია ან მისგან იმდენად უმნიშვნელოდ არის გადახრილი, რომ დაავადების დროული ამოცნობისთვის შესაფერ დასკვნის გაკეთების საშუალებას არ იძლევა. წარმოდგენილი კლინიკური შემთხვევა შეეხება 77 წლის მამაკაცს, რომელსაც საზარდულის ჩაჭედილი ირიბი თიაქრის გამო გაუკეთდა სასწრაფო ღია პერნიოპლასტიკა ბადის გამოყენებით. პოსტოპერაციულ პერიოდში ნაოპერაციებ მიდამოში ჩამოყალიბდა მზარდი კანქვეშა ჰემატომა. რის გამოც განმეორებით ჩატარდა ქირურგიული ჩარევა. ინტრაოპერაციული რევიზიით აქტიური სისხლდენის მიზეზი არ იქნა ნანახი. ჰემატოლოგის მიერ ჩატარებული დამატებითი კვლევებით პაციენტს აღმოაჩნდა I ტიპის VWD და ჩატარებული ადეკვატური კონსერვატიული მკურნალობით მიღწეული იქნა ჰემოსტაზი.

საკვანძო სიტყვები: პოსტოპერაციული ჰემორაგია, ფონ ვილბრანდის დაავადება, საზარდულის თიაქარი

SIMULTANEOUS PERFORATION OF THE ANTERIOR AND POSTERIOR WALLS OF THE STOMACH: A RARE CLINICAL CASE REPORT

Elguja Ardia¹, Avtandil Megreladze², Gia Tomadze², Teimuraz Sesitashvili²

¹ Petre Shotadze Tbilisi Medical Academy, ²Surgery Department, Tbilisi State Medical University, Georgia

Contact person: Gia Tomadze, g.tomadze@tsmu.edu

DOI: <https://doi.org/10.48412/GTBGS.2026.14-15.34-37>

Resume Gastric and duodenal ulcers are common diseases worldwide. Complications occur in 10–20% of patients, including perforation in 2–14% of cases. Ulcer perforation is more frequently found in the pyloric region of the stomach or in the proximal part of the duodenum. *Helicobacter pylori* infection, excessive use of nonsteroidal antiinflammatory drugs and steroids, as well as tobacco use, are considered the most common risk factors for ulcer formation in developing countries. Other risk factors include: postoperative stress, burns, and Zollinger–Ellison syndrome. Perforation of two peptic ulcers simultaneously is a rare occurrence, with only a few cases reported worldwide.

We present a rare clinical case of a 76-year-old woman who underwent emergency surgery for peritonitis caused by the simultaneous perforation of two gastric ulcers—one located on the anterior wall and the other on the posterior wall of the stomach. The first perforated ulcer was identified on the anterior gastric wall in the prepyloric region. In contrast, the second perforated ulcer was found on the posterior wall, primarily toward the body of the stomach.

As is known, only a few cases of simultaneous perforation of peptic ulcers have been described in the medical literature, including gastric and duodenal ulcers, two duodenal ulcers, and esophageal and duodenal ulcers. However, simultaneous perforation of two gastric ulcers is an exceptionally rare occurrence. All surgeons performing operations for perforated ulcers—whether open or laparoscopic—should be aware of and remember the rare but real possibility of two ulcers perforating at the same time.

Key words: peptic ulcer, ulcer perforation, simultaneous perforation of two gastric ulcers.

INTRODUCTION

Gastric and duodenal ulcers remain among the most common diseases of the gastrointestinal tract [1,2]. The annual incidence of peptic ulcer disease ranges from 0.1% to 0.3% [3]. There are two main risk factors: *Helicobacter pylori* infection and frequent use of nonsteroidal antiinflammatory drugs. Smoking, postoperative stress, and steroid abuse also increase the risk of ulcer development [4,5,6]. The incidence of ulcers increases with age, including both duodenal and gastric ulcers. Duodenal ulcers [7] tend to occur earlier than gastric ulcers, especially in men. Several factors predict an increased risk associated with nonsteroidal antiinflammatory drug use, such as *H. pylori* infection, older age, and adjuvant therapy with medications including corticosteroids and anticoagulants. Complications (bleeding, perforation, obstruction) can occur in patients with peptic ulcers of any etiology. Perforation occurs in approximately 5% to 10% of patients with active peptic ulcer disease. Duodenal, antral, and gastric body ulcers account for 60%, 20%, and 20% of peptic ulcer perforations, respectively [7,8]. Factors contributing to a poor prognosis in perforated peptic ulcers include early-stage shock, delayed diagnosis, metabolic acidosis, advanced age, low body mass index, and heavy tobacco use [9].

The most common site of perforated peptic ulcer is the anterior duodenal wall, with the pylorus being the second most common location [10,11]. Ulcers in the posterior duodenal wall cause erosion of the gastroduodenal artery, leading patients to present with hemorrhagic shock, whereas perforations of the anterior wall typically result in peritonitis.

Helicobacter pylori infection is considered the most important risk factor for the development of peptic ulcer disease. Although improved hygiene has reduced the incidence of *H. pylori* infection in developed countries, it still accounts for 10–20% of cases [12]. Studies have shown that 2–4% of individuals who regularly use nonsteroidal antiinflammatory drugs develop perforated peptic ulcers; tobacco use is also a significant risk factor in developing countries. A meta-analysis has demonstrated that 23% of peptic ulcers are due to tobacco use [13]. Other important risk factors include steroid abuse, alcohol consumption, postoperative stress, and Zollinger–Ellison syndrome (ZES).

Multiple peptic ulcer perforation is extremely rare, and only a few cases have been reported worldwide, with the causative factors including NSAIDs, ZES, postoperative stress, steroid use, burns, and Degos disease [14]. Our patient developed a double peptic ulcer perforation in the anterior and posterior gastric walls, which was caused

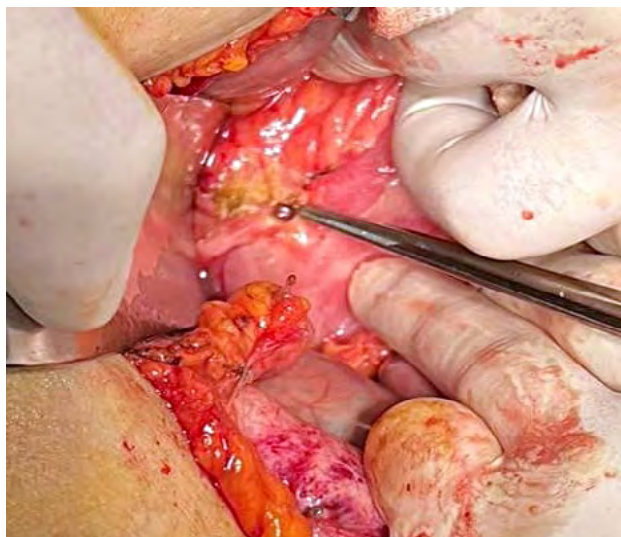


Figure 1. Perforated ulcer located in pyloroantral part of the stomach

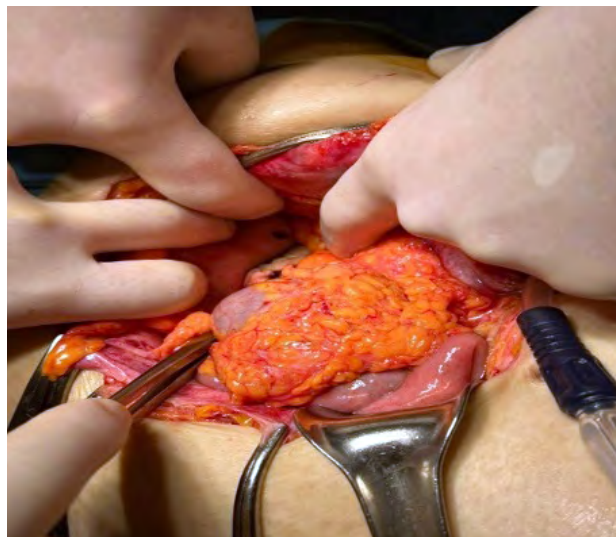


Figure 2. Perforated ulcer of the posterior gastric wall

by the use of high doses of NSAIDs due to postoperative stress and spinal pain.

Gastroduodenal perforation always requires urgent surgical intervention, either laparoscopic or open. Conservative treatment is possible only if there is minimal peritoneal effusion. The majority of patients can be managed conservatively with intravenous fluids, IV antibiotics, and proton pump inhibitors (PPIs) [15]. Conservative management requires the surgeon to continuously assess and monitor the patient's condition. Endoscopic techniques are used if the patient presents to the clinic within a short period (<24 hours) of symptom onset and the perforation is small [16]. Laparoscopic and open surgery have the same outcome. The only difference is that laparoscopic intervention is associated with less postoperative pain but a longer operating time [17]. Successful treatment of perforated peptic ulcers using a laparoscopic approach was first reported in 1990 [18]. Since then, various institutions have adopted this technique for treating patients with perforated peptic ulcers. Contraindications of laparoscopic treatment of perforated peptic ulcers include large perforation, previous abdominal surgery, posterior wall location of the perforation, and poor overall health of the patient. Our patient presented to the clinic 48 hours after symptom onset, with pronounced peritonitis and sepsis, which led to an open operation consisting of laparotomy, ulcerorrhaphy, and abdominal cavity sanitation and drainage.

CASE PRESENTATION

The patient, a 76-year-old woman, Ms. K.L., was brought to the clinic as an emergency case and admitted to the emergency department. She reported abdominal pain and discomfort, primarily in the lower abdomen, along with nausea, dry mouth, and general weakness. She had been experiencing severe pain over the past few months due to a cervical vertebra fracture and the postoperative condition following its fixation. Notably, the patient's

main complaints upon admission were severe spinal pain at the postoperative site and a dull pain and discomfort in the lower abdomen. On examination, the defect was not pronounced; palpation was painful, mainly in the lower abdomen; and Bloomberg's sign was positive in the lower abdomen, despite a soft abdominal wall. An abdominal radiograph and CT scan were performed, revealing free air in the abdominal cavity, including the subdiaphragmatic spaces. After appropriate preoperative preparation, which included correction of acid-base balance, blood gases, and electrolytes, and hemodynamic parameters, the patient underwent emergency surgery: laparotomy, suturing of two perforated gastric ulcers, and drainage of the abdominal cavity. Diffuse biliary-ulcerative peritonitis was found, with a callous ulcer measuring 0.5-0.5 cm and a perforated hole, perifocal inflammation, and a peritoneal fluid collection on the anterior wall of the pyloroantral part (Figure 1).

After suturing the first ulcer, a thorough lavage of the abdominal cavity was performed. During revision, a second perforated hole measuring 0.8x0.8 cm was identified on the posterior wall of the stomach, closer to the body (Figure 2). This perforated ulcer was then sutured. The postoperative course was uneventful. Treatment was carried out according to protocol, including a proton pump inhibitor, amoxicillin, and clarithromycin, along with correction of acid-base balance, blood gases, and electrolytes, as well as symptomatic management. On the 9th postoperative day, the patient was discharged from the clinic in satisfactory condition for outpatient follow-up under a gastroenterologist's supervision. Gastroscopy was performed according to the established protocol.

DISCUSSION

Peptic ulcer perforation is a surgical emergency that still carries a high risk of mortality. We successfully diagnosed and treated a rare case of synchronous perforation

of two gastric ulcers. Thorough intraoperative revision allowed us to identify a second perforated defect on the posterior wall of the stomach and eliminate this pathology. Finally, all surgeons should strictly adhere to the fundamental principle of abdominal surgery: performing a thorough revision of the abdominal cavity in all cases of diffuse peritonitis, even when the primary pathology is clearly visible.

CONCLUSION

All surgeons performing surgery for perforated ulcers, whether open or laparoscopic, should be aware of the rare but possible occurrence of simultaneous perforation of two ulcers. A thorough intraoperative examination of the abdominal cavity is the most effective method for detecting this rare pathology and preventing complications.

References:

1. Bansod, A. N., Lanjewar, S. M., Bansod, S. A., Choudhary, S. D., Shamkuwar, A. D., & Singh, K. H. (2015). Synchronous gastric and duodenal peptic perforation: A rare case report. *International Surgery Journal*, 2(1), 112–114.
2. Bansod, A., Bansod, S. A., Galande, A. B., Shamkuwar, A. T., & Singh, K. H. (2014). Study of the incidence of peptic ulcer perforation in young adults. *International Surgery Journal*, 1(3), 144–147.
3. Chan, F. K. L., & Leung, W. K. (2002). Peptic-ulcer disease. *The Lancet*, 360(9337), 933–941.
4. Daniel, S., Zietlow, J., & Zietlow, S. (2022). Perforated peptic ulcer. In *The acute management of surgical disease* (pp. 253–261). Springer International Publishing.
5. Etonyeaku, A. C., Agbakwuru, E. A., Akinkuolie, A. A., Omatola, C. A., Talabi, A. O., Onyia, C. U., Kolawole, O. A., & Aladesuru, O. A. (2013). A review of the management of perforated duodenal ulcers at a tertiary hospital in south western Nigeria. *African Health Sciences*, 13(4), 907–913.
6. Farooq, H. F., Sandeep, K., Abdul, H., Nowreen, S., & Mudasir, F. (2012). Synchronous dual perforation of gastrointestinal tract: A case series of two cases. *International Journal of International Science and Innovative Technology*, 1(5), 68–69.
7. Garcia Rodriguez, L. A., & Hernandez-Diaz, S. (2004). Risk of uncomplicated peptic ulcer among users of aspirin and non-aspirin nonsteroidal anti-inflammatory drugs. *American Journal of Epidemiology*, 159(1), 23–31.
8. Graham, D. Y. (1993). Ulcer complications and their nonoperative treatment. *Gastrointestinal Disease*, 698.
9. Goel, B., Rani, J., Huria, A., Gupta, P., & Dalal, U. (2014). Perforated duodenal ulcer—A rare cause of acute abdomen in pregnancy. *Journal of Clinical and Diagnostic Research*, 8(9), OD03–OD04.
10. Hashmi, J. Z., Hiraj, M. M., Saleem, F., Malik, U., & Mazari, I. K. (2022). Double peptic ulcer perforation due to cumulative effects of post-surgery stress and NSAIDs: A rare event in surgical practice. *Journal of the College of Physicians and Surgeons Pakistan*, 32(4), S21–S23.
11. Lau, J. Y. W., Sung, J., Hill, C., Henderson, C., Howden, C. W., & Metz, D. C. (2011). Systematic review of the epidemiology of complicated peptic ulcer disease: Incidence, recurrence, risk factors and mortality. *Digestion*, 84(2), 102–113.
12. Meng, Q. D., Ma, X. N., Wei, H., Pan, R. H., Jiang, W., & Chen, F. S. (2016). Lipomatous ganglioneuroma of the retroperitoneum. *Asian Journal of Surgery*, 39(2), 116–119.
13. Paspatis, G. A., Arvanitakis, M., Dumonceau, J. M., Barthet, M., Saunders, B., Turino, S. Y., Dhillon, A., Fragaki, M., Gonzalez, J. M., Repici, A., & van Wanrooij, R. L. (2020). Diagnosis and management of iatrogenic endoscopic perforations: European Society of Gastrointestinal Endoscopy (ESGE) position statement—Update 2020. *Endoscopy*, 52(9), 792–810.
14. Sonnenberg, A., & Everhart, J. E. (1997). Health impact of peptic ulcer in the United States. *The American Journal of Gastroenterology*, 92(4), 614–620.
15. Songne, B., Jean, F., Foulatier, O., Khalil, H., & Scotte, M. (2004). Nonoperative treatment for perforated gastroduodenal ulcer: Results of a prospective study. *Annales de Chirurgie*, 129(10), 578–582.
16. Triantafyllou, T., K., N., P., J., L., D., Z., G., & T., D. (2018). Double perforated kissing ulcers of the duodenum: A brief report. *International Surgery*, 103(1–2), 36–39.
17. Zittel, T. T., Jehle, E. C., & Becker, H. D. (2000). Surgical management of peptic ulcer disease today—Indication, technique and outcome. *Langenbeck's Archives of Surgery*, 385, 84–96.

Supplementary References:

- Biophytopharm. (n.d.). How beeswax can soothe gastric ulcers. <https://biophytopharm.com/how-beeswax-can-soothe-gastric-ulcers/>
- Health Digest. (n.d.). What a gastroenterologist wants patients to know about peptic ulcer disease. <https://www.healthdigest.com/1229995/what-a-gastroenterologist-wants-patients-to-know-about-peptic-ulcer-disease/>
- Jemere, T., Walle, G., Yideg, G., & Abebe, E. (2023). Helicobacter pylori infection and its associated factors among dyspepsia patients attending Debre Tabor Comprehensive Specialized Hospital, 2020. *PLoS ONE*, 18(3), e0279396. <https://doi.org/10.1371/journal.pone.0279396>
- Regional Medical Journal 4–5. (n.d.). Perforated gastric ulcer at Paholpolpayuhasena Hospital [Article in Thai]. <https://he02.tci-thaijo.org/index.php/reg45/article/view/129292>
- Samson, E. S. (2018). Screening for Helicobacter pylori infection among undergraduate students of a tertiary institution using serum antibody and stool antigen detection methods. *Biomedical Journal of Scientific & Technical Research*, 3(5). <https://doi.org/10.26717/bjstr.2018.03.000883>
- Sarosiek, S., Seldin, D. C., Berk, J. L., & Sanchorawala, V. (2013). A solitary mediastinal mass due to localized AL amyloidosis: Case report and review of the literature. *Amyloid*, 20(2), 127–130. <https://doi.org/10.3109/13506129.2013.775644>

The following additional references provide further context but are not directly cited in the main text

კუჭის წინა და უკანა კედლის წყლულების ერთდროული პერფორაცია: იშვიათი კლინიკური შემთხვევის აღწერა

ელგუჯა არდია¹, ავთანდილ მეგრელაძე², გია თომაძე², თემურაზ სესიტაშვილი²

¹ პეტრე შოთაძის თბილისის სამედიცინო აკადემია, ² თსუ ქირურგიული დეპარტამენტი

პასუხისმგებელი პირი: ელგუჯა არდია, elgujaardia1@gmail.com

DOI: <https://doi.org/10.48412/GTBGS.2026.14-15.34-37>

რეზიუმე კუჭისა და თორმეტგოჯა ნაწლავის წყლულოვანი დაავადება ფართოდ გავრცელებული პათოლოგიაა მთელ მსოფლიოში. გართულებები გვხვდება პაციენტების 10-20%-ში, მათ შორის პერფორაციით გართულება ვითარდება შემთხვევათა 2-14%-ში. წყლულის პერფორაცია უფრო ხშირად გვხვდება კუჭის პილორულ ნაწილში ან თორმეტგოჯა ნაწლავის დასაწყის ნაწილში. Helicobacter pylori-თ ინფექცია, არასტეროიდული ანთების საწინააღმდეგო საშუალებებისა და სტეროიდების ბოროტად გამოყენება, თამბაქოს მოხმარება, ითვლება წყლულის გამომწვევ ყველაზე გავრცელებულ რისკ-ფაქტორებად განვითარებად ქვეყნებში. სხვა რისკ-ფაქტორებია: ოპერაციის შემდგომი სტრესი, დამწვრობა და ზოლინგერ-ელისონის სინდრომი. ორი პეპტიური წყლულის პერფორაცია იშვიათი მოვლენაა, რომლის მხოლოდ რამოდენიმე შემთხვევაა დაფიქსირებული მთელ მსოფლიოში.

კლინიკური შემთხვევის აღწერა: წარმოგიდგინთ 76 წლის ქალბატონის იშვიათ კლინიკურ შემთხვევას, რომელსაც კუჭის ორი წყლულის (კუჭის წინა კედლისა და კუჭის უკანა კედლის წყლული) ერთდროული პერფორაციით გამოწვეული პერიტონიტის გამო ჩაუტარდა სასწრაფო ოპერაცია. აღმოჩნდა კუჭის წინა კედელზე, პრეპილორულ მიდამოში პირველი პერფორირებული წყლული, ასევე მის უკანა კედელზე, უპირატესად კუჭის სხეულისკენ მეორე პერფორირებული წყლული.

დასკვნა: მოგეხსენებათ სამედიცინო ლიტერატურაში აღწერილია მხოლოდ რამოდენიმე შემთხვევა პეპტიური წყლულის ერთდროული პერფორაციის შესახებ; ამავდროულად მეტი წილი ამ იშვიათი პათოლოგიიდან მოდის კუჭისა და თორმეტგოჯა ნაწლავის წყლულების ერთდროულ პერფორაციაზე, თორმეტგოჯა ნაწლავის ორი წყლულის ერთდროულ პერფორაციაზე, საყლაპავისა და თორმეტგოჯა ნაწლავის წყლულების ერთდროულ პერფორაციაზე, თუმცა იშვიათია კუჭის ორი წყლულის ერთდროული პერფორაციის შემთხვევა. ყველა ქირურგი, რომელიც ატარებს ოპერაციას პერფორირებული წყლულის გამო, როგორც ღია ასევე ლაპაროსკოპიული მეთოდით, უნდა იცოდეს და ახსოვდეს, რომ არსებობს იშვიათად, მაგრამ მანც ერთდროულად ორი წყლულის პერფორაციის შესაძლებლობა.

საკვანძო სიტყვები: პეპტიური წყლული, წყლულის პერფორაცია, კუჭის ორი წყლულის ერთდროული პერფორაცია

A RARE CASE OF GASTRIC VOLVULUS

Gia Azmaiparashvili^{1,2}, Gia Tomadze^{1,2}, Avtandil Megreladze^{1,2}, Baadur Kikalia², Manuchar Gvatadze², Mamuka Goletiani^{1,2}, Alexander Gvazava^{1,2}

¹Department of Surgery, International Faculty of Medicine and Dentistry, Tbilisi State Medical University

²LTD Pineo Medical Ecosystem

Contact person: Gia Azmaiparashvili, g.azmaiparashvili@tsmu.edu

DOI: <https://doi.org/10.48412/GTBGS.2026.14-15.38-40>

Rezume

Gastric volvulus is a very rare disease, accounting for approximately 0.5% of all abdominal volvulus cases. It presents as acute or chronic abdominal pain and vomiting, most commonly in young and middle-aged individuals, or in young children with congenital gastrointestinal anomalies. The hallmark features are impaired blood supply to the gastric tissues and obstruction of the gastrointestinal passage. Diagnosis relies on gastroscopy, radiological imaging, and computed tomography. Prompt surgical intervention is mandatory to prevent complications.

The paper discusses the case of a 66-year-old woman who complained of diffuse abdominal pain, bloating, nausea, general weakness, vomiting, and inability to tolerate both food and liquids. Her history included laparoscopic cholecystectomy and Nissen-type surgery on the esophagus (which presumably became the cause of gastric volvulus). Using the above investigations, the diagnosis was established, and emergency surgery was performed. The stomach was of large size, markedly distended, occupying almost the entire abdominal cavity, twisted by 180 degrees, and fixed by dense adhesions. The pyloro-antral part of the stomach was displaced beneath the diaphragm; both the esophagus and the duodenum were twisted. This represented gastric volvulus, due to which the esophagus and duodenum were non-patent. Posterior to the esophagus, the transverse colon, together with the greater omentum, was visualized. There was a pronounced adhesive process around the stomach. Adhesiolysis and visualization of anatomical structures were achieved. Detorsion of the stomach and reposition of the transverse colon to the anatomical location were carried out after dismantling the esophageal "cuff" (previous Nissen-type procedure). Patency of the esophagus, stomach, and duodenum was restored. Gastropexy of the fundus and antrum to the anterior abdominal wall was performed, after which the stomach and duodenum assumed their physiological position. The stomach color was normal. The postoperative period was uneventful. The patient was discharged from the clinic on day 4. Contemporary diagnostic methods allow rapid diagnosis and emergency surgery for this rare pathology. Surgical management includes adhesiolysis, detorsion of the stomach, restoration of patency of the esophagus, stomach, and duodenum, and gastropexy.

Key words: stomach, volvulus, adhesiolysis, gastrotomy, gastrorrhaphy, esophagorrhaphy, detorsion, gastropexy.

INTRODUCTION

Gastric volvulus is the twisting of a hollow organ around its axis with displacement. It leads to impaired blood supply to gastric tissue and disrupted passage of gastrointestinal contents [3,4]. The disease presents with severe upper abdominal pain, persistent vomiting, and abdominal distension. Diagnosis is clinical, radiologic [computed tomography], and endoscopic [7,12]. Surgical intervention is required, including correction of torsion and fixation of the stomach to the abdominal wall [1,3,11].

The disease is rare, accounting for 0.5% of cases of abdominal volvulus. It occurs in young and middle-aged individuals. Congenital gastrointestinal anomalies occur in early childhood. Delayed diagnosis often leads to high mortality [4,8,13,15]. The condition's etiology is unknown and is most often linked to individual anatomical features, such as constitutional weakness, underdeveloped gastric ligaments, and gastrointestinal developmental defects [1,2,6,15].

The following conditions contribute to disease development. Diaphragmatic hernia is the most frequent cause. Risk also increases with phrenic nerve damage, leading to diaphragmatic relaxation. Plant-based or very fatty foods

increase risk. Increased intra-abdominal pressure from chronic constipation, persistent cough, or frequent vomiting is another cause [3,5,12].

Gastric volvulus can follow surgeries like small intestine resection, fundoplication for reflux, and truncal vagotomy [2,9,10,14].

Two pathogenetic stages of gastric volvulus exist. In the first stage, the stomach twists less than 180 degrees, making it hard for food to pass into the intestine. In the later stage, the twist exceeds 180 degrees. The upper and lower stomach openings close, resulting in a serious blockage. Decreased blood flow to the stomach wall increases tissue death. This can lead to stomach wall perforation and severe abdominal infection. If untreated, the death rate is 50%. Early on, traumatic shock and spleen rupture are risks; later, there is a high chance of inflammation of the lung lining and pneumonia [1,2,6,9,13].

Diagnosis is difficult due to rare, non-specific signs. Investigations include radiography, endoscopy, CT, and laparoscopy.

Emergency surgery is always required for gastric volvulus. Conservative therapy fails.

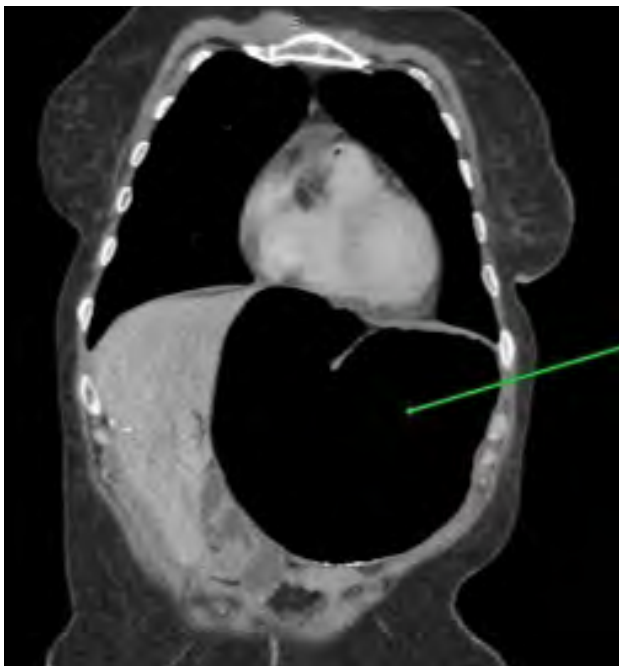


Figure 1. CT image demonstrating a distended and twisted stomach.

Early diagnosis and modern surgery lead to good outcomes [3,7,9,12].

CLINICAL CASE

We present a case from our practice. T.M., a 66-year-old woman, was admitted to the clinic on 27.10.2025 as an emergency. On admission, she reported diffuse abdominal pain, bloating, nausea, weakness, and vomiting even after drinking liquids.

Brief history: She previously underwent appendectomy; in April 2025, she had a laparoscopic cholecystectomy and Nissen fundoplication for a hiatal hernia.

Symptoms progressed over five days; the patient could not tolerate food or liquids, had severe pain [especially in the upper abdomen], and sought care at our clinic.

Clinical, lab, and imaging studies were performed.

Ultrasound showed no free fluid. Intestines were distended with gas. The stomach held large amounts of liquid.

Gastroscopy showed swollen, soaked mucosa above the cardiac sphincter; the scope could not pass beyond. Neither the stomach nor the duodenum could be seen, and a biopsy probe could not be inserted. This raised the question: Is there a narrowing in the lower third of the esophagus?

A CT scan of the abdominal cavity in angiographic mode was performed. No free fluid or gas was detected in the abdominal or pelvic cavities. After intravenous bolus contrast injection, the aorta and major vessels were patent; no pathological stenoses or dilatations were noted. Oral contrast did not pass beyond the esophagus, which was dilated and filled with fluid content. The stomach was displaced and markedly distended, containing a large amount of liquid and gas; the lumen was narrowed both proximally and distally. The pylorus was abnormally located, subdiaphragmatic, and a left gastric volvulus was suspected. The transverse colon was displaced and visualized

medial to the stomach. The remaining structures showed no remarkable changes. Figure 1.

Emergency surgery was performed the same day. Laparotomy was done through a midline incision from the xiphoid process to the left of the umbilicus. The stomach was large, distended, and occupied almost the entire abdominal cavity. It was twisted 180 degrees and fixed by dense adhesions. The pyloro-antral part was beneath the diaphragm. Both the esophagus and duodenum were twisted, making neither patent, and the stomach was severely distended. Posterior to the esophagus, the transverse colon and greater omentum were visible. Dense adhesions surrounded the stomach, making anatomical differentiation difficult.

Due to technical difficulties, blunt and sharp adhesiolysis was performed. Anatomical structures were visualized. Detorsion was achieved after adhesiolysis and gastrotomy. Gastric decompression via a nasogastric tube was performed. Placement of the tube was possible after decompression, which was not possible before due to volvulus. Gastrorrhaphy was performed. Adhesiolysis on the lesser and greater curvatures followed. The transverse colon was repositioned to its anatomical location. Suturing of the deserosated esophagus was carried out, and the exposed lesser curvature was restored. The gastrocolic ligament was also reconstructed. A nasogastric tube was advanced via the Treitz ligament into the jejunum by 15 cm. An additional nasogastric tube was placed through the other nostril. Patency of the esophagus, stomach, and duodenum was restored. Gastropexy of the fundus and antrum to the anterior abdominal wall was then performed, resulting in physiological positioning of the stomach and duodenum. Gastric walls were pink and viable. The abdominal cavity was irrigated with Betadine solution. Hemostasis was complete. Two drains were placed: one in the Douglas pouch, exteriorized through a separate counterincision in the right iliac fossa; the second in the left iliac fossa, exiting via the left lateral gutter.

The postoperative period was uneventful. The patient was discharged on postoperative day 4 in satisfactory condition under outpatient care. She had no complaints. Sutures were removed on an outpatient basis, and the wound healed by primary intention.

CONCLUSION:

Gastric volvulus is an extremely rare pathology, and timely diagnosis is sometimes difficult. With modern clinical, laboratory, and instrumental diagnostics such as ultrasound, gastroscopy, and computed tomography, timely recognition and emergency surgery are possible. Surgical management includes adhesiolysis, detorsion, restoration of patency of the esophagus, stomach, and duodenum, and gastropexy. It should be assumed that in the presented case, the cause was laparoscopic cholecystectomy and Nissen-type antireflux surgery performed five months earlier. This case demonstrates the critical importance of early diagnosis and adequate treatment.

References:

1. Basaran, U. N., Inan, M., Ayhan, S., et al. (2002). Acute gastric volvulus due to deficiency of the gastrocolic ligament in a newborn. *European Journal of Pediatrics*, 161, 288–290.
2. Bimal, P. S., Kalra, N., & Suri, S. (2000). CT features of acute phlegmonous gastritis. *Journal of Clinical Imaging*, 24, 287–288.
3. Boopathy, V., & Balasubramanian, P. (2017). Chronic gastric volvulus—Diagnosed on endoscopy. *Journal of Clinical and Diagnostic Research*, 11(8), 1. <https://doi.org/10.7860/JCDR/2017.28547.10392>
4. Carreno, G., Sanchez, R., Alonso, R. A., et al. (2001). Laparoscopic repair of Bochdalek's hernia with gastric volvulus. *Surgical Endoscopy*, 15, 1359.
5. Channer, L. T., Squires, G. T., & Price, P. D. (2000). Laparoscopic repair of gastric volvulus. *JSLs*, 4, 225–230.
6. Darani, A., Mendoza-Sagaon, M., & Reinberg, O. (2005). Gastric volvulus in children. *Journal of Pediatric Surgery*, 40, 855–858.
7. Esteveao-Costa, J., Soares-Oliveira, M., Correia-Pinto, J., et al. (2000). Acute gastric volvulus secondary to a Morgagni hernia. *Pediatric Surgery International*, 16, 107–108.
8. Harinath, G., Senapati, P. S., Pollitt, M. J., & Ammori, B. J. (2002). Laparoscopic reduction of an acute gastric volvulus and repair of a hernia of Bochdalek. *Surgical Laparoscopy, Endoscopy & Percutaneous Techniques*, 12, 180–183.
9. Komuro, H., Matoba, K., & Kaneko, M. (2005). Laparoscopic gastropexy for chronic gastric volvulus complicated by pathologic aerophagia in a boy. *Pediatrics International*, 47, 701–703.
10. Kuenzler, K. A., Wolfson, P. J., & Murphy, S. G. (2003). Gastric volvulus after laparoscopic Nissen fundoplication with gastrostomy. *Journal of Pediatric Surgery*, 38, 1241–1243.
11. Patoulis, D., Rafailidis, V., Kalogirou, M., Farmakis, K., Rafailidis, D., & Patoulis, I. (2017). Acute primary mesenteroaxial gastric volvulus in a 6-year-old child: The contribution of ultrasonographic findings to prompt diagnosis (Case report and review of the literature). *Folia Medica Cracoviensia*, 57(3), 47–55.
12. Al Daoud, F., Daswani, G. S., Perinjelil, V., & Nigam, T. (2017). Acute organoaxial gastric volvulus: A massive problem with a twist—Case report. *International Journal of Surgery Case Reports*, 41, 366–369. <https://doi.org/10.1016/j.ijscr.2017.11.016>
13. Shidakov, I. H., Kalniyazov, B. M., & Karaev, A. A. (2018). Acute gastric volvulus with perforation. *Kubanskiy Nauchnyy Medicinskiy Vestnik*, 25(3), 173–177. <https://doi.org/10.25207/1608-6228-2018-25-3-173-177>
14. Korkmazov, M. S. (2000). Kinks and volvulus of the stomach in children (Candidate of Medical Sciences dissertation). Moscow.
15. Kurguzov, O. P. (1998). Gastric volvulus. *Khirurgiya*, (4), 62–68.

კუჭის შემოგრების იშვიათი შემთხვევა

გია აზმაიფარაშვილი^{1,2}, გია თომაცე^{1,2}, ავთანდილ მეგრელაძე^{1,2}, ბაადურ კიკალია², მანუჩარ ლავთაძე², მამუკა გოლეთიანი^{1,2}, ალექსანდრე გვაზავა^{1,2}

¹თსუ მედიცინისა და სტომატოლოგიის საერთაშორისო ფაკულტეტის ქირურგიის დეპარტამენტი
²შპს „პინეო სამედიცინო ეკოსისტემა“

პასუხისმგებელი პირი: გია აზმაიფარაშვილი, g.azmaiparashvili@tsmu.edu

DOI: <https://doi.org/10.48412/GTBGS.2026.14-15.38-40>

რეზიუმე მუცლის ღრუში განვითარებულ ორგანოთა შემოგრებებს შორის კუჭის შემოგრება ძალზე იშვიათია - სულ 0,5%. პათოლოგია შეინიშნება ახალგაზრდა და საშუალო ასაკის პირებში. კუჭ-ნაწლავის ტრაქტის თანდაყოლილი ანომალიების დროს გვხვდება მცირეწლოვან ბავშვებში. პათოლოგიას თან ახლავს კუჭის ქსოვილების სისხლით მომარაგების დარღვევა და კუჭ-ნაწლავის ტრაქტის შიგთავსის პასაჟის გაუარესება. დიაგნოსტიკა ხდება გასტროსკოპიით, რენტგენოლოგიური და კომპიუტერული ტომოგრაფიული კვლევით. საჭიროებს სასწრაფო ქირურგიულ ოპერაციას. ნაშრომში განხილულია ორ წლის ქალის შემთხვევა, რომელიც უჩიოდა დიფუზური ხასიათის ტკივილს მუცლის არეში, შეხებრილობას, გულსრევას, საერთო სისუსტეს, ღებინებას, ვერ იღებს ვერც საკვებს და ვერც სითხეებს. ანამნეზში ლაპაროსკოპული ქოლაციტექტომია და საყლაპავზე ნისენის ტიპის ოპერაცია (სავარაუდოდ ეს უკანასკნელი გახდა კუჭის შემოგრების მიზეზი). ზემოთ აღნიშნული კვლევებით დადგინდა დიაგნოზი და გაკეთდა სასწრაფო ოპერაცია. კუჭი დიდი ზომის, გადაბერილი, იკავებდა თითქმის მთელ მუცლის ღრუს, შემოგრებული 180°-ით, ფიქსირებული ტლანქი შეხორცებითი ზონრებით. კუჭის პილორო-ანტრალური ნაწილი ასული დიაფრაგმის ქვეშ; შემოგრებული იყო როგორც საყლაპავი, ასევე თორმეტგოჯა ნაწლავი. საქმე ეხებოდა კუჭის შემოგრებას, რის გამოც დარღვეული იყო საყლაპავის და თორმეტგოჯა ნაწლავის გამავლობა. საყლაპავის უკან ვიზუალიზაცია გახდა კოლინჯი მთლიანად, დიდ ბადექონთან ერთად. კუჭის ირგვლივ ძლიერი შეხორცებითი პროცესი. მოხერხდა სინექიოლიზი და ანატომიური სტრუქტურების ვიზუალიზაცია. მოხდა კუჭის დეტორზიო და განივი კოლინჯის რეპოზიცია ანატომიურ ადგილას საყლაპავიდან „მუფტის“ მოხსნის შემდეგ (წარსულში „ნისენის“ ტიპის ოპერაცია). აღდგა საყლაპავ-კუჭ-თორმეტგოჯა ნაწლავის გამავლობა. გაკეთდა მუცლის წინა კედელზე კუჭის ფუნდუსის და ანტრუმის მიდამო პექსია; კუჭმა და თორმეტგოჯა ნაწლავმა მიიღეს ფიზიოლოგიური მდებარეობა. კუჭის ფერი - ნორმალური. პოსტოპერაციული პერიოდი გართულებების გარეშე. ავადმყოფი კლინიკიდან გაეწერა მე-4 დღეს. თანამედროვე კვლევებით შესაძლებელია ამ იშვიათი პათოლოგიის დიაგნოზის სწრაფი დასა და სასწრაფო ოპერაციის გაკეთება. ოპერაციაში იგულისხმება სინექიოლიზი, კუჭის დეტორზიო, საყლაპავ-კუჭის და თორმეტგოჯა ნაწლავის გამტარობის აღდგენა და გასტროპექსია.

საკვანძო სიტყვები: კუჭი, შემოგრება, სინექიოლიზი, გასტროტომია, გასტრორაფია, ეზოფაგორაფია, დეტორზიო, გასტროპექსია.

BILE DUCT INJURY AFTER LAPAROSCOPIC CHOLECYSTECTOMY AND METHODS OF PREVENTION OF THIS COMPLICATION - CASE REPORT

Nika Khetagurova¹, Irakli Pipia², Giorgi Kopadze², Anano Tvaladze², Grigol Nemsadze^{1,2}, Zaza Demetrashvili^{1,2}

¹Tbilisi State Medical University; ²N. Kipshidze's Central University Clinic

Contact person: Nika Khetagurova, nika.khetagurova@gmail.com

DOI: <https://doi.org/10.48412/GTBGS.2026.14-15.41-47>

Resume We described a case of successful treatment of common hepatic duct injury during laparoscopic cholecystectomy in a subject with acute calculous cholecystitis complicated with Mirizzi syndrome. On the 3rd postoperative day following laparoscopic cholecystectomy, the patient developed mechanical jaundice and bile leakage from the abdominal drain. CT, MRCP, and ERCP have confirmed common hepatic duct injury (E3 according to the Strasberg-Bismuth classification). On the 10th day, the reconstructive operation with formation of hepaticojejunal anastomosis by Roux. In the article, we described methods for preventing bile duct injuries during laparoscopic cholecystectomy (critical view of safety, Rouviere's sulcus, "fundus-first" technique, subtotal cholecystectomy, and the use of fluorescent indocyanine green).

Key words: Laparoscopic cholecystectomy; Bile duct injury.

CASE PRESENTATION

Patient, female, 24 years old, arrived at the emergency department with pain in the right upper quadrant, which irradiated to the back; nausea and vomiting; temperature (38.5 C°); general weakness. Presenting symptoms, which occurred several days ago, were exacerbated on the day of arrival at the hospital.

Physical examination indicated positive Murphy's sign. Ultrasonography: sludge and calculus in the gallbladder. Ultrasound examination after patient repositioning revealed an immobile calculus in Hartmann's pouch. Diagnosis: acute calculous cholecystitis. The surgical team performed a Laparoscopic Cholecystectomy (LC) within a few hours, during which the surgeon encountered the following complicating factors:

1. Mirizzi syndrome has been diagnosed and classified as 3A according to the latest Carmen Payá-Llorente classification compiled in 2017 [1] (Fig. 1).
2. The gallbladder is located near the level of confluence, which could confuse the identification of important anatomical structures (Fig. 2).
3. Left and right intrahepatic ducts were located deep in the parenchyma, which made it impossible to identify the location and configuration of confluence.
4. The right intrahepatic duct passed in proximity to the wall of the gallbladder, which led to the accidental injury of the duct during the separation of the gallbladder from the visceral surface of the liver (Fig. 3).

During the first postoperative days, the patient presented with bile in the drainage, jaundice, and pain in the right subcostal area.

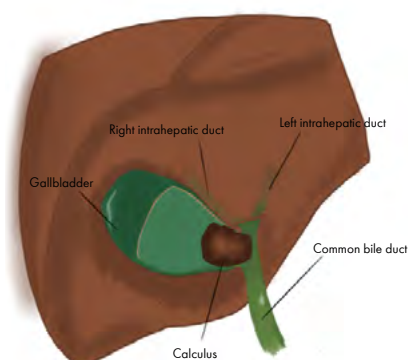


Figure 1. Preoperative picture of patient's bile ducts on arrival (13.09.2023)

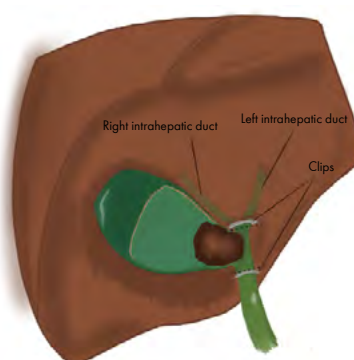


Figure 2. Clipping of common bile duct: proximal clip is 2-3 mm below confluence; The distal clip is on the common bile duct

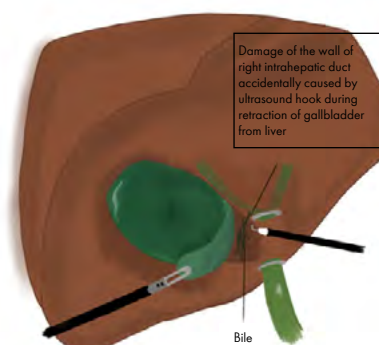


Figure 3. Damage of the wall of right intrahepatic duct during separation of gallbladder with ultrasound hook

Table 1. The table shows dynamic of dilatation of left hepatic duct during all intrahospital period

The date of investigation	The width of left hepatic duct
13.09 1st operation	4mm
15.09	4mm
20.9	5mm
22.09 ERCP; 2nd operation	6mm
26.09	4.8mm
30.09	2.5mm

On the 5th day after LC, an investigation of the bile ducts was conducted in axial/sagittal/portal planes using T2, FIESTA, and MRCP modes. Imaging revealed an insignificant amount of fluid collection and infiltrative changes within the postoperative abdominal cavity. Fluid collection

persisted throughout the postoperative period until discharge.

The dynamics of left hepatic duct dilatation were traced from the moment the patient arrived at the clinic (table 1).

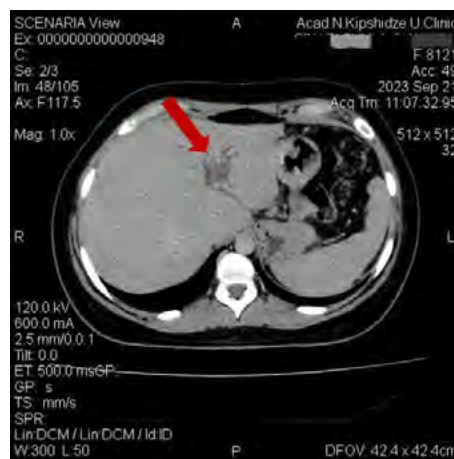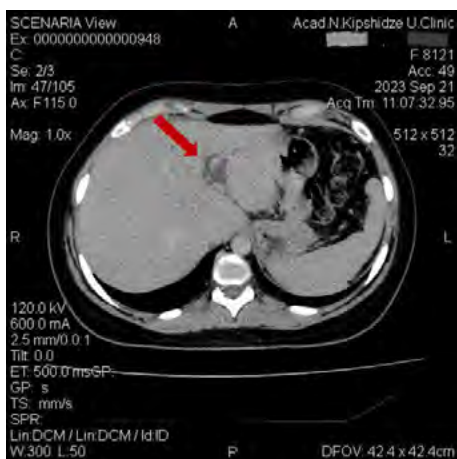


Figure 5. Damage of the wall of right intrahepatic duct during separation of gallbladder with ultrasound hook.

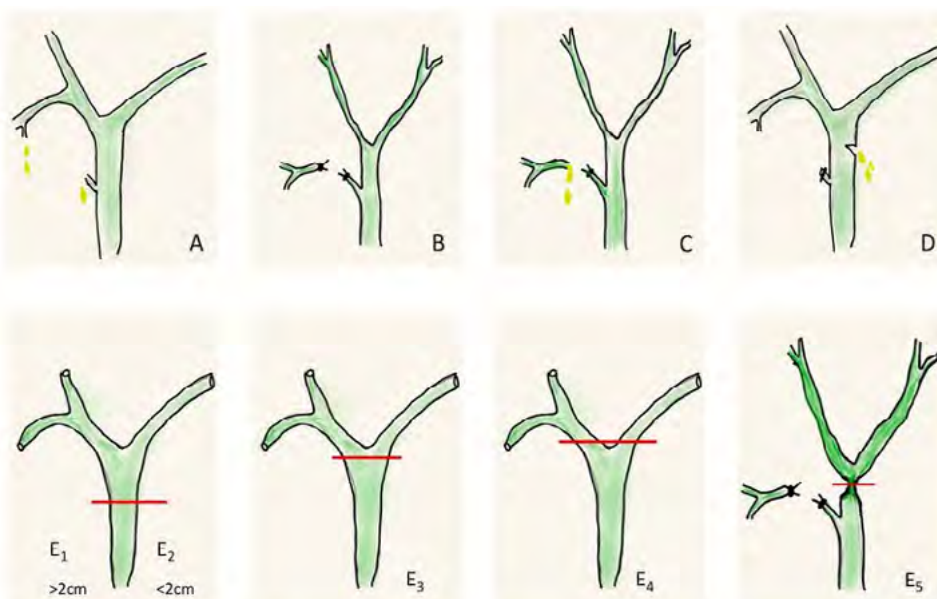


Figure 6. Bismuth-Strasberg classification of bile duct injury.

Resource: https://www.researchgate.net/figure/Bismuth-Strasberg-classification-of-bile-duct-injury-A-Bile-leak-from-cystic-duct-or_fig2_332358086

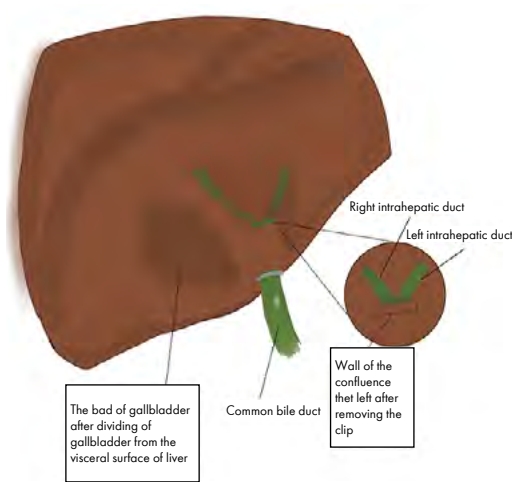


Figure 7. The picture of patient's bile ducts after LC

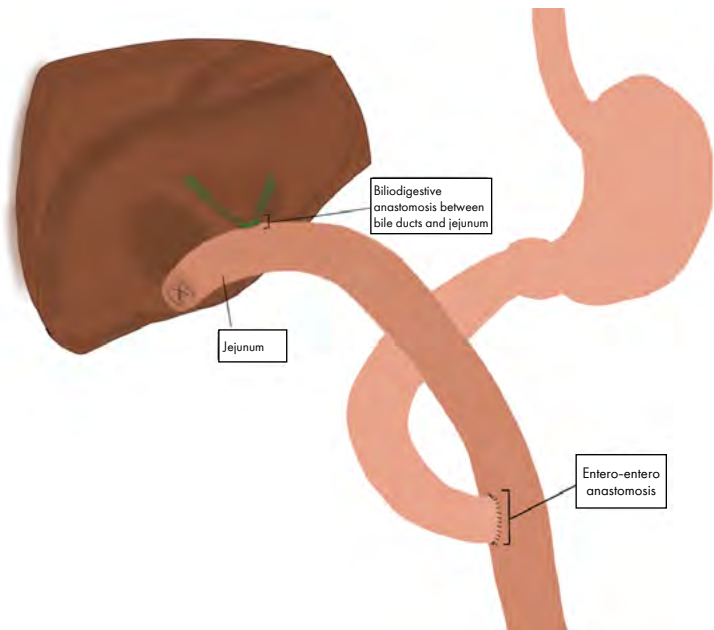


Figure 8. The result of reconstructive operation: biliodigestive anastomosis; formation of hepatojejunal anastomosis by Roux.

On the 8th day after LC, we conducted a Computer Tomography (CT) contrast in angiography mode and found a clip on the distal part of the right hepatic duct. The left hepatic duct is dilated, measuring 6 mm in diameter (normal up to 2 mm). Based on CT results, we identified an iatrogenic injury to the common bile duct near the confluence. (Fig.5)

After obtaining more detailed results from Endoscopic Retrograde Cholangiopancreatography (ERCP), it has been decided to proceed with a reconstructive operation. The laparotomy was conducted, during which surgeons found out that a proximal clip was placed 2-3 mm below confluence and the right intrahepatic duct had been

damaged, which had led to bile leakage. The distal clip was placed on the Common Bile Duct (CBD). Part of the Common Hepatic Duct (CHD) between the proximal and distal clips was present. The patient had E3 biliary injury according to the Bismuth-Strasberg classification [2] (Fig. 6), so no confluence between the right and left hepatic ducts was considered. However, ducts were not fully divided. Damage was on the level of confluence, and the superior intrahepatic wall of this confluence was intact. (Fig. 7) Hepato-jejunal anastomosis by Roux was formed intraoperatively. (Fig. 8) Postoperative period passed without complications. The patient was discharged on the 12th

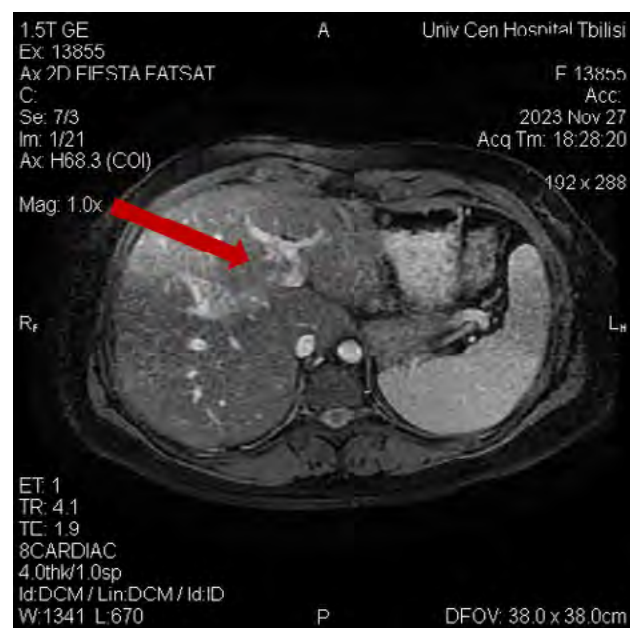
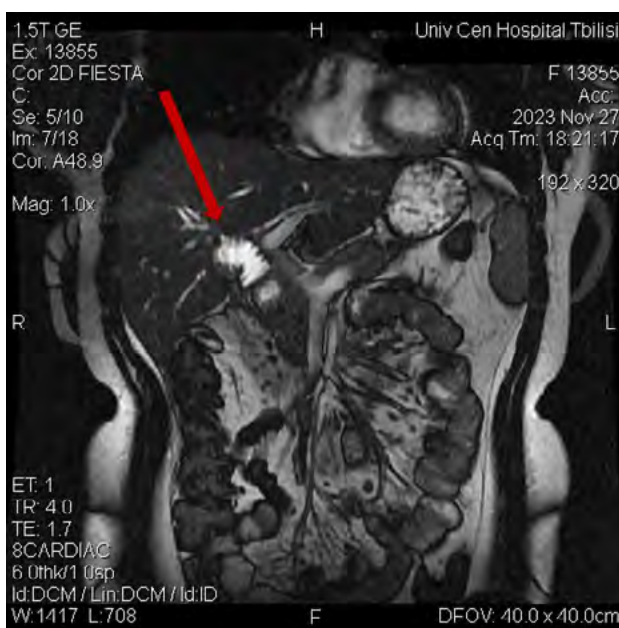

Figure 9. MRI and CT results in one month after reconstructive operation. The pces where anastomosis has been placed is pointed with arrow.

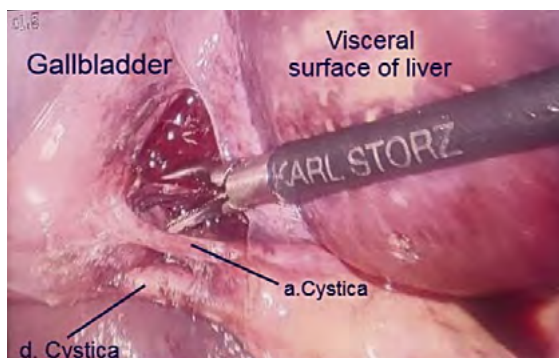


Figure 10. Clearance of surrounded tissue from hepatocystic triangle

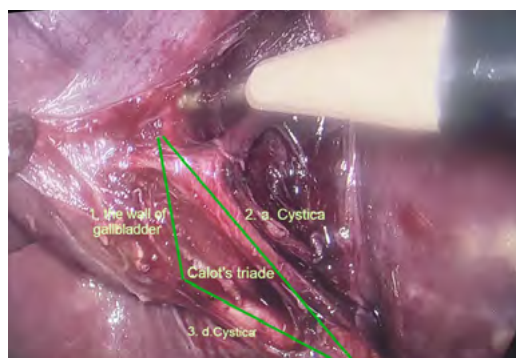


Figure 11. Visualisation of vascular structures (Calot's triangle)

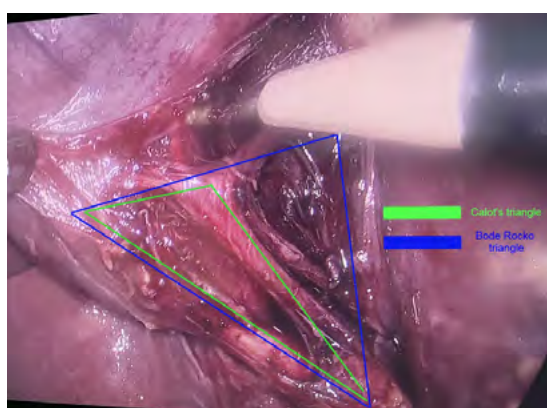


Figure 12. The difference between Calot's triangle and Bode Rocko triangle. Green: Calot's triangle; Blue: Bpde Rocko triangle.

postoperative day. The patient has returned to a common lifestyle in 6 months. (Fig. 9)

Iatrogenic injuries after LC occur in 0.5% of cases. In the present hepatobiliary surgery, some rules and techniques for conducting safe LC were highlighted.

1. CVS

First applied 30 years ago, Critical View of Safety (CVS) has become a gold standard for all surgeons performing laparoscopic cholecystectomy (LC).

This technique includes 3 steps:

1. Dissection of the surrounding tissue from important vascular structures. (Fig. 10)
2. Separation of the lower 1/3 of the gallbladder from the liver.
3. Visualisation of vascular structures. [3]

According to the Tokyo Guidelines 2018 (TG18) [4], surgeons should adhere to the 3 steps of CVS to minimize the risk of Bile Duct Injury (BDI) and cystic artery bleeding.

In this technique, the key role is played by Calot's triangle, the borders of which are formed by crucial structures that should be identified precisely: the cystic duct (laterally), the cystic artery (superiorly), and the common bile duct (medially). (Fig. 11) Throughout these years, Calot's triangle has become an inevitable part of LC. However, sometimes, if the liver margin is counted as the upper border of the triangle, it is modified in the Bode Rock triangle (hepatocystic). (Fig. 12) As the cystic artery (which is traditionally considered as the upper board of Calot's triangle)

has different variants of performing and can compromise the CVS, the Bode Rocko triangle is considered a safe and clear method for conducting CVS. First, the inferior margin of the liver is a constant structure with no anatomical variations. Another point is that in the Bode-Rocko triangle, surgeons can identify the Lund or Moskagni node, which is also a helpful landmark in patients with normal BMI. [1]

Despite its advantages and the need to provide CVS, this technique falls short of accurately representing the biliary tree's unconventional anatomy. For instance, according to the prevalence-based classification of anatomical biliary variants [6], the presence of type 4 and type 5 variants can lead to misinterpretation of the patient's anatomy, with subsequent postoperative complications even with conducted CVS. This fact also represents the usefulness of using the Bode Rocko triangle instead of Calot's triangle. Moreover, Mirrizzi syndrome also makes it impossible for a surgeon to visualize vascular structures and skeletonize them. In such cases, CVS fails, and the gold standard for resolution of these situations is subtotal cholecystectomy, which will be considered later.

2. Rouviere's sulcus (RS)

For surgeons, it is also important to precisely determine the level of soft-tissue dissection due to the high risk of Common Bile Duct Injury (CBDI) and Cystic Artery Bleeding (CAB).

This line is placed between Rouviere's sulcus and the umbilical ligament. Rouviere's line allows defining the safe

level of manipulation in the Bode Rocko triangle area to avoid complications [5]. Thus, after representing this imaginary line, the surgeon should adhere to the rule which can be briefly formulated as "over-done, under-none!", so the operator should not work under the level of Rouviere's line.

Rouviere's sulcus is used during both LC and open cholecystectomy. Though during LC, the visualisation of this structure is better. Rouviere's sulcus can be seen as either a white line or a true sulcus. It can be classified according to profundity and appearance: open, closed, slit, and scar [7]. The open sulcus continues to the porta hepatis and can be measured with length, breadth, and depth. Closed sulcus is partly visible and looks like a fossa in the parenchyma of the Vth segment. Slit sulcus is the last visible grade of sulcus, where only length can be measured. The scar sulcus appears as a white line with no relief differences compared to the surrounding parenchymatous tissues.

Nevertheless, in some patients, we cannot detect Rouviere's sulcus, which may be an anatomical variation. In this case, it becomes impossible to use this landmark.

3. "Fundus-first" technique

In some cases, when CVS fails and a traditional approach is not feasible, the "fundus-first" technique is the last step before more radical bailout strategies, such as subtotal cholecystectomy or conversion to open cholecystectomy.

The concept of "fundus-first", also known as "fundus down", "retrograde cholecystectomy" or "dome down", differs from the traditional approach only at the beginning, from the fundus of the gallbladder, because the CVS cannot be completed. The reasons can include: adhesions in the area of Calot's triangle or the Bode-Rocko triangle; severe inflammation; BMI \leq 30; Mirizzi syndrome; an anomalous bile duct; necrotic changes around the gallbladder and in Calot's triangle; and other reasons. Beginning with the dissection of the gallbladder from the visceral surface of the liver, the procedure proceeds to the cystic duct and cystic artery, culminating in their visualisation and clipping. Thus, "fundus-first" allows precise identification of the structures entering the gallbladder and clips them [8].

"Fundus-first" technique is a controversial way of conducting cholecystectomy because it is associated with a

high risk of Vascular-Biliary Injury (VBI). Anatomical variations in the elements of the porta hepatis make it impossible for the surgeon to reduce the risk of VBI, especially in patients with chronic inflammation, biliary inflammatory fusion, and contraction [9]. Moreover, clipping the cystic artery at the end of gallbladder retraction is associated with greater blood loss during the operation [5].

Though, the dissection about merits and demerits of this technique continue, Society of American Gastroenterologists and Endoscopic Surgeons (SAGES) gives a recommendation: "When the critical view of safety cannot be achieved and other methods during laparoscopic cholecystectomy cannot clearly define the biliary anatomy, we suggest that surgeons consider subtotal cholecystectomy over total cholecystectomy by the fundus-first (top down) approach (expert opinion)" [10]. Moreover, the Tokyo Guidelines 2018 state that, in cases of severe inflammation of the Calot's triangle, this technique can offer an alternative to LC without risk of BDI or conversion to open cholecystectomy [4].

4. Subtotal cholecystectomy

Subtotal cholecystectomy (STC) is one of the bailout procedures that allows for gallbladder removal in cases when CVS is impossible to achieve. STC is the last feasible laparoscopic way of treating acute cholecystitis before the last existing option- open cholecystectomy, which is associated with high risks of complications.

STC can be divided into 2 types: fenestrating and reconstituting.

I - Fenestrating STC

The fenestrating way of conducting STC includes the excision of the peritonealised part of the gallbladder; extraction of the content of the gallbladder, and closure of the cystic duct from inside the gallbladder using a purse-string suture. [11]

While excising the peritonealised part of the gallbladder, the surgeon should leave the lowest edge. This part serves as a "shield" to help prevent BDI while working in Hartman's pouch. This landmark, called the "shield" of McElmoyle, is presented as an important detail in fenestrating STC [11] (Fig. 13).

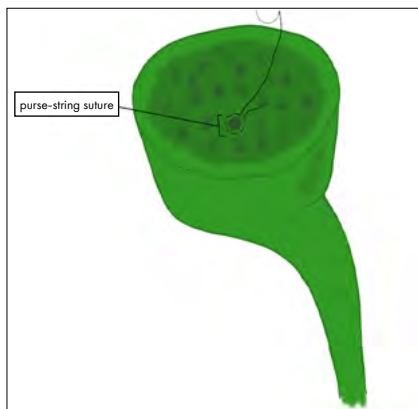


Figure 13. Fenestrating STC



Figure 14. Reconstituting STC; the stump

II - Reconstituting STC

The difference between fenestrating and reconstituting STC lies in the last steps: in reconstituting STC, the surgeon should close the remnant of the gallbladder with interrupted sutures, as shown in the picture (Fig 14) [11]

As we can see, the choice between fenestrating and reconstituting the STC depends on whether to close the cystic duct from within or leave the gallbladder stump.

Depending on the chosen technique, some advantages and disadvantages can be achieved. More preference is given to fenestrating STC because of decreased risks of postoperative complications, such as gallbladder remnant, associated with the lowest part of the gallbladder, which is left re-established as it performs in reconstituting STC. On the other hand, the use of fenestrating STC can lead to the incidence of bile fistula, and this kind of complication is less likely to occur after reconstituting STC. However, it was concluded that of these 2 postoperative complications, the bile fistula is less problematic, as it has resolved spontaneously in many patients [11]. In contradiction to this, gallbladder remnant exacerbated the quality of patients' lives, causing pain, jaundice, and fever, so it requires reoperation.

The most reasonable decision in cases with STC to reduce the risk of complications is to perform it in a reconstructive manner using that small stump, which can be equivalent to cystic duct closure, as in fenestrating STC [11].

5. Fluorescent Indocyanin Green

Using Indocyanin Green (ICG) during acute cholecystectomy is a relatively new method of visualisation of bile

ducts in patients with severe inflammation, Mirizzi syndrome, and bile duct or gallbladder tumors [12].

To provide an LC with augmented reality, the clinic should have special equipment that compares two wavelength-isolated light sources: a white light source and a near-infrared light source. When ICG is administered, it is metabolized within 2-5 min and excreted by the liver cells within 10 min. ICG reaches its peak in 2-2.5 hours [13]. That is why, in elective cases, the use of ICG is more relevant than in urgent operations, where time plays a key role. At the same time, visualization of bile ducts using ICG is more necessary in urgent cholecystectomies. However, the fluorescent pigment's representation can take a comparatively long time in an emergency.

ICG can be used not only for BDI prediction, but also for bleeding prevention. When a surgeon has difficulty identifying the cystic artery, the i/v injection of ICG solution can be used. This intraoperative administration method can provide visualisation of the artery in 20-40 sec over a 20-30 sec period [13].

The SAGES recommends ICG integration LC routine: "We suggest that the use of near-infrared imaging can be considered as an adjunct to white light alone for identification of biliary anatomy during cholecystectomy. Guideline Development Group (GDG) noted that relying on near-infrared imaging must not be a substitute for good dissection and identification technique (expert opinion)" [10].

This modern way of predicting BDI and bleeding has its own advantages and disadvantages, presented in the table below (Table 2).

Table 2. Advantages and disadvantages of using ICG imaging during LC

Advantages of ICG imaging	Disadvantages of ICG imaging
1. Ability to provide individual approach to patients' anatomy	1. High price of ICG liquid
2. Visualisation of feasible aberrant ducts	2. Complementary special equipment.
3. Ability of visualizing either ducts or arteria	3. Long representation time
4. Control of bile leakage as a result of BDI during all steps of operations	4. Difficulties in exploitation during emergency operations because relatively long time of representation (1.5 - 2 h)
5. Ability to visualise bile ducts in patient with Mirizzi syndrome and primary or secondary tumors of bile ducts	5. Possible allergic reactions, including intraoperation anaphylaxis

References:

1. Payá-Llorente, C., Vázquez-Tarragón, A., Alberola-Soler, A., Martínez-Pérez, A., Martínez-López, E., Santarrufina-Martínez, S., Ortiz-Tarín, I., & Armañanzas-Villena, E. (2017). Mirizzi syndrome: a new insight provided by a novel classification. *Annals of Hepatobiliary and Pancreatic Surgery*, 21(2), 67–75. <https://doi.org/10.14701/ahbps.2017.21.2.67>
2. Kumar, S., Gorla, P., & Chandra, A. (2019). Bile duct injury: To err is human; To refer is divine. *BMJ Case Reports*, 12, e228361. <https://doi.org/10.1136/bcr-2018-228361>
3. Gupta, V., & Jain, G. (2019). Safe laparoscopic cholecystectomy: Adoption of universal culture of safety in cholecystectomy. *World Journal of Gastrointestinal Surgery*, 11(2), 62–84. <https://doi.org/10.4240/wjgs.v11.i2.62>
4. Wakabayashi, G., Iwashita, Y., Hibi, T., Takada, T., Strasberg, S. M., Asbun, H. J., Endo, I., Umezawa, A., Asai, K., Suzuki, K., Mori, Y., Okamoto, K., Pitt, H. A., Han, H.-S., Hwang, T.-L., Yoon, Y.-S., Yoon, D.-S., Choi, I.-S., Huang, W. S.-W., ... Yamamoto, M. (2018). Tokyo Guidelines 2018: Surgical management of acute cholecystitis: Safe steps in laparoscopic cholecystectomy for acute cholecystitis (with videos). *Journal of Hepato-Biliary-Pancreatic Sciences*, 25(1), 73–86. <https://doi.org/10.1002/jhbp.517>

5. Alius, C., Serban, D., Bratu, D. G., Tribus, L. C., Vancea, G., Stoica, P. L., Motofei, I., Tudor, C., Serboiu, C., Costea, D. O., et al. (2023). When critical view of safety fails: A practical perspective on difficult laparoscopic cholecystectomy. *Medicina*, 59(8), 1491. <https://doi.org/10.3390/medicina59081491>
6. Janssen, B., van Laarhoven, S., Elshaer, M., Cai, H., Praseedom, R., Wang, T., & Liau, S.-S. (2021). Comprehensive classification of anatomical variants of the main biliary ducts. *British Journal of Surgery*, 108(4). <https://doi.org/10.1093/bjs/znaa147>
7. Voruganti, M. R., Mohammed, N., Gurralla, R. C., et al. (2023). Rouviere's sulcus: Anatomy and its clinical significance in laparoscopic cholecystectomy. *World Journal of Laparoscopic Surgery*, 16(1), 4–7. <https://doi.org/10.5005/ijp-journals-10033-1553>
8. Huang, S. M., Hsiao, K. M., Pan, H., Yao, C. C., Lai, T. J., Chen, L. Y., Wu, C. W., & Lui, W. Y. (2011). Overcoming the difficulties in laparoscopic management of contracted gallbladders with gallstones: Possible role of fundus-down approach. *Surgical Endoscopy*, 25(1), 284–291. <https://doi.org/10.1007/s00464-010-1175-y>
9. Strasberg, S. M., & Gouma, D. J. (2012). 'Extreme' vasculobiliary injuries: Association with fundus-down cholecystectomy in severely inflamed gallbladders. *HPB*, 14(1), 1–8. <https://doi.org/10.1111/j.1477-2574.2011.00393.x>
10. Brunt, L. M., Deziel, D. J., Telem, D. A., Strasberg, S. M., Aggarwal, R., Asbun, H., Bonjer, J., McDonald, M., Alseidi, A., Ujiki, M., Riall, T. S., Hammill, C., Moulton, C.-A., Pucher, P. H., Parks, R. W., Ansari, M. T., Connor, S., Dirks, R. C., Anderson, B., ... Stefanidis, D. (n.d.). Safe cholecystectomy multi-society practice guideline and state of the art consensus conference on prevention of bile duct injury during cholecystectomy. Society of American Gastrointestinal and Endoscopic Surgeons. <https://www.sages.org/publications/guidelines/safe-cholecystectomy-multi-society-practice-guideline/>
11. Strasberg, S. M., Pucci, M. J., Brunt, L. M., & Deziel, D. J. (2016). Subtotal cholecystectomy—"Fenestrating" vs "reconstituting" subtypes and the prevention of bile duct injury: Definition of the optimal procedure in difficult operative conditions. *Journal of the American College of Surgeons*, 222(1), 89–96. <https://doi.org/10.1016/j.jamcollsurg.2015.09.019>
12. Hiwatashi, K., Okumura, H., Setoyama, T., Ando, K., Ogura, Y., Aridome, K., Maenohara, S., & Natsugoe, S. (2018). Evaluation of laparoscopic cholecystectomy using indocyanine green cholangiography including cholecystitis: A retrospective study. *Medicine*, 97(30), e11654. <https://doi.org/10.1097/MD.00000000000011654>
13. Kashchenko, V. A., Emelyanov, S. I., Strizheletsky, V. V., et al. (2023). Integration of ICG-fluorescence cholangiography into the safety system of laparoscopic cholecystectomy. *Pirogov Russian Journal of Surgery*, (11), 89–98. <https://doi.org/10.17116/hirurgia202311189> Sonnet 4.6

სანალვლე სადინრის დაზიანება ლაპაროსკოპიული ქოლეცისტექტომიის შემდეგ და ამ ბართულების პრევენციის მეთოდები (კლინიკური შემთხვევის აღწერა)

ნიკა ხეთაგუროვა¹, ირაკლი ფიფია², გიორგი კოპაძე², ანანო თვალაძე², გრიგოლ ნემსაძე^{1,2}, ზაზა დემეტრაშვილი^{1,2}

¹ თბილისის სახელმწიფო სამედიცინო უნივერსიტეტი; ²ნ. ყიფშიძის ცენტრალური საუნივერსიტეტო კლინიკა

პასუხისმგებელი პირი: ნიკა ხეთაგუროვა, nika.khetagurova@gmail.com

DOI: <https://doi.org/10.48412/GTBGS.2026.14-15.41-47>

რეზიუმე ჩვენ აღწერეთ, ლაპაროსკოპიული ქოლეცისტექტომიის დროს, საერთო სანალვლე სადინრის დაზიანების (თანდართული მირიზის სინდრომით) წარმატებული მკურნალობის შემთხვევა. ლაპაროსკოპიული ქოლეცისტექტომიიდან მე-3 დღეს, პაციენტს აღენიშნა მქანუკური სიყვითლე და დრენაჟებიდან გამოიხატა სანალვლოვანი გამონადენი. საერთო სანალვლე გზის დაზიანება ("Strasberg-Bismuth" კლასიფიკაციის შესაბამისად E3) დადასტურებულ იქნა კომპიუტერული ტომოგრაფიით (CT), ენდოსკოპიური ქოლანგიოპანკრეატოგრაფიით (ERCP) და მაგნიტურ-რეზონანსული ქოლანგიოპანკრეატოგრაფიით (MRCP). სანალვლე გზების რეკონსტრუქცია, ჰეპატიკოიეიუნოსტომია Roux-en-y შესრულდა მე-10 დღეს. სტატიაში ჩვენ აღწერეთ ლაპაროსკოპიული ქოლეცისტექტომიის დროს სანალვლე გზების დაზიანების პრევენციის მეთოდებს (უსაფრთხოების კრიტიკული ველი, Rouviere-ის ღარი, ქოლეცისტექტომია ფუნდუსიდან მიდგომით, სუბტოტალური ქოლეცისტექტომია, ინდოციანინის მწვანეს გამოყენება).

საკვანძო სიტყვები: ლაპაროსკოპიული ქოლეცისტექტომია; სანალვლე სადინრის დაზიანება.

FEATURES OF OPEN SURGICAL TRACHEOSTOMY IN INTENSIVE CARE UNIT (ICU) PATIENTS

Theimuraz Sesitashvili^{1,2}, Gia Tomadze¹, Ana Tsirekidze^{1,2}, Avthandil Megreladze¹

¹*Surgery Department, Tbilisi State Medical University, Georgia;*

²*St.Michalel's Hospital, Department of General Surgery, Georgia*

Contact person: Gia Tomadze, g.tomadze@tsmu.edu

DOI: <https://doi.org/10.48412/GTBGS.2026.14-15.48-50>

Rezume

Tracheostomy is the most common procedure in the intensive care unit. Its indication is mainly prolonged intubation. Various studies have determined that 10% of intubated patients require a tracheostomy.

The article discusses the anatomical features of the neck, trachea, and thyroid gland. 70 cases of open surgical tracheostomy performed in intensive care patients over a continuous two-year period are presented, including 53 (75.7%) patients over 60 years of age.

The importance of correct positioning of the patient on the operating table and selection of a skin incision on the anterior surface of the neck is presented. Technical aspects of the operation, selection of the correct localization of the tracheal incision by the surgical team. In intensive care patients, preference is given to relatively "high" tracheostomies, mobilization of the isthmus and edges of the thyroid gland.

Open surgical tracheostomy in intensive care patients is not an easy operation to perform. The operation must be performed in an operating room with appropriate equipment, by a suitably qualified team.

Key words: Tracheostomy; Open Surgical Technique; Intensive Care Unit; Mechanical Ventilation; Thyroid Gland Anatomy.

Tracheostomy represents one of the oldest known surgical procedures, with images dating back to 3600 BC. In the early twentieth century, Chevalier Jackson established the principles of tracheostomy, which clinicians still follow today [1,2,3].

The term "tracheostomy" refers to the surgical creation of a stoma that opens the trachea onto the anterior surface of the neck.

Tracheostomy currently constitutes the most common surgical procedure in patients receiving mechanical ventilation. Various studies report that intensive care unit physicians perform tracheostomy in approximately 10% of ICU patients. The main indications for this procedure include prolonged endotracheal intubation, frequent lower airway clearance, and upper airway obstruction [1,6]. Many authors consider it appropriate to perform tracheostomy after 9–10 days of intubation [1,2,5].

Although tracheostomy is the most frequently performed surgical procedure in intensive care patients, surgeons have not yet established a single, universally accepted method [5]. We usually describe the tracheostomy as upper, middle, or lower, in relation to the thyroid isthmus. Because the anatomical relationships vary considerably, the terms "upper" and "lower" do not always correspond to "high" and "low" tracheostomy. This has been emphasized by V.S. Lyande (1957) and M.K. Perelman (1972) [6].

According to various authors, the trachea consists of 16–20 or 18–22 cartilaginous rings. In the cervical re-

gion, surgeons usually identify 4–5 rings; every 1 cm of tracheal length contains roughly two rings, each about 4 mm wide. On average, the trachea measures 10–13 cm in men and is shorter in women.

The isthmus of the thyroid gland most commonly overlies the 2nd to 4th tracheal rings [3,4,7].

The anatomical configuration of the thyroid gland also plays an important role. In 1895, C.F. Marshall noted that it is difficult to define a single "normal" anatomy of the thyroid gland. He proposed a classification based on differences in the presence and position of the pyramidal lobe and described 17 distinct forms [7].

Large-scale studies from the UK, which analyzed 70 general intensive care units, showed that performing a tracheostomy within the first 4 days of ICU care does not reduce mortality. These studies also demonstrated that intensive care physicians cannot reliably predict which patients will ultimately require tracheostomy [1,2,5,6].

In 1998–2000, M.A. Ognerubov and co-authors described 12 variants of thyroid morphology:

1. Pyramidal lobe on the right (12%)
2. Pyramidal lobe in the center (17%)
3. Pyramidal lobe on the left (31.4%)
4. Butterfly-shaped (30.6%)
5. Without a bridge (lobes separated) (21.7%)
6. Asymmetrical (11.2%)
7. Large and wide isthmus (8%)
8. Thin and narrow isthmus (8.25%)

9. Triangular shape (10.8%)
10. Crescent shape (12.8%)
11. "H" shape (11.1%)
12. Without a bridge, with lobes in close contact (3.3%)

The upper edge of the thyroid gland may extend from the lower border of the thyroid cartilage to the lower border of the cricoid cartilage. In contrast, the lower edge may reach from the cricoid cartilage to the suprasternal notch. Surgeons encounter a wide and large isthmus in about 8% of cases and observe closely apposed lobes without an isthmus in approximately 3.4% of patients [7].

Anatomical variants of the thyroid and trachea strongly depend on typical features of the neck, particularly on absolute measurements of neck length and width [7].

Many authors recommend that surgeons perform open surgical tracheostomy, with rare exceptions, in a fully equipped operating room, with adequate lighting and instrumentation, and under the supervision of a team of experienced surgeons and anesthesiologists [2,3,4].

The patient lies in the supine position, and the surgeon fully extends the neck by placing a pillow or bolster under the shoulders and tilting the head backward. The neck must remain in the midline. Before starting the incision, the surgeon identifies and marks key landmarks from the cricoid cartilage down to the suprasternal notch [2,3,4].

Investigators classify tracheostomy complications as intraoperative, early postoperative (up to 7 days), and late (after 7 days). Engels P.T. et al. [5,6] report that the most frequent complication of open surgical tracheostomy is paratracheal placement of the tracheostomy tube (up to 10%), which can lead to subcutaneous emphysema and pneumomediastinum. In the early postoperative period, the most common complications include bleeding (up to 80%), wound infection (up to 63%), and unintended decannulation (up to 15%). Among late complications, tracheal stenosis occurs in up to 63% of cases, and patients may also develop a rigid tracheostomy tract after decannulation [5,6].

Most authors prefer a transverse skin incision, placed midway between the cricoid cartilage and the jugular fossa [1,2,3]. Some Russian authors recommend a longitudinal midline incision from the cricoid cartilage to the jugular fossa in critically ill patients, due to both the severity of their condition and the technical challenges of the operation [5].

After incising the skin and superficial cervical fascia and retracting the prethyroid muscles, the surgeon usually divides the thyroid isthmus to expose the operative segment of the trachea [3]. The surgeon then performs transverse tracheal dissection between rings 2–3 or 3–4. If necessary, the surgeon can pull the trachea upward and forward using a tracheal hook, which facilitates fixation of the skin to the edges of the tracheal opening [1,2,3,5].

In this article, we present 70 cases of open surgical tracheostomy performed in intensive care unit patients over a continuous 2-year period. During the same period, we also performed three emergency tracheostomies in patients outside the intensive care unit. In extremely severe, prac-

tically hopeless patients with a very short, wide neck, we created six tracheostomies between the first and second tracheal rings and three between the cricoid cartilage and the first tracheal ring. We also performed one conicotomy between the thyroid and cricoid cartilages in an extremely critically ill ICU patient.

We usually performed tracheostomy on days 9–10 of mechanical ventilation. In six patients, we operated on the first or second day for other indications, not for prolonged ventilation.

Patient age ranged from 17 to 92 years. Fifty-three patients (75.7%) were older than 60 years; the cohort included 36 females and 34 males.

We carried out almost all operations under general anesthesia in the operating room. Only in two extremely critically ill patients did we perform the procedure directly in the intensive care unit. Correct patient positioning proved crucial: we placed a pillow under the shoulders and carefully aligned the neck in both the sagittal and frontal planes.

Most intensive care patients in our series were elderly and showed some degree of cervical spine ankylosis, which was further aggravated by prolonged immobilization during mechanical ventilation. Consequently, we often could not achieve sufficient head extension for optimal surgical exposure. In relatively young patients with a normal neck length, full extension increases the distance between the cricoid cartilage and the suprasternal notch to about 6 cm. In elderly, short-necked patients, this distance may decrease to about 3 cm. In five patients, we observed a rotated neck; even after repositioning the head, we could not fully center the trachea in the operative field. All these factors significantly complicated the surgery.

In all cases, we used a Kocher-type transverse arcuate skin incision measuring 5–6 cm and locally excised excess subcutaneous fat down to the third cervical fascia. After additional fascial mobilization, we extended the incision longitudinally from the lower edge of the thyroid cartilage to the suprasternal notch. Once we opened the second fascia longitudinally, we exposed the thyroid gland and the anterior tracheal wall.

In intensive care patients, we prefer to create a relatively "high" tracheostomy. In most cases, this approach requires resecting the isthmus and performing limited mobilization or resection of the adjacent thyroid lobes.

After incising the trachea, we can pull it upward and, if necessary, construct a relatively "low" tracheostomy between the third and fourth rings. However, in short-necked patients, this configuration may lead to problems in the postoperative period. When the head remains relatively elevated, the traction can cause skin fixation sutures to cut through the skin near the trachea. We observed this complication in 2 of our patients.

During the operation, the anesthesiologist advances the endotracheal tube as far as possible toward the tracheal bifurcation. This maneuver provides crucial information about the trachea's orientation and reduces the risk of

cuff injury. After we obtain this information, we decide on the exact site of the tracheal incision.

In all cases, we closed the mobilized edges of the thyroid gland with Z-sutures to ensure reliable hemostasis. We performed tracheostomy without manipulating the thyroid gland in only 11 of 70 patients (15.7%).

In most cases, we transected the trachea transversely between rings 1–2 or 2–3. We fixed the upper and lower skin flaps to the edges of the tracheal opening with two sutures each and then placed additional skin sutures laterally. We inserted an adjustable-length tracheostomy tube, which allowed us to adjust the tube position in patients with a short neck and a short trachea. At the end of the procedure, we placed a dressing under the tracheostomy site and secured the tube around the neck with straps that provided moderate compression.

We did not observe any major postoperative complications. The only issues involved two cases in which the skin fixation sutures cut into the skin.

CONCLUSION:

Open surgical tracheostomy in critically ill, elderly, mechanically ventilated patients is not a simple procedure. Surgeons should, whenever possible, perform this operation in a fully equipped operating room, working together with experienced anesthesiology and surgical teams. The surgeon must determine the precise level of the tracheostomy intraoperatively, taking into account the individual anatomy of the neck, trachea, and thyroid gland. In patients who require prolonged mechanical ventilation, we recommend relatively "high" tracheostomies, which generally demand appropriate intervention on the thyroid gland.

References:

1. El-Anwar, M. W., Nofal, A. A.-F., El Shawadfy, M. A., Maaty, A., & Khazbak, A. O. (2016). Tracheostomy in the intensive care unit: A university hospital in a developing country study. *International Archives of Otorhinolaryngology*. <https://doi.org/10.1055/s-0036-1584297>
2. Muscat, K., Bille, A., & Simo, R. (2017). *A guide to open surgical tracheostomy*. Guy's and St. Thomas' NHS Foundation Trust, Head and Neck and Thoracic Surgery Units, London, UK.
3. Raimonde, A. J., Gaston, S., & Wang, C. F. (2025). *Tracheostomy*. National Library of Medicine, National Institutes of Health.
4. Furlow, P. W., & Mathisen, D. J. (2018). *Surgical anatomy of the trachea*. *Annals of Cardiothoracic Surgery*, 7(2), 255–260.
5. Engels, P. T., Bagshaw, S. M., Meier, M., & Brindley, P. G. (2009). *Tracheostomy: From insertion to decannulation*. *Canadian Journal of Surgery*, 52(5), 427–433.
6. Kolesnikov, V. N., Khanamirov, A. A., Dashevsky, S. P., & Suntsov, V. V. (2017). [Tracheostomy in intensive care unit patients: Current state of the problem]. *Khirurgiya–Reanimatsiya [Surgery–Resuscitation]*.
7. Kruzina, E. A. (2018). [Analysis of the frequency and causes of tracheostomy complications in intensive care unit patients of multidisciplinary hospitals in Moscow] (Doctoral dissertation, Moscow).
8. Ognerubov, N. A., Zhukov, A. O., & Sergeev, R. S. (2016). [Individual features of the surgical anatomy of the thyroid gland: A literature review]. *Meditsina*, 21(2).

ღია ქირურგიული ტრაქეოსტომიის თავისებურებები რეანიმაციული განყოფილების პაციენტებში

თეიმურაზ სესიტაშვილი^{1,2}, გია თომაძე¹, ანა ცირეკიძე^{1,2}, ავთანდილ მეგრელაძე¹

¹ თსსუ ქირურგიული დეპარტამენტი, ² წმინდა მიქაელის ჰოსპიტალი, ზოგადი ქირურგიის დეპარტამენტი

პასუხისმგებელი პირი: გია თომაძე, g.tomadze@tsmu.edu

DOI: <https://doi.org/10.48412/GTBGS.2026.14-15.48-50>

რეზიუმე ტრაქეოსტომია ინტენსიური თერაპიის განყოფილებაში ყველაზე გავრცელებული ქირურგიული პროცედურაა. მისი ჩვენება ძირითადად არის ხანგრძლივი ინტუბაცია. სხვადასხვა კვლევით დადგენილია, რომ ინტუბირებული პაციენტების 10%-ს ესაჭიროება ტრაქეოსტომია. სტატიაში განხილულია კისრის, ტრაქეის და ფარისებრი ჯირკვლის ანატომიური თავისებურებები. წარმოდგენილია უწყვეტ ორწლიან პერიოდში რეანიმაციულ პაციენტებში ჩატარებული ღია ქირურგიული ტრაქეოსტომის 70 შემთხვევა, მათ შორის, 60 წელს ზემოთ 53 (75,7%). წარმოდგენილია საოპერაციო მაგიდაზე პაციენტის სწორი პოზიციონირების და კისრის წინა ზედაპირზე კანის განაკვეთის შერჩევის მნიშვნელობა. ოპერაციის მსვლელობის ტექნიკური ასპექტები, ტრაქეის კვეთის სწორი ლოკალიზაციის შერჩევა ქირურგიული ბრიგადის მიერ. რეანიმაციულ პაციენტებში უპირატესობა ენიჭება შედარებით „მაღალ“ ტრაქეოსტომიებს, ფარისებრი ჯირკვლის ისთმუსის და კიდების მობილიზაციას. რეანიმაციულ პაციენტებში ღია ქირურგიული ტრაქეოსტომია არ წარმოადგენს მარტივად შესასრულებელ ოპერაციას და ის უნდა ჩატარდეს სათანადო აღჭურვილობის მქონე საოპერაციოში, სათანადო კვალიფიკაციის მქონე ბრიგადის მიერ.

საკვანძო სიტყვები: ტრაქეოსტომია; ღია ქირურგიული ტექნიკა; ინტენსიური თერაპიის განყოფილება; მექანიკური ვენტილაცია; ფარისებრი ჯირკვლის ანატომია.

CARCINOID TUMOR OF THE APPENDIX (NEUROENDOCRINE TUMOR OF THE APPENDIX) IN THE SETTING OF ACUTE APPENDICITIS: A CLINICAL CASE OF A 19-YEAR-OLD PATIENT

Kakhaber Kikvidze, Sergo Abramian, Gia Chukhua, David Butkhuzi, Solomon Kerashvili

Iv. Bokeria University Hospital, Department of General Surgery and Transplantology

Contact person: David Butkhuzi, butxuzi@yahoo.com

DOI: <https://doi.org/10.48412/GTBGS.2026.14-15.51-54>

Resume | **Background:** Appendiceal neuroendocrine tumors (ANETs) are rare and often present alongside acute appendicitis [1, 4]. Tumors larger than 2 cm are associated with high oncological risk according to leading guidelines (NCCN, ENETS) [11, 12]. Determining the extent of surgery (achieving R0 resection status) in emergency settings remains a complex clinical dilemma [7]. **Case Presentation:** We present the case of a 19-year-old patient diagnosed with acute appendicitis and a concomitant massive mass measuring 81x42 mm with regional lymphadenopathy on CT scan [9]. Based on high intraoperative oncological suspicion, a one-stage right hemicolectomy was performed. Pathomorphology confirmed an appendiceal carcinoid with cecal invasion, achieving R0 resection. **Conclusion:** Our case underscores that in the presence of high-risk factors (size ≥ 2 cm, suspected invasion), one-stage radical surgical intervention is a legitimate and ethically justifiable risk [10].

Key words: Appendiceal Neuroendocrine Tumor, Carcinoid, Acute Appendicitis, Hemicolectomy, R0 Resection, Ki-67.

INTRODUCTION:

Relevance of the Topic and Clinical Challenge

Appendiceal neuroendocrine tumors (ANETs) represent a comparatively rare neoplastic entity [1]. Approximately one-third of these tumors present without specific clinical symptomatology; instead, they produce luminal obstruction of the vermiform appendix, which manifests clinically as the classic presentation of acute appendicitis [8]. This scenario places the operating surgeon in an exceptionally challenging intraoperative situation. During emergency surgery, where inflammatory infiltration obscures the operative field, the clinician must recognize a potentially malignant neoplasm and make an appropriate tactical decision.

In oncological surgery, the primary objective of any resection is to achieve R0 status — a resection margin free of neoplastic cells — to preclude R1 or R2 resection, both of which substantially worsen the patient's oncological prognosis.

AIMS OF THE STUDY

The present study aims to:

1. Drawing upon the most recent international consensus guidelines (NANETS [6], ENETS [12], and NCCN [11]), we delineate the critical determinants of ANET management: tumor size, depth of invasion, and lymphadenopathy.
2. Through detailed analysis of a clinical case, to substantiate the legitimacy of single-stage radical surgical intervention as the preferred approach to achieving R0 resection, notwithstanding diagnostic uncertainty.

LITERATURE REVIEW:

Controversy in the Surgical Management of ANETs

The surgical management of ANETs remains a subject of considerable debate among oncological and colorectal surgeons [4]. The principal challenge lies in the fact that acute appendicitis entirely masks the clinical presentation of appendiceal neuroendocrine tumors, and clinicians frequently identify them as incidental findings. In these circumstances, the surgeon must make intraoperative decisions under significant time constraints [7].

Historically, because clinicians regarded carcinoid tumors as comparatively indolent neoplasms, they often managed them conservatively and considered a simple appendectomy sufficient. However, pathomorphological studies and long-term observational data accumulated over recent decades have demonstrated that the biological behavior of these lesions is not uniform [1, 2]. Consequently, tumor size has emerged as the foremost anatomical criterion in determining the appropriate management strategy.

The Philosophical Dilemma in Surgical Management: Conservatism versus Radicalism

- Conservative approach (appendectomy): Proponents of this strategy argue that the majority of tumors — particularly small lesions (≤ 1 cm) — carry a minimal risk of metastatic dissemination [2].
- Radical approach (hemicolectomy): This position is grounded in the primacy of oncological safety. Advocates contend that whenever there is any suspicion of invasion or regional lymph node involvement, lym-

phatic dissection is necessary to achieve R0 resection. In their view, the risk of R1/R2 resection is considerably greater and less acceptable from an oncological standpoint [10].

The Two-Stage Management Concept: Risk Factors for Tumors Measuring 1–2 cm

The greatest degree of tactical uncertainty arises in the management of tumors measuring 1–2 cm in greatest dimension [7]. The literature favors a two-stage approach in such cases: initial appendectomy followed by comprehensive pathomorphological examination of the resected specimen.

Additionally, decisive risk factors that justify the performance of hemicolectomy [11] include:

1. **Ki-67 index and tumor grade:** A Ki-67 proliferation index of $\geq 3\%$ is indicative of aggressive biological behavior [5, 6, 12].
2. **Invasion of the cecal wall:** When the tumor extends to the base of the appendix, appendectomy alone carries a near-certain risk of R1 residual disease [7, 12].
3. **Lymphovascular invasion:** The identification of neoplastic cells within blood vessels or lymphatic channels [5, 11].

International Guidelines and Size-Based Criteria (ENETS, NCCN)

Contemporary international guidelines (NANETS [6], ENETS [12], and NCCN [11]) now provide explicit recommendations based on tumor size and local invasion:

- **Low risk (generally < 1 cm):** The risk of metastatic dissemination in this category is minimal; accordingly, appendectomy alone is considered adequate.
- **Intermediate risk (1–2 cm):** Requires detailed pathomorphological assessment with evaluation of all three risk factors (Ki-67 index, depth of invasion, and lymphovascular invasion).
- **High risk (≥ 2 cm):** At this tumor dimension, the risk of regional lymph node metastasis is substantially ele-

vated [3]. Therefore, right hemicolectomy with lymph node dissection, aimed at guaranteeing R0 status, constitutes the gold standard of care [11, 12].

The Factor of Emergency Surgery: Inflammation and Neoplasia

Of particular significance are clinical scenarios analogous to the present case, in which ANETs manifest in the context of acute appendicitis or periappendiceal abscess. In circumstances where the visually estimated tumor dimension clearly exceeds 2 cm and is accompanied by regional lymphadenopathy [9], the prevailing consensus within the oncological community favors single-stage radical resection [10]. This pragmatic approach aims to prevent residual neoplastic disease (R1/R2) and to ensure optimal oncological outcomes for the patient.

CASE REPORT

Diagnostic Findings and Clinical Presentation

Patient: A 19-year-old male presenting with severe abdominal pain and elevated inflammatory markers (leukocytosis, WBC \uparrow).

Computed tomography (CT) of the abdomen demonstrated not only radiological signs consistent with acute appendicitis, but also an 81x42 mm heterogeneous mass in the periappendiceal region, accompanied by regional lymph node enlargement [9]. These findings were strongly indicative of a high probability of malignant neoplasia.

Operative Findings and Specimen Description

Intraoperative examination revealed a massive, indurated inflammatory infiltrate (approximately 8x6 cm), associated with a periappendiceal abscess and high suspicion of cecal wall invasion. Given the elevated oncological risk, the operating surgeon elected to proceed with a single-stage right hemicolectomy.

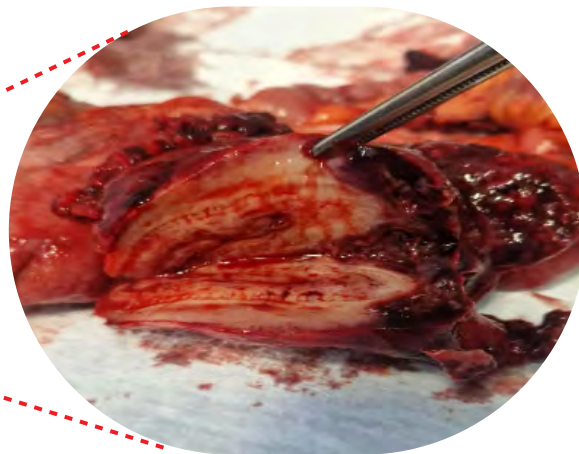
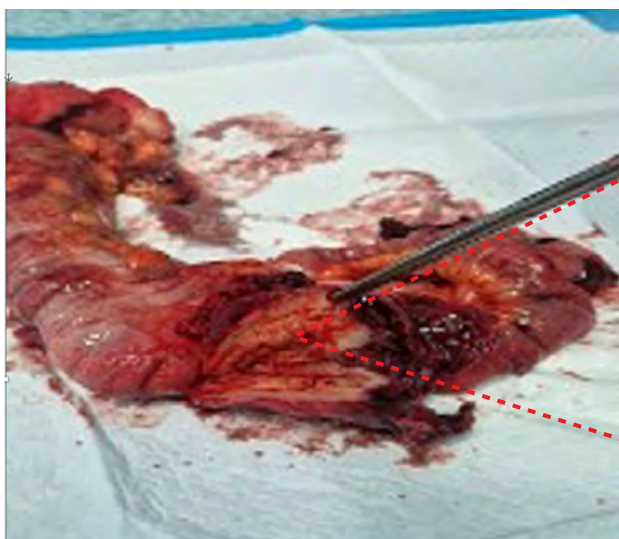


Figure 1-A

The resected specimen constituted a voluminous neoplastic mass. Figure 1A illustrates the gross appearance of the specimen (resected hemicolectomy specimen).

Pathomorphological Confirmation and Final Diagnosis

Pathomorphological examination confirmed the following:

- Carcinoid tumor (neuroendocrine neoplasm).
- Tumor invasion involving all layers of the cecal wall and the adjacent mesentery.
- Resection margins negative for neoplastic involvement (R0 status achieved).
- Figure 1B presents the gross pathological appearance of the specimen on cross-section (resected specimen on cross-section).

Postoperative Course and Outcome

The postoperative course was uneventful and complication-free. The patient was discharged with recommendations for scheduled outpatient oncological surveillance, given that complete (R0) oncological resection had been achieved [10].

DISCUSSION:

Legitimacy of the Surgical Decision from an Oncological Safety Perspective

The present case substantiates the validity of single-stage radical surgical intervention in the setting of intraoperative diagnostic uncertainty [10].

Primacy of R0 Resection in the Setting of Concurrent Infection

The tumor dimensions (≥ 2 cm) and cecal wall invasion indicated that appendectomy alone would have carried a near-certain risk of R1/R2 resection [7]. Achievement of

R0 resection — the benchmark of oncological success — was possible exclusively by means of hemicolectomy.

Ethical and Oncological Justification of the Surgical Approach

The prevailing oncological principle dictates that the risk of oncological inadequacy (R1/R2 residual disease) is substantially greater and considerably less acceptable than the risk of performing an extensive resection for what may prove to be a benign process [10].

CONCLUSION:

Recommendations and Management Algorithm

Practical recommendations:

1. **Single-stage radical resection:** When intraoperative findings unequivocally demonstrate high-risk features — such as a visually estimated tumor size ≥ 2 cm, cecal wall invasion, or regional lymphadenopathy — the surgeon should perform a right hemicolectomy as a single-stage procedure [3, 10, 11, 12].
2. **Two-stage cautious approach:** When risk factors are intermediate (tumor size 1–2 cm), and no overt signs of invasion are identified, appendectomy followed by definitive histopathological assessment is preferable. In the event of confirmed high-risk features (Ki-67 $\geq 3\%$ and R1 margins), completion hemicolectomy is indicated [5, 7, 12].

Conclusion:

In the management of ANETs, the operating surgeon should adhere to the principle: "An extended resection is preferable to an inadequate one" [10] — a dictum that ensures the patient's durable oncological safety and long-term disease control.

References:

1. Modlin, I. M., Lye, K. D., & Kidd, M. (2003). A 5-decade analysis of 13,715 carcinoid tumors. *Cancer*, 97(4), 934–959. <https://doi.org/10.1002/cncr.11105>
2. Groth, S. S., Virnig, B. A., Al-Refaie, W. B., Jarosek, S. L., Jensen, E. H., & Tuttle, T. M. (2010). Appendiceal carcinoid tumors: Predictors of nodal metastases and the impact of right hemicolectomy on survival. *Journal of Gastrointestinal Surgery*, 14(10), 1530–1536. <https://doi.org/10.1007/s11605-010-1321-7>
3. Hristov, B. D., Yeo, C. J., & Lavu, H. (2021). The management of large appendiceal neuroendocrine tumors: A national perspective on practice patterns. *American Journal of Surgery*, 221(4), 743–749. <https://doi.org/10.1016/j.amjsurg.2020.07.017>
4. Pampalana, F., Bencini, L., Farsi, M., & Scatizzi, M. (2018). Appendiceal neuroendocrine tumors: A review of current knowledge. *Journal of Surgical Oncology*, 117(2), 226–235. <https://doi.org/10.1002/jso.24855>
5. Pavel, M., Öberg, K., Falconi, M., Krenning, E. P., Sundin, A., Perren, A., & Berruti, A. (2020). Gastroenteropancreatic neuroendocrine neoplasms: ESMO clinical practice guidelines for diagnosis, treatment and follow-up. *Annals of Oncology*, 31(7), 844–860. <https://doi.org/10.1016/j.annonc.2020.03.304>
6. Strosberg, J. R., Halldanarson, T. R., Bellizzi, A. M., Chan, J. A., Dillon, J. S., Heaney, A. P., & Kunz, P. L. (2017). The North American Neuroendocrine Tumor Society consensus guidelines for the diagnosis and management of neuroendocrine tumors. *Pancreas*, 46(6), 707–714. <https://doi.org/10.1097/MPA.0000000000000846>
7. Landry, C. S., Woodall, C., Scoggins, C. R., McMasters, K. M., & Martin, R. C. (2011). The decision for completion right hemicol-

ectomy in appendiceal carcinoids. *American Surgeon*, 77(9), 1162–1165. <https://doi.org/10.1177/000313481107700930>

8. Syrigos, K. N., Zalonis, A., Kotteas, E., & Saif, M. W. (2007). Appendiceal carcinoid tumors: A review of the literature. *Anticancer Research*, 27(6B), 4377–4384.
9. Ciresa, M., Cortese, F., Quacia, E., Belgrano, M., Stacul, F., & Zuiani, C. (2020). Imaging of neuroendocrine tumors: Current practice and future perspectives. *Cancers*, 12(11), Article 3169. <https://doi.org/10.3390/cancers12113169>
10. Morris, A. M., Billingsley, K. G., Baxter, N. N., & Baldwin, L. M. (2012). Surgical decision making in appendiceal carcinoids: A population-based analysis. *Journal of the American College of Surgeons*, 215(3), 338–344. <https://doi.org/10.1016/j.jamcollsurg.2012.05.003>
11. National Comprehensive Cancer Network. (2024). *NCCN clinical practice guidelines in oncology: Neuroendocrine and adrenal tumors (Version 2.2024)*. <https://www.nccn.org/guidelines>
12. European Neuroendocrine Tumor Society. (2023). *ENETS consensus guidelines: Management of appendiceal neuroendocrine neoplasms*. <https://www.enets.org/guidelines>

აპენდიქსის კარცინოიდული სიმსივნე (ჭიანჭლავის ნეიროენდოკრინული სიმსივნე) მწვავე აპენდიციტის ფონზე: 19 წლის პაციენტის კლინიკური შემთხვევა

კახაბერ კიკვიძე, სერგო აბრამიანი, გია ჩუხუა, დავით ბუთხუზი, სოლომონ ქერაშვილი

ივ. ბოკერიას სახ. საუნივერსიტეტო ჰოსპიტალი, ზოგადი ქირურგიის და ტრანსპლანტალოგიის დეპარტამენტი

პასუხისმგებელი პირი: დავით ბუთხუზი, butxuzi@yahoo.com

DOI: <https://doi.org/10.48412/GTBGS.2026.14-15.51-54>

რეზიუმე შესავალი: აპენდიქსის ნეიროენდოკრინული სიმსივნეები (ANETs) იშვიათია და ხშირად მწვავე აპენდიციტის ფონზე ვლინდება [1]. 2 სმ-ზე მეტი ზომის წარმონაქმნები ონკოლოგიურად მაღალი რისკის შემცველია [3, 11]. გადაუდებელ სიტუაციებში ქირურგიის მოცულობის განსაზღვრა (R0 რეზექციის მიღწევა) რჩება რთულ კლინიკურ დილემად. **კლინიკური შემთხვევა:** წარმოგიდგინთ 19 წლის პაციენტის შემთხვევას, რომელსაც მწვავე აპენდიციტის ფონზე, კტ-ზე დაუფიქსირდა 81x42 მმ ზომის მასიური წარმონაქმნი ლიმფადენოპათიით. ინტრაოპერაციული მაღალი ონკოლოგიური ეჭვის საფუძველზე, ჩატარდა ერთეტაპიანი მარჯვენამხრივი ჰემიკოლექტომია. პათომორფოლოგიურმა პასუხმა დაადასტურა კარცინოიდი ცეკუმში ინვაზიით, მიღწეული იქნა R0 რეზექცია. **დასკვნა:** ჩვენი შემთხვევა ხაზს უსვამს იმას, რომ მაღალი რისკის ფაქტორების (ზომა ≥ 2 სმ, ინვაზიის ეჭვი) არსებობისას, ერთეტაპიანი რადიკალური ქირურგიული ჩარევა არის ლეგიტიმური და ეთიკურად გამართლებული რისკი [12].

საკვანძო სიტყვები: აპენდიქსის ნეიროენდოკრინული სიმსივნე, კარცინოიდი, მწვავე აპენდიციტი, ჰემიკოლექტომია, R0 რეზექცია, Ki-67.

EN BLOC TUMOR RESECTION AND ILIAC ARTERY RECONSTRUCTION USING ILIO-FEMORAL BYPASS IN A HEAVILY PRETREATED PATIENT WITH RECURRENT ENDOMETRIAL CANCER: A CASE REPORT

Shota Mebonia¹, George Jinchveladze¹, Guram Vardishvili¹, Ivane Kiladze^{2,3}, Sandro Tsikarishvili¹, Aleksandre Gelashvili¹

¹*Vascular and Endovascular Surgery Department, Caucasus Medical Center, Tbilisi, Georgia,*

²*Clinical Oncology Department, Caucasus Medical Center, Tbilisi, Georgia,*

³*Ilia State University Tbilisi, Georgia*

Contact person: Shota Mebonia, shotamebonia@gmail.com

DOI: <https://doi.org/10.48412/GTBGS.2026.14-15.55-58>

Rezume This case report presents a 61-year-old woman with a history of endometrial carcinoma, initially treated with hysterectomy and chemotherapy in 2021. In 2023, due to pelvic disease recurrence, she received chemoradiotherapy followed by two lines of systemic therapy for disease progression. In July 2024, further progression was identified, revealing a large retroperitoneal tumor encasing major vessels and directly invading the left external iliac artery. Radiological imaging showed no evidence of distant metastasis.

Following a multidisciplinary discussion, a surgical intervention was planned. The patient underwent an extensive tumor excision, which included resection of the retroperitoneal mass along with the external iliac artery, followed by arterial reconstruction using an ilio-femoral bypass procedure. Histopathological and immunohistochemical analysis confirmed a poorly differentiated carcinoma consistent with endometrial cancer, with metastasis to the retroperitoneal lymph nodes.

The patient tolerated the procedure well and was discharged in satisfactory condition following postoperative care. This case underscores the clinical complexity of managing recurrent endometrial carcinoma with retroperitoneal lymph node metastasis, illustrating that surgical excision can be a vital option when chemotherapy does not achieve sufficient disease control. It emphasizes the importance of precise surgical intervention, particularly for patients with locally advanced recurrent disease.

Key words: endometrial cancer, retroperitoneal tumor, iliac artery reconstruction, ilio-femoral bypass

INTRODUCTION

Endometrial cancer is the most common gynecologic malignancy in developed countries, with a significant proportion of cases being diagnosed at an early stage due to early symptomatology [1]. However, advanced-stage and recurrent endometrial carcinoma present a substantial therapeutic challenge, particularly when the disease metastasizes to atypical sites such as the retroperitoneal lymph nodes [2]. Retroperitoneal lymph node metastasis is a rare but aggressive manifestation of endometrial cancer, often associated with a poor prognosis and a limited response to conventional therapies, including chemotherapy and radiotherapy [3]. Metastasis of endometrial carcinoma to the retroperitoneum is an uncommon event, as endometrial cancer typically spreads via the pelvic and para-aortic lymphatic systems [4,5]. Once the disease reaches the retroperitoneal space, surgical management becomes increasingly complex due to the proximity of vital structures such as the iliac vessels, ureters, and bowel [6,7]. In these cases, the involvement of vascular surgeons becomes critical, as excision of the tumor often requires intricate vascular reconstruction [8]. Chemotherapy remains the first line of treatment for metastatic endometrial cancer, but its efficacy in cases with retroperitoneal lymph node involvement is limited [9,10].

This case report presents an intriguing example of a 61-year-old female who was diagnosed with progressive disease of endometrial cancer and was heavily pre-treated with initial surgery, chemoradiotherapy for disease recurrence, and several lines of chemotherapy for disease progression. After disease progression in retroperitoneal lymph nodes involving the left external iliac artery/vein, radical surgical excision was offered after MDT discussion. The patient underwent an extensive tumor excision, which included resection of the retroperitoneal mass along with the external iliac artery, followed by arterial reconstruction using an ilio-femoral bypass procedure. Remarkably, this approach yielded clinical improvements, resulting in a notable improvement in the patient's performance status and overall quality of life.

CASE PRESENTATION

We present a case of a heavily pretreated patient with recurrent endometrial cancer. The patient is a 61-year-old woman with a history of moderately differentiated adenocarcinoma of the endometrium (GRADE-2), for which she underwent a hysterectomy with appendages in 2021. In 2023, due to pelvic disease recurrence, she received chemoradiotherapy followed by two lines of systemic therapy for disease progression. In July 2024, further pro-

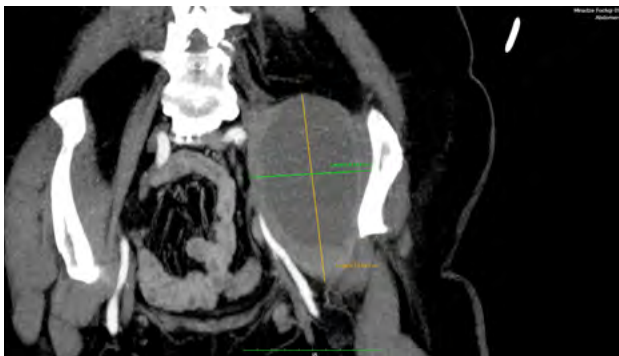

Figure 1. A large retroperitoneal tumor (CT coronal view)

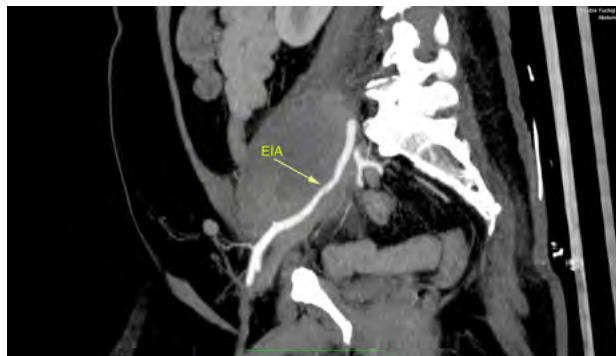

Figure 2. Retroperitoneal tumor associated with left external iliac artery (CT sagittal view)

gression was identified. She presented to our clinic with complaints of severe pain in the left lower quadrant of the abdomen and the left groin area. The patient also has a history of type 2 diabetes mellitus, diagnosed in 2010, which remains unmanaged.

On physical examination, the patient appeared with excessively developed subcutaneous fat. She was alert, oriented, and cooperative. Her vital signs were within normal limits (T: 36.3°C, P: 88 bpm, BP: 125/80 mmHg). The abdomen was soft but tender upon palpation in the left lower quadrant. There were no signs of peritoneal irritation. Cardiovascular and respiratory system examinations were unremarkable.

A CT scan of the abdomen with contrast, performed in July 2024, revealed a large retroperitoneal tumor closely associated with the left external iliac artery (Figure 1). The tumor was suspected to involve surrounding structures, including the iliac vein, artery, and ureter (Figure 2).

Despite chemotherapy to control the progression of the disease, a multidisciplinary decision was made to proceed with surgical intervention. The patient was scheduled

for tumor excision and ilio-femoral bypass due to the involvement of critical vascular structures. image.jpeg

Histopathological Examination showed a poorly differentiated carcinoma of the retroperitoneal area involving soft tissue specimens and lymph nodes. Immunohistochemical Examination showed that the phenotypic and morphological changes in the tumor are most consistent with endometrioid-type carcinoma.

Surgical Intervention

In August 2024, the patient underwent a complex surgical procedure involving the excision of the retroperitoneal tumor and ilio-femoral bypass. The surgical approach included an incision from the left pubic symphysis to the rib cage, opening the retroperitoneal space. The tumor was found to be invading the iliac vein and artery, as well as closely adhering to the ureter and iliac bone (Figure 3). Following the excision of the tumor, ilio-femoral bypass was performed using a Dacron Graft 8 mm (Figure 4). Postoperatively, the patient was managed with antibiotics, anticoagulants, crystalloids, and erythrocyte mass transfusions. image.jpegimage.jpeg

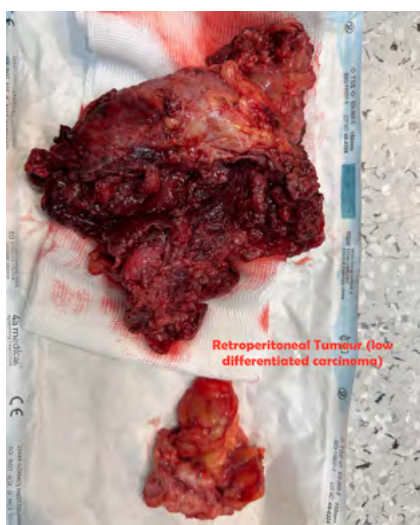


Figure 3. A poorly differentiated carcinoma of the retroperitoneal area

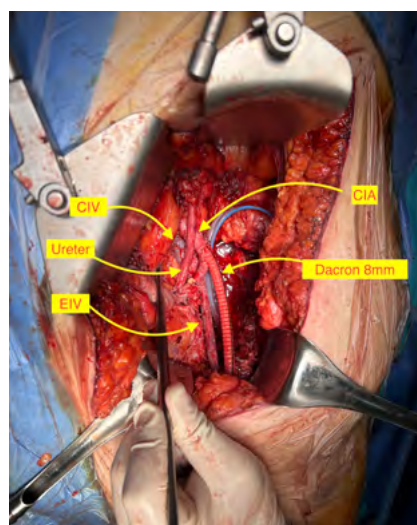


Figure 4. Ilio-Femoral shunt (Dacron graft 8mm)

OUTCOME AND FOLLOW-UP

After ten days of hospital care, during which her condition remained stable, she was discharged in satisfactory condition. Follow-up plans include regular imaging and consultations with oncology and vascular surgery teams to monitor for any signs of recurrence or complications.

DISCUSSION

Retroperitoneal cancers, particularly those that recur after initial treatment, present significant challenges in terms of surgical management and prognosis.

As vascular surgeons, our role in the management of such cases is paramount. This patient's tumor was not only located in the retroperitoneum but also encased the iliac vessels, necessitating ilio-femoral bypass following tumor excision [11,12]. The technical challenges associated with this type of surgery cannot be overstated, as the tumor's proximity to major vessels significantly increases the risk of intraoperative complications [13,14]. In recent literature, surgical resection combined with vascular reconstruction has been shown to improve local control and, in some cases, extend survival in patients with retroperitoneal metastasis of endometrial cancer [15,16]. This approach, while not curative, can provide symptomatic relief, prevent further vascular compression, and enhance the quality of life [17]. This case highlights the necessity of a multidisciplinary approach to recurrent endometrial carcinoma, where oncologists, gynecologists, and vascular surgeons collaborate to provide optimal care [18]. Surgical resection remains the definitive option regardless of chemotherapy, especially in the presence of vascular involvement [19]. By excising the tumor and performing ilio-femoral shunting, the goal was to reduce the tumor burden and prevent complications related to vascular compression [20,21].

This case exemplifies the difficulties in managing such tumors because of their proximity to vital structures such as blood vessels, nerves, and organs. The patient's history of endometrial adenocarcinoma with subsequent metastatic spread underscores the importance of vigilant follow-up and early intervention in cases of suspected recurrence. The decision to perform ilio-femoral shunting was led by the tumor's involvement with the iliac artery, demonstrating the need for advanced surgical techniques in managing complex retroperitoneal tumors. The patient's successful recovery post-surgery, despite her history of uncontrolled diabetes and previous chemotherapy, highlights the importance of a multidisciplinary approach in managing such cases. This case also raises important considerations for the prognosis of patients with recurrent retroperitoneal tumors. The involvement of the iliac vessels and close proximity to other critical structures suggest a guarded prognosis, with careful monitoring required to detect any signs of further recurrence or metastasis.

CONCLUSION

This case report illustrates the complexities of managing recurrent retroperitoneal cancer, particularly when the tumor involves critical structures like the iliac artery and vein. Surgical intervention, combined with comprehensive postoperative care, can lead to successful outcomes even in challenging cases. However, the risk of recurrence remains significant, necessitating ongoing follow-up and a multidisciplinary approach to care.

ACKNOWLEDGEMENTS

We would like to thank the whole staff involved in the treatment of this patient.

References:

1. Siegel, R. L., Miller, K. D., & Jemal, A. (2020). *Cancer statistics, 2020*. CA: A Cancer Journal for Clinicians, 70(1), 7–30.
2. Morice, P., Leary, A., Creutzberg, C., Abu-Rustum, N., & Darai, E. (2016). *Endometrial cancer*. Lancet, 387(10023), 1094–1108.
3. Clement, P. B., & Young, R. H. (2002). *Endometrioid carcinoma of the uterine corpus: A review of its pathology with emphasis on recent advances and problematic aspects*. Advances in Anatomic Pathology, 9(3), 145–184.
4. Bendifallah, S., Koskas, M., Ballester, M., Genin, A. S., Darai, E., & Rouzier, R. (2012). *Para-aortic lymphadenectomy in node-positive endometrial cancer: Time to reevaluate?* Gynecologic Oncology, 126(3), 414–418.
5. Matias-Guiu, X., & Prat, J. (2013). *Molecular pathology of endometrial carcinoma*. Histopathology, 62(1), 111–123.
6. Abeler, V. M., & Kjørstad, K. E. (1991). *Endometrial adenocarcinoma in Norway: A histopathological and prognostic survey of a total population*. International Journal of Gynecological Cancer, 1(1), 9–21.
7. Shah, C., Vicus, D., Bernardini, M. Q., Kurman, M. S., Mallick, R., & Lheureux, S. (2017). *Endometrial carcinoma metastatic to retroperitoneal lymph nodes: Patterns of failure and impact on survival*. International Journal of Gynecological Cancer, 27(5), 902–908.
8. Walker, J. L., Piedmonte, M. R., Spirtos, N. M., Eisenkop, S. M., Schlaerth, J. B., Mannel, R. S., Spiegel, G., Barakat, R., Pearl, M. L., & Sharma, S. K. (2012). *Recurrence and survival after random assignment to laparoscopy versus laparotomy for comprehensive surgical staging of uterine cancer: Gynecologic Oncology Group LAP2 Study*. Journal of Clinical Oncology, 30(7), 695–700.
9. Miller, D. S., Filiaci, V. L., Mannel, R. S., Cohn, D. E., Matsumoto, T., Tewari, K. S., DiSilvestro, P., Pearl, M. L., Argenta, P. A., Powell, M. A., Zweigig, S. L., Thaker, P. H., Warshal, D. P., Jelovac, D., O'Malley, D. M., McCourt, C., Birrer, M. J., & Secord, A. A. (2020). *Carboplatin and paclitaxel for advanced endometrial cancer: Final overall survival and adverse event analysis of a phase III trial*. Journal of Clinical Oncology, 38(33), 3841–3850.
10. de Haydu, C., Black, J. D., Schwab, C. L., English, D. P., & Santin, A. D. (2016). *An update on the current pharmacotherapy for endometrial cancer*. Expert Opinion on Pharmacotherapy, 17(4), 489–499.
11. Tewari, K. S., Monk, B. J., Vergote, I., Miller, A., de Melo, A. C., Kim, H. S., Kim, Y. M., Lisianskaya, A., Samouelian, V., Lorusso,

D., Colombo, N., Park, S. Y., Hoskins, P., Mirza, M. R., Castonguay, V., Pépin, K., Mariani, A., & Fleming, G. F. (2013). Chemo-sensitivity to first-line platinum-based chemotherapy in advanced or recurrent endometrial cancer: A Gynecologic Cancer Intergroup study. *Gynecologic Oncology*, 130(2), 207–214.

12. Randall, M. E., Filiaci, V. L., McMeekin, D. S., von Gruenigen, V., Huang, H., Yashar, C. M., Mannel, R. S., Kim, J. W., Salani, R., DiSilvestro, P. A., Burke, J. J., Rutherford, T. J., Spirto, N. M., Tewari, K. S., Mariani, A., Mayadev, J. S., Shafer, A., Geller, M. A., Nsih-Asare, A., & Rossi, E. C. (2019). Phase III trial: Adjuvant pelvic radiation therapy versus vaginal brachytherapy plus paclitaxel/carboplatin in high-intermediate and high-risk early-stage endometrial cancer. *Journal of Clinical Oncology*, 37(21), 1810–1818.

13. Kitchener, H., Swart, A. M., Qian, Q., Amos, C., & Parmar, M. K. (2009). Efficacy of systematic pelvic lymphadenectomy in endometrial cancer (MRC ASTEC trial): A randomised study. *Lancet*, 373(9658), 125–136.

14. Fader, A. N., Santin, A. D., Zahurak, M. L., Diaz-Montes, T. P., Levinson, K. L., & Bristow, R. E. (2009). Outcomes of retroperitoneal lymphadenectomy in patients with recurrent endometrial cancer. *Gynecologic Oncology*, 113(1), 50–55.

15. Gunderson, C. C., Moxley, K. M., Broadwater, G., Lurain, J. R., Havrilesky, L. J., & Soper, J. T. (2014). Endometrial cancer: Recurrences outside the radiation field. *Gynecologic Oncology*, 134(3), 452–457.

16. Goff, B. A., Kato, D., & Schmidt, R. A. (2007). Surgical management of recurrent endometrial carcinoma with retroperitoneal lymph node involvement: Techniques and outcomes. *Gynecologic Oncology*, 105(2), 582–587.

17. Rose, P. G., Ali, S., Watkins, E., Thigpen, J. T., Deppe, G., Clarke-Pearson, D. L., & Insalaco, S. (2017). Long-term follow-up of a randomized trial comparing chemoradiation to chemotherapy as adjuvant treatment for high-risk endometrial carcinoma. *Gynecologic Oncology*, 144(2), 200–203.

18. Takemura, A., Osuga, Y., Fujiwara, T., Oi, N., Tsuji, S., Taketani, Y., & Harada, M. (2018). Management of lymph node metastases in endometrial cancer: The role of surgical staging and adjuvant therapy. *Journal of Gynecologic Oncology*, 29(5), Article e93.

19. Giovannini, M., Bricou, A., Marret, H., Ouldamer, L., Body, G., & Lacoste, P. (2013). Surgical management of recurrent endometrial cancer with retroperitoneal lymph node metastasis. *Surgical Oncology*, 22(2), e51–e56.

20. Takahashi, T., Kido, A., Minamiguchi, S., Fujimoto, K., Tanaka, S., Nakamoto, Y., & Togashi, K. (2020). Metastatic pattern of endometrial cancer: How can we identify intractable cases early? *Cancer Imaging*, 20(1), Article 22.

21. Erkan, M., Kleeff, J., Esposito, I., Giese, T., Ketterer, K., Buchler, M. W., Giese, N. A., & Friess, H. (2005). Pancreatic ductal adenocarcinoma: A ductal cancer with a significant propensity for retroperitoneal invasion. *Annals of Surgical Oncology*, 12(5), 359–366.

რეტროპერიტონეალური სიმსივნის ამოკვეთა ერთ ბლოკში და სისხლძარღვოვანი რეკონსტრუქცია თეძო-ბარძაყის არტერიების შუნტირებით ენდომეტრიუმის სიმსივნის რეციდივის შემთხვევაში: შემთხვევის აღწერა

შოთა მეზონია¹, გიორგი ჯინჭველაძე¹, გურამ ვარდიამილი¹, ივანე კილაძე^{2,3}, სანდრო წიქარიშვილი¹, ალექსანდრე გელაშვილი¹

¹ვასკულური და ენდოვასკულური ქირურგიის დეპარტამენტი, კავკასიის მედიცინის ცენტრი;

²კლინიკური ონკოლოგიის დეპარტამენტი, კავკასიის მედიცინის ცენტრი;

³ილიას სახელმწიფო უნივერსიტეტი

პასუხისმგებელი პირი: შოთა მეზონია, shotamebonia@gmail.com

DOI: <https://doi.org/10.48412/GTBGS.2026.14-15.55-58>

რეზიუმე | მოხსენება შეეხება 61 წლის ქალს, რომელთანაც დიაგნოსტირებული იყო ენდომეტრიული კარცინომა. ჩაუტარდა ოპერაციული მკურნალობა (ჰისტერექტომია) და ქიმიოთერაპია 2021 წელს. აღნიშნული დაავადების პროგრესირების გამო 2023 წელს ჩაუტარდა დამატებითი ქიმიო და სხივური თერაპიები. 2024 წლის ივლისში კვლავ გამოვლინდა აღნიშნული დაავადების პროგრესირება. ჩატარებული კლინიკური კვლევებით დადგინდა დიდი ზომის რეტროპერიტონეალური სიმსივნე, რომელიც გარს ეკვროდა და ინვაზირებდა მარცხენა თეძოს გარეთა არტერიას. რადიოლოგიური კვლევებით დაავადების გავრცელების სხვა სარწმუნო ნიშნები ნანახი არ იქნა. პაციენტი განხილულ იქნა მულტიდისპლინური ბორდის მიერ, სადაც გადაწყდა და დაიგეგმა ქირურგიული მკურნალობა. პაციენტს ჩაუტარდა რეტროპერიტონეალური სიმსივნის ამოკვეთა გარეთა თეძოს არტერიასთან ერთად ერთ ბლოკში და სისხლძარღვოვანი რეკონსტრუქცია (მარცხენა თეძო და ბარძაყის არტერიების შუნტირება). იმუნიჰისტოქიმიურმა და პოსტოპათოლოგიურმა კვლევებმა დაადასტურა დაბალდიფერენცირებული კარცინომა, რომელიც შედგებოდა ენდომეტრიული სიმსივნური ქსოვილებისგან, ასევე დაავადების გავრცელება რეტროპერიტონეალურ ლიფურ კვანძებში. პოსტოპერაციულ პერიოდში დინამიკა დადებითი. გაწერა კლინიკიდან დამაკმაყოფილებელი მდგომარეობით. აღნიშნული შემთხვევა ხაზს უსვამს რეტროპერიტონეალური ლიმფური კვანძების მეტასტაზით მიმდინარე რეციდიული ენდომეტრიუმის კარცინომის მართვის კლინიკურ სირთულეს, რაც აჩვენებს, რომ ქირურგიული მკურნალობა უალტერნატივოა, როდესაც ქიმიოთერაპია ვერ აღწევს სასურველ შედეგს. მოხსენება ხაზს უსვამს ზუსტი ქირურგიული მკურნალობის მნიშვნელობაზე, განსაკუთრებით ადგილობრივად გავრცელებული რეციდიული დაავადების მქონე პაციენტებისთვის.

საკვანძო სიტყვები: ენდომეტრიული კარცინომა, რეტროპერიტონეალური სიმსივნე, თეძოს არტერიის რეკონსტრუქცია, თეძო-ბარძაყის არტერიების შუნტირება.

THE IMPACT OF COMPUTER-ASSISTED NAVIGATED TOTAL KNEE ARTHROPLASTY ON OPERATIVE TIME

George Tchumburidze¹, Lukhum Tchanturia², Irakli Gogokhia³

¹Ivane Bokeria University Hospital, ²Newhospitals, ³Aleksandre Aladashvili Clinic (Tbilisi, Georgia)

Contact person: George Tchumburidze, dr.tchumburidze@yahoo.de

DOI: <https://doi.org/10.48412/GTBGS.2026.14-15.59-63>

Resume | **Background:** The knee joint, due to its anatomy, biomechanics, and function, represents a highly complex mechanical system. In recent years, the implantation of artificial knee joints has increased significantly worldwide as a means of reducing pain and improving mobility. Although total knee arthroplasty is currently the most commonly used treatment for advanced-stage gonarthrosis, the high effectiveness of surgical treatment, functional restoration of mobility, and predictability of outcomes remain ongoing challenges.

Objectives: The aim of this study was to identify the advantages of computer-assisted surgical navigation in the treatment of gonarthrosis and to evaluate its impact on operative time.

Methods: A total of 100 patients who underwent primary total knee arthroplasty between 2020 and 2024 were included in the study (cruciate-retaining, mobile-bearing implants). All procedures were performed using a tibially fixed polyethylene insert with preservation of the posterior cruciate ligament (Aesculap). Patients were divided into two main groups: the N-group, who underwent computer-assisted navigated total knee arthroplasty with patellar resurfacing (OrthoPilot®, B. Braun Aesculap), and the S-group, who underwent total knee arthroplasty with patellar resurfacing using the standard conventional technique. The total operative time for both standard and navigation-assisted procedures was recorded and documented for statistical analysis, measured from skin incision to wound closure.

Results: No statistically significant differences were observed between the groups with respect to age or sex. In patients who underwent computer-assisted surgery, the mean operative time (M = 68.50; SD = 8.29 minutes) was significantly shorter compared with patients treated using the standard technique (M = 80.58; SD = 10.47 minutes).

Conclusions: On average, the navigation-assisted group required approximately 12 minutes less operative time than the group treated with the standard methodology.

Key words: Gonarthrosis; Navigation in knee endoprosthesis implantation; OrthoPilot; Total knee arthroplasty.

INTRODUCTION:

It should be noted that in patients over 60 years of age, approximately 90% of cases of gonarthrosis ultimately result in total knee arthroplasty. Consequently, this condition represents not only a medical but also a significant social problem. Although total knee arthroplasty is currently the most widely used treatment for advanced-stage gonarthrosis, the high effectiveness of surgical treatment, full functional restoration of mobility, and reliable predictability of outcomes remain relevant challenges.

Despite the availability of modern, well-established techniques and high-quality implants produced by leading medical technology companies worldwide, consistently high clinical outcomes are not always achieved. This is reflected in the relatively high incidence of postoperative complications, including early implant loosening, dislocation, persistent pain, severe limitation of mobility, prolonged rehabilitation, and infectious or other inflammatory processes associated with implant instability. Many authors associate early loosening of knee endoprostheses primarily with infection. Since prolonged operative time increases the risk of both infectious and other postoperative complications, optimizing surgical duration is crucial.

The concept of computer-assisted navigation systems was developed in response to the problems associated with knee arthroplasty described in the international medical and scientific literature. This approach is based on establishing a relationship between highly accurate, anatomically precise implant positioning and the quality of postoperative biomechanical joint restoration, which ultimately has a significant impact on implant longevity. Navigation systems such as OrthoPilot allow not only the precise determination of bone resection planes tailored to the individual patient but also the assessment of ligamentous tension and the selection of the appropriate implant size [5,6,22].

Why is it so important for a knee endoprosthesis to closely match the patient's individual anatomy? The knee joint is a complex structure with unique, patient-specific biomechanics. Applying a standardized anatomical approach to all patients and performing arthroplasty accordingly neglects individual anatomical variability. This may alter the joint's natural range of motion and affect surrounding structures, including patellar positioning, ligament tension, and overall joint stability. This also explains why up to 20% of patients report dissatisfaction after conventional total knee arthroplasty [2,3].

Since navigation-assisted knee arthroplasty is a relatively recent technique and requires additional specialized training, its widespread implementation on a global scale has not yet been achieved [4]. As a result, studies evaluating outcomes of computer-assisted knee arthroplasty and related scientific publications remain limited. Most available publications in the international literature focus primarily on postoperative radiological outcomes of navigated knee arthroplasty [7]. However, equally important are analyses of clinical outcomes, operative and rehabilitation time, postoperative biomechanical characteristics of the knee joint, and pain intensity.

Among the reported disadvantages, J.M. Strauss and W. R  ther emphasized that navigation-assisted procedures are more time-consuming, increasing operative time by an average of 19 minutes. Nevertheless, recent advances in surgical techniques and improved familiarity with navigation system functionality have significantly optimized the procedure.

The aim of the present study is to demonstrate, using statistical analysis, that under modern conditions an experienced surgical team requires the same, or even less, operative time when performing navigation-assisted total knee arthroplasty as with the standard conventional technique.

METHODS

The study included patients who underwent primary total knee arthroplasty between 2020 and 2024 using mobile-bearing implants with patellar resurfacing. All procedures were performed using a tibially fixed polyethylene insert with preservation of the posterior cruciate ligament (Aesculap). Patients with stage III–IV gonarthrosis according to the Kellgren–Lawrence classification were selected for the study.

Patients were divided into two main groups:

N group: patients who underwent computer-assisted navigation total knee arthroplasty with patellar resurfacing (OrthoPilot®, B. Braun Aesculap).

S group: patients who underwent total knee arthroplasty with patellar resurfacing using the standard conventional technique.

Age groups were defined as follows:

Group I: 50–65 years

Group II: 66–80 years

Gender distribution was categorized as male (M) and female (F).

The study included 100 patients (50 females and 50 males) who underwent primary total knee arthroplasty with patellar resurfacing between 2020 and 2024. Of these, 50 patients were assigned to the N group (25 females, 25 males) and 50 patients to the S group (25 females, 25 males).

RESULTS:

No statistically significant differences in outcomes were observed by age or sex. Overall, among the 100 patients, the mean operative time was approximately 74 minutes (M = 74.54; SD = 11.18) (Table 1).

DISCUSSION

It should be noted that in patients who underwent surgery with computer-assisted navigation, the mean operative time (M = 68.50; SD = 8.29) was significantly shorter than in patients who underwent surgery with the standard conventional technique (M = 80.58; SD = 10.47) (Table 2).

CONCLUSIONS:

In the computer-assisted surgery group, the mean operative time was reduced by approximately 12 minutes compared with the standard technique group. This difference was statistically significant ($t(98) = 6.39; p < .05$). In addition, it is noteworthy that the standard deviation of the mean operative time was lower in the computer-assisted group than in the standard surgery group, indicating that operative duration in navigation-assisted procedures was more consistent and homogeneous.

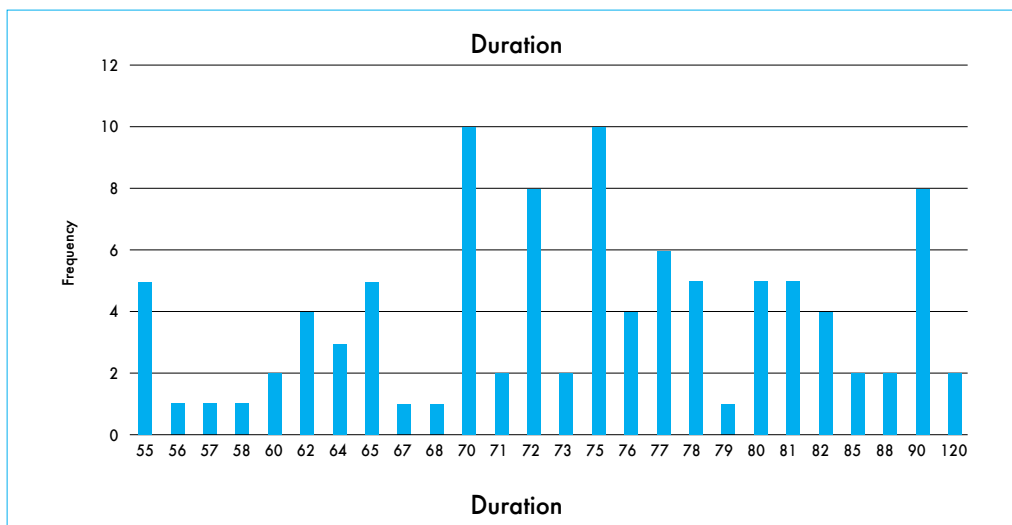


Chart 1. Duration - 1

Table 1. Operation time

PATIENT	OPERATION TIME	OPERATION TIME
	50 Patients who underwent Computer-assisted TKA with patellar resurfacing using a navigation system	50 Patients who underwent Standard (non-navigated) TKA with patellar resurfacing
NR.1	72 MIN	90 MIN
NR.2	77 MIN	82 MIN
NR.3	55 MIN	85 MIN
NR.4	90 MIN	120 MIN
NR.5	62 MIN	85 MIN
NR.6	70 MIN	70 MIN
NR.7	76 MIN	78 MIN
NR.8	64 MIN	90 MIN
NR.9	55 MIN	72 MIN
NR.10	76 MIN	82 MIN
NR.11	65 MIN	88 MIN
NR.12	73 MIN	90 MIN
NR.13	80 MIN	81 MIN
NR.14	75 MIN	70 MIN
NR.15	78 MIN	90 MIN
NR.16	72 MIN	90 MIN
NR.17	65 MIN	72 MIN
NR.18	75 MIN	81 MIN
NR.19	55 MIN	72 MIN
NR.20	56 MIN	80 MIN
NR.21	68 MIN	82 MIN
NR.22	76 MIN	78 MIN
NR.23	64 MIN	72 MIN
NR.24	75 MIN	81 MIN
NR.25	65 MIN	70 MIN
NR.26	60 MIN	90 MIN
NR.27	62 MIN	120 MIN
NR.28	55 MIN	75 MIN
NR.29	78 MIN	70 MIN
NR.30	77 MIN	80 MIN
NR.31	57 MIN	70 MIN
NR.32	58 MIN	75 MIN
NR.33	62 MIN	77 MIN
NR.34	77 MIN	81 MIN
NR.35	62 MIN	77 MIN
NR.36	75 MIN	72 MIN
NR.37	70 MIN	70 MIN
NR.38	76 MIN	75 MIN
NR.39	55 MIN	71 MIN
NR.40	73 MIN	80 MIN
NR.41	75 MIN	81 MIN
NR.42	67 MIN	88 MIN
NR.43	60 MIN	72 MIN
NR.44	65 MIN	82 MIN
NR.45	70 MIN	90 MIN
NR.46	75 MIN	80 MIN
NR.47	65 MIN	78 MIN
NR.48	64 MIN	70 MIN
NR.49	77 MIN	79 MIN
NR.50	71 MIN	75 MIN

Table 2. Group Statistics

	Group	N	Mean	Std. Deviation	Std. Error Mean
Duration	N	50	68.5000	8.29125	1.17256
	S	50	80.5800	10.47658	1.48161

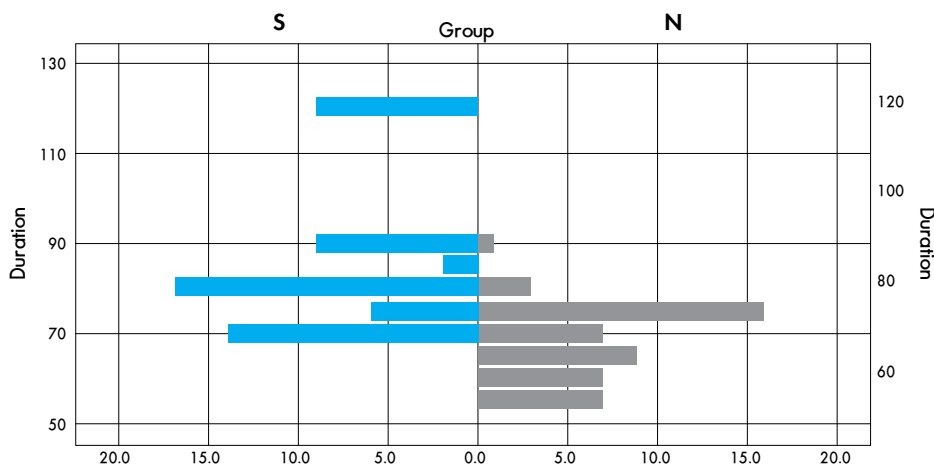


Chart 2. Duration - 2

Preferences:

- Alvarez, P. M., McKeon, J. F., Spitzer, A. I., Krueger, C. A., Pigott, M., Li, M., et al. (2022). Socioeconomic factors affecting outcomes in total knee and hip arthroplasty: a systematic review on healthcare disparities. *Art Ther*, 4, 36.
- Batailler, C., Swan, J., Sappey Marinier, E., Servien, E., & Lustig, S. (2020). New technologies in knee arthroplasty: current concepts. *J Clin Med*, 10, 47.
- Cantivalli, A., Cottino, U., Bonasia, D. E., Rosso, F., & Rossi, R. (2023). Robotic systems in knee surgery: current concepts and future perspectives. *Prosthesis*, 5, 1257–1274.
- Christen, B., Tanner, L., Ettinger, M., Bonnin, M. P., Koch, P. P., & Calliess, T. (2022). Comparative cost analysis of four different computer-assisted technologies to implant a total knee arthroplasty over conventional instrumentation. *J Pers Med*, 12, 184.
- Cozzi Lepri, A., Innocenti, M., Matassi, F., Villano, M., Civinini, R., & Innocenti, M. (2019). Accelerometer-based navigation in total knee arthroplasty for the management of extra-articular deformity and retained femoral hardware: analysis of component alignment. *Joints*, 7, 1–7.
- Deep, K., Shankar, S., & Mahendra, A. (2017). Computer assisted navigation in total knee and hip arthroplasty. *Sicot J*, 3, 50.
- Dong, Z., Li, Y., & Tian, H. (2021). Research progress on comparison of the application effects between personal specific instrumentation and computer-assisted navigation surgery in total knee arthroplasty. *Zhongguo Xiu Fu Chong Jian Wai Ke Za Zhi*, 35, 1492–1498.
- Figuerola, F., Parker, D., Fritsch, B., & Oussedik, S. (2018). New and evolving technologies for knee arthroplasty—computer navigation and robotics: state of the art. *J ISAKOS*, 3, 46–54.
- Gong, S., Xu, W., Wang, R., Wang, Z., Wang, B., Han, L., et al. (2019). Patient-specific instrumentation improved axial alignment of the femoral component, operative time and perioperative blood loss after total knee arthroplasty. *Knee Surg Sports Traumatol Arthrosc*, 27, 1083–1095.
- Gordon, A. C., Conditt, M. A., & Verstraete, M. A. (2021). Achieving a balanced knee in robotic TKA. *Sensors (Basel)*, 21, 535.
- Hariri, M., Hagemann, M., Mick, P., Deisenhofer, J., Panzram, B., Innmann, M., et al. (2023). Physical activity of young patients following minimally invasive lateral unicompartmental knee replacement. *J Clin Med*, 12, 635.
- Hill, D., Williamson, T., Lai, C. Y., Leary, M., & Brandt, M. (2020). Robots and tools for remodeling bone. *IEEE Rev Biomed Eng*, 13, 184–198.
- Hinloopen, J. H., Puijk, R., Nolte, P. A., Schoones, J. W., de Ridder, R., & Pijls, B. G. (2023). The efficacy and safety of patient-specific instrumentation in primary total knee replacement: a systematic review and meta-analysis. *Expert Rev Med Devices*, 20, 245–252.
- Marullo, M., Vitale, J. A., Stucovitz, E., & Romagnoli, S. (2019). Simultaneous bilateral unicompartmental knee replacement improves gait parameters in patients with bilateral knee osteoarthritis. *Knee*, 26, 1413–1420.
- Matassi, F., Cozzi Lepri, A., Innocenti, M., Zanna, L., Civinini, R., & Innocenti, M. (2019). Total knee arthroplasty in patients with extra-articular deformity: restoration of mechanical alignment using accelerometer-based navigation system. *J Arthroplasty*, 34, 676–681.
- Matsumoto, T., Nakano, N., Hayashi, S., Takayama, K., Maeda, T., Ishida, K., et al. (2023). Prosthetic orientation, limb alignment, and soft tissue balance with bi-cruciate stabilized total knee arthroplasty: a comparison between the handheld robot and conventional techniques. *Int Orthop*, 47, 1473–1480.

17. Nandi, M., Schreiber, K. L., Martel, M. O., Cornelius, M., Campbell, C. M., Haythornthwaite, J. A., et al. (2019). Sex differences in negative affect and postoperative pain in patients undergoing total knee arthroplasty. *Biol Sex Differ*, 10, 23.
18. Nisar, S., Palan, J., Riviere, C., Emerton, M., & Pandit, H. (2020). Kinematic alignment in total knee arthroplasty. *EFORT Open Rev*, 5, 380–390.
19. Odum, S. M., Fehring, T. K., & Knee Society Crosswalk Writing Group. (2017). Can original knee society scores be used to estimate new 2011 knee society scores? *Clin Orthop Relat Res*, 475, 160–167.
20. Pietsch, M., Hochegger, M., Djahani, O., Mlaker, G., Eder-Halbedl, M., & Hofstadter, T. (2021). Handheld computer-navigated constrained total knee arthroplasty for complex extra-articular deformities. *Arch Orthop Trauma Surg*, 141, 2245–2254.
21. Sculco, P. K., Kahlenberg, C. A., Fragomen, A. T., & Rozbruch, S. R. (2019). Management of extra-articular deformity in the setting of total knee arthroplasty. *J Am Acad Orthop Surg*, 27, e819–e830.
22. Shah, S. M. (2021). After 25 years of computer-navigated total knee arthroplasty, where do we stand today? *Art Ther*, 3, 41.
23. Shakya, P., & Poudel, S. (2022). Prehabilitation in patients before major surgery: a review article. *J Nepal Med Assoc*, 60, 909–915.
24. Shatrov, J., & Parker, D. (2020). Computer and robotic-assisted total knee arthroplasty: a review of outcomes. *J Exp Orthop*, 7, 70.
25. Shih, Y. C., Chau, M. M., Arendt, E. A., & Novacheck, T. F. (2020). Measuring lower extremity rotational alignment: a review of methods and case studies of clinical applications. *J Bone Joint Surg Am*, 102, 343–356.
26. Siddiqi, A., Horan, T., Molloy, R. M., Bloomfield, M. R., Patel, P. D., & Piuze, N. S. (2021). A clinical review of robotic navigation in total knee arthroplasty: historical systems to modern design. *EFORT Open Rev*, 6, 252–269.
27. Wan, R. C. W., Fan, J. C. H., Hung, Y. W., Kwok, K. B., Lo, C. K. M., & Chung, K. Y. (2021). Cost, safety, and rehabilitation of same-stage, bilateral total knee replacements compared to two-stage total knee replacements. *Knee Surg Relat Res*, 17.
28. Wang, B., Xing, D., Li, J. J., Zhu, Y., Dong, S., & Zhao, B. (2019). Lateral or medial approach for valgus knee in total knee arthroplasty - which one is better? A systematic review. *J Int Med Res*, 47, 5400–5413.
29. Weber, P., & Gollwitzer, H. (2021). Kinematic alignment in total knee arthroplasty. *Oper Orthop Traumatol*, 33, 525–537.

Sonnet 4.6 Claude is AI and can make mistakes. Please double-check responses.

მუხლის სახსრის კომპიუტერული ნავიგაციით ენდოპროთეზირების უპირატესობის გავლენა საოპერაციო დროის ფაქტორზე

გიორგი ჭუმბურიძე¹, ლუხუმ ჭანტურია², ირაკლი გოგონია³

¹ივანე ბოკერიას სახელობის საუნივერსიტეტო ჰოსპიტალი,
²ნიუჰოსპიტალისი, ³ალექსანდრე ალადაშვილის სახ. კლინიკა

პასუხისმგებელი პირი: გიორგი ჭუმბურიძე, dr.tchumburidze@yahoo.de

DOI: <https://doi.org/10.48412/GTBGS.2026.14-15.59-63>

რეზიუმე

მუხლის სახსარი თავისი ანატომიით, ბიომექანიკით და ფუნქციით წარმოადგენს საკმაოდ რთულ მექანიზმს. ტკივილის შემცირების და მოძრაობის გაუმჯობესების მიზნით, მუხლის ხელოვნური სახსრის იმპლანტაციამ, მსოფლიო მასშტაბით საგრძობლად იმატა ბოლო წლებში. მიუხედავად იმისა, რომ მაღალი სტადიის გონართროზის მკურნალობის ყველაზე გავრცელებული მეთოდი დღეისთვის არის ტოტალური ენდოპროთეზირება, ოპერაციული მკურნალობის მაღალი შედეგიანობა, გადაადგილების უნარის ფუნქციური სრულყოფა და გამოსავლის შედეგების პროგნოზირება კვლავ რჩება აქტუალურ პრობლემად. თანამედროვე მსოფლიო რეალობაში მოწოდებული და აპრობირებული მეთოდები, წამყვანი სამედიცინო ქვეყნების მიერ წარმოებული უმაღლესი ხარისხის იმპლანტების გამოყენებით, მაინც ვერ იძლევა ყოველთვის მაღალ შედეგს. ბევრი ავტორისთვის ენდოპროთეზის ადრეული მორყევა ძირითადად ინფექციასთან ასოცირდება. ვინაიდან, ოპერაციის ხანგრძლივი მსვლელობა ზრდის, როგორც ინფექციის, ასევე სხვა პოსტოპერაციული პათოლოგიების განვითარების რისკს, ოპერაციის დროის ოპტიმიზაციას მნიშვნელოვანი როლი ეკისრება. კომპიუტერით ასისტირებული სანავიგაციო სისტემის შექმნის იდეა დაკავშირებული იყო მსოფლიო სამედიცინო-სამეცნიერო ლიტერატურაში აღწერილი მუხლის სახსრის ენდოპროთეზირებასთან დაკავშირებული პრობლემების გადაჭრის გზების ძიებასთან. რასაც საფუძვლად ედო კავშირების დადგენა იმპლანტის სახსარში, მაღალი ანატომიური, ბუნებრივი სიზუსტით განთავსებასა და სახსრის პოსტოპერაციულ ბიომექანიკურ ფუნქციის ხარისხიანად აღდგენის პროცესს შორის. რაც საბოლოოდ მნიშვნელოვანწილად განსაზღვრავს ენდოპროთეზის ექსპლუატაციის ვადას. უარყოფითი მხარეებიდან, J.M. Strauss და W. Rütther თავის სტატიაში სახს უსვამენ, რომ ნავიგაციით ჩატარებული ოპერაცია უფრო ხანგრძლივია და საშუალოდ 19 წუთით ზრდის დროს. თუმცა, ბოლო პერიოდში ოპერაციული ტექნიკა დაიხვეწა, აგრეთვე კარგად ათვისებული იქნა სანავიგაციო კომპიუტერული აპარატის მუშაობის პრინციპები. კვლევის ამოცანა იყო, სანავიგაციო კომპიუტერული სისტემით, გონართროზის ქირურგიული მკურნალობის უპირატესობების დადგენა და მათი გავლენა საოპერაციო დროსთან მიმართებაში. ჩვენი ნაშრომის მიზანია, სტატისტიკურ მასალაზე დაყრდნობით, დაამტკიცოს, რომ თანამედროვე პირობებში, გამოცდილ საოპერაციო გუნდს იგივე ან უფრო ნაკლები დრო სჭირდება ოპერაციის ნავიგაციით მართვისას, ვიდრე სტანდარტული ენდოპროთეზირებისას.

საკვანძო სიტყვები: გონართროზი; მუხლის სახსრის ენდოპროთეზირების ნავიგაცია; ორთოპედიკი; მუხლის სახსრის ტოტალური ენდოპროთეზირება.

MULTIDISCIPLINARY MANAGEMENT OF AN OPEN DISTAL TIBIAL FRACTURE: A CASE REPORT

Nikoloz Avazashvili^{1,2}, Levan Chikvatia^{1,2}, Krupa Sara Thomas¹, Divina Mariya Puthooran¹

¹Tbilisi State Medical University, Department of Traumatology and Orthopaedics

²L.t.d. "Vian", Iv. Bokeria University Hospital, Department of Traumatology and Orthopaedics

Contact person: Sergo Kobalava, sergokobalava@gmail.com

DOI: <https://doi.org/10.48412/GTBGS.2026.14-15.64-68>

Rezume | Open fractures in orthopedic trauma present significant challenges due to the high risk of infection, non-union, and limb loss. This case report of a complicated Gustilo-Anderson Type IIIc high-energy trauma underscores the necessity for adaptable, evidence-based management protocols. It demonstrates that staged repair, prioritization of vascular status, early intervention, and the strategic use of external fixation contribute to improved outcomes in complex open fractures. A multidisciplinary approach, including early damage control, functional limb preservation, and adherence to BOA/BAPRAS guidelines, is essential for managing these injuries. Collaborative orthopedic-plastic management is a notable advancement that optimizes outcomes in high-energy limb trauma cases.

Key words: fracture, external fixation, osteosynthesis

INTRUCTION

An open fracture is a bone fracture where the broken bone and associated soft-tissue injuries are exposed to the external environment through a break in the skin. The energy involved in the injury directly correlates with trauma severity [1]. The Gustilo-Anderson classification (GAC), established as the standard in 1984, categorizes open fractures based on the extent of soft-tissue and skin damage [2]. Complications can include compartment syndrome (increased pressure within a muscle compartment), non-union (failure of bone healing), loss of function, neurovascular injury (damage to nerves or blood vessels), infection, osteomyelitis (bone infection), and amputation [1].

Understanding the epidemiology and mechanisms of open fractures is crucial for triage and treatment. Most are from traffic accidents; in patients under 65, tibial diaphysis fractures are most common. Gunshot wounds can cause complex bone and tissue injuries, sometimes exceeding those of high-velocity impacts. Since closure is not generally recommended, management must address the soft-tis-

sue defect. Despite research efforts, data on best practices remains limited.

This case report presents the management of a gunshot-induced, open fracture of the distal tibia and associated foot injury. The study highlights the surgical decision-making process, the role of external fixation, and additional fundamental concepts of open fracture care.

CASE PRESENTATION

A male patient presented to the emergency department (ED) 30 minutes after being wounded by a gunshot injury to his right leg. The bullet had entered the posteromedial aspect of the lower leg, resulting in a fracture of the lower third of the tibia with active bleeding. X-rays were performed in the emergency department, confirming the findings below (Figure 1). It was a comminuted open distal tibial fracture with significant bone loss and displacement. Multiple bone fragments and foreign bodies/ bullet fragments were seen in the surrounding soft tissues.

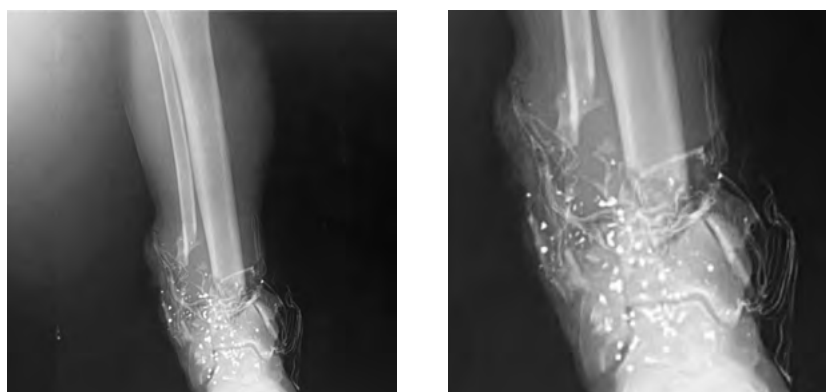


Figure 1. Preoperative plain radiographs. Anteroposterior (AP) view of the right lower leg/ankle

Initial Evaluation and Management

The Advanced Trauma Life Support (ATLS) protocol—a standardized approach for emergency care of trauma patients—should be immediately implemented at the scene or in the emergency room. Orthopedic evaluation and management should follow. On examination, the right leg showed extensive soft tissue injury and bone exposure. Emergency intraoperative findings confirmed damage to the arteria tibialis posterior (the posterior tibial artery), while the arteria dorsalis pedis (the dorsalis pedis artery) remained intact and became the foot's primary arterial blood supply. After administering a tetanus vaccine, the patient was taken to surgery for thorough irrigation (washing out the wound) and debridement (removal of damaged tissue). Given the extent of the bone defect, a 3-4 cm tibial shortening (surgically removing a bone segment to allow soft-tissue closure and alignment) was performed. Initial stabilization was achieved with external fixation (an ex-

ternal device that stabilizes the bone), as internal fixation (plates or rods placed inside the bone) is contraindicated when the wound is open and contaminated.

Postoperative Care and Plan

Postoperatively, the patient was placed on strict bed rest and started on broad-spectrum antibiotics. Vascular monitoring was performed routinely to assess perfusion via the remaining dorsalis pedis artery. The limb remained viable, though the vascular supply was tenuous due to the single-artery perfusion. Given the extensive bone loss and complexity of the injury, the orthopedic team recommended a 6-month observation period to monitor spontaneous bone regeneration and soft-tissue healing. If insufficient bone healing is observed, further interventions such as bone grafting and internal fixation will be considered at a later stage (Figure 2,3,4).

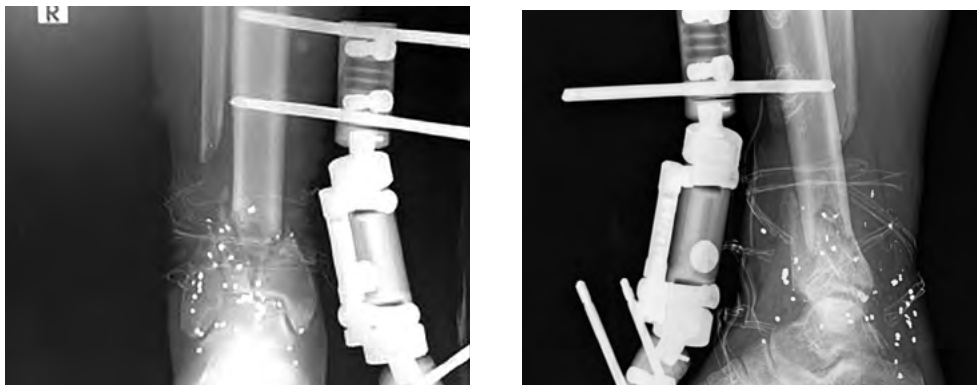


Figure 2. Postoperative plain radiographs. An external fixator was placed. 1 month post-op. Anteroposterior (AP) and Lateral views of the right lower leg/ankle (A and B)

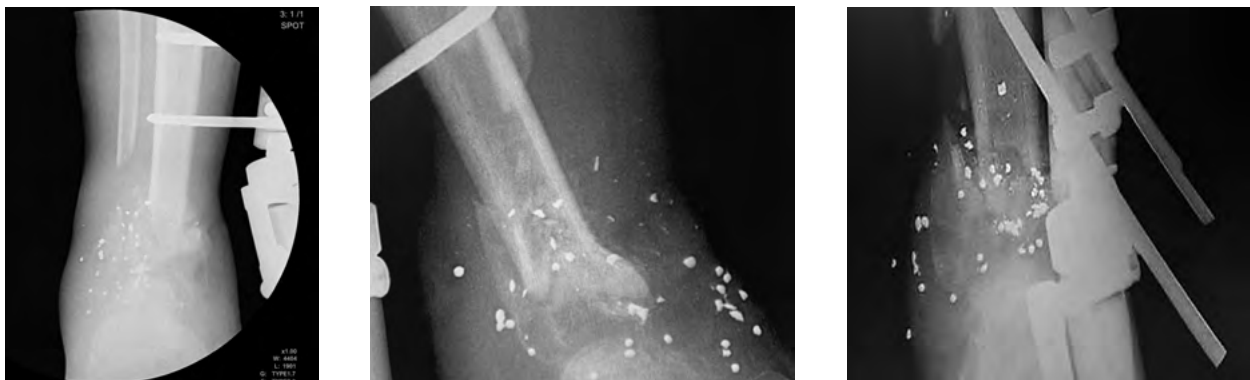

Figure 3. Postoperative plain radiographs. 2 months post-op. Anteroposterior (AP) and Lateral views of the right lower leg/ankle (A-C)




Figure 4. Postoperative plain radiographs. Latest post-op. Anteroposterior (AP) and Lateral views of the right lower leg/ankle(A-B)

DISCUSSION

Types of Open Fractures & Mechanisms

Open fractures may result from a variety of mechanisms of injury. Typical direct injuries include high-energy trauma such as car crashes, gunshot wounds, and high-impact falls. These injuries are frequently associated with varying degrees of contamination, soft-tissue compromise, and osseous involvement. High-velocity bullet-induced fractures have a known correlation with neurovascular injury due to the close proximity of vascular and neural structures to bone. According to Omer et al., approximately 69% of nerve injuries related to gunshot fractures demonstrate spontaneous recovery within three to nine months, while cases involving both arterial and nerve injury have a less favorable prognosis, often resulting in non-functional limbs. Visser et al. reported that only 7% of such combined injuries recover normal function.

In contrast, low-energy torsional injuries, including those from sports and falls from a standing height, are examples of indirect processes. However, there is a strong correlation between the amount of energy transferred at the time of damage and the severity of any open fracture [7].

Classification Systems

Gustilo and Anderson's classification system categorizes open fractures by severity and guides treatment. Type I fractures are clean wounds less than 1 cm long. Type II fractures are lacerations over 1 cm but without flaps, avulsions, or severe soft tissue damage. Type III fractures involve segmental bone injury with severe soft tissue damage or even amputation. For type I and II open fractures, primary wound closure is recommended, while for type III fractures, delayed primary closure is suggested, often using split-thickness skin grafts (transplanted skin layers) or suitable flaps (sections of tissue moved from another body part). The study found that more severe fracture types had worse prognoses and higher infection rates. Type IIIa fractures can be closed but have high contamination and soft tissue damage. Type IIIb fractures involve soft-tissue loss and require a tissue flap. Type IIIc fractures require vascular (blood vessel) repair due to arterial injury [10]. The present case is a Gustilo-Anderson type IIIc open fracture that required urgent surgery.

Treatment Principles

Effective management of open fractures requires understanding anatomy, injury mechanisms, the patient's physical state, and available surgical options. Treatment covers soft-tissue healing, reconstruction, final bone fixation, and initial wound cleaning (decontamination) [11].

Removing foreign objects within 6 hours during fracture reduction helps prevent infection. A wet-to-dry saline dressing after irrigation helps comfort and promote healing. Next, the limb should be reduced and put in a splint with padding. Pulses must be recorded both before and

after reduction. However, formal debridement is not required for a gunshot fracture unless the wound is large and contaminated. Tetanus prophylaxis is a standard procedure after open fractures, given the disease's severity and the low morbidity of treatment.

Antibiotics are essential for open wounds, as gram-positive bacteria are present in most cases, and gram-negative bacteria in some. Giving antibiotics within 60 minutes reduces infection-related postoperative complications.

Surgical stabilization (external fixation vs internal)

Effective surgical care lays the foundation for rehabilitation and a return to activities. Early fracture stabilization, especially for intra-articular fractures, enhances healing, reduces pain, eases bed transfers, and prevents further damage. Hemodynamic state, fracture site, and soft-tissue damage influence the treatment option chosen.

Depending on the degree of soft-tissue cover, it is assessed whether to perform definitive surgery with internal or external fixation of the fracture, as this is the biggest predictor of infection risk later. External and internal devices such as ring fixators, external fixators, and monolateral rails, as well as extramedullary devices, such as intramedullary nails or ORF with plates, are examples of fixation types [11]. When GHOISS is greater than 9, external fixators are crucial because they aid in skeletal stabilization, facilitate less-invasive procedures, and reduce soft-tissue damage in open fracture treatment. To enable soft-tissue repair, external fixator pins should be inserted through undamaged skin rather than through the incision. To prevent interference, they should not be positioned along the lines of future surgical incisions. To reduce the risk of fracture, skin incisions may be performed if the patient's hemodynamic status permits. The limb's length can be preserved by applying temporary external fixation, which can subsequently be changed to internal fixation. Although internal fixation is advised for subsequent reduction loss, open wounds with articular fractures present a possibility for articular reconstruction on day 1 [12].

If there is no significant soft tissue involvement or extensive contamination, and the patient is stable, primary internal fixation can be performed for open fractures with a GHOISS score of less than 9. The technique of choice is thorough debridement, with careful handling of the bone fragments to prevent devascularization [12].

Delayed vs primary closure.

The risk of nosocomial infection with gram-negative bacteria may increase with delayed wound closure. For wounds with significant tissue loss, Gopal et al. recommended early internal fracture fixation and flap covering [7]. In Type III injuries, Rajasekaran et al. reported outstanding results with a 3% deep infection rate following immediate primary skin closure, stringent inclusion and exclusion criteria, and tension-free closure after skeletal fixation. When the GHOISS skin score is 1 or 2, meaning there is no skin loss during debridement, and the overall score is less than 10, with no organic or sewage contam-

ination and no farmyard injuries, primary closure can be performed in type IIIb fractures [12].

Risks and Complications

The severity of the injury, the treatment method, and each patient's individual traits all affect the incidence of complications [13]. Open wounds, diabetes, and peripheral vascular disease were identified as risk factors according to a large population-based study. These complications can be perioperative, early postoperative, or late postoperative [14]. Delaying surgery for swollen ankles can reduce wound complications like infection, blistering, and edge necrosis, as posttraumatic edema, fracture blisters, or abrasions decrease. Nonunion development is facilitated by excessive motion at the fracture site, influenced by factors like infection, obesity, diabetes, tobacco use, alcohol misuse, and old age. Complex regional pain syndrome results in 30% of open tibial fractures. Loss of reduction and malunion can lead to osteoarthritis and functional impairment [11,14]

Role of Multidisciplinary Management

Management of open fractures requires a multidisciplinary team approach. Imaging the wound in the ED allows different specialties within the multidisciplinary team to further assess the wound, minimizing repeated exposure or contamination of the injury. In cases of open fractures, patients with severe injuries are now sent straight to major trauma units via pre-hospital pathways, which provide orthopedic and plastic surgery experts as well as on-site trauma subspecialties [12]. Open injuries require the joint efforts of orthopedic and plastic surgeons to coordinate the course of treatment and surgical procedures, ensuring the patient receives the most feasible and effective care. Orthopedic hospitals that have implemented this approach have shown markedly lower rates of deep infections, fewer revision procedures, shorter hospital stays, lower overall expenditures, and better outcomes, with lower amputation

and nonunion rates [11]. The effectiveness of structured interdisciplinary care in improving functional outcomes and quality of life for patients with open fractures is demonstrated by the success of orthoplastic centers.

Literature Review and Comparison

According to the protocols from the British Orthopaedic Association (BOA) and the British Association of Plastic Reconstructive and Aesthetic Surgeons (BAPRAS), treatment of open fractures must focus on early antibiotic prophylaxis, ortho-plastic input led by consultants, and early debridement with fracture fixation and soft tissue coverage within 72 hours [11]. Restoring as much anatomical alignment as feasible, reducing tamponade bleeding and edema at the fracture site, and reducing traction and pressure on the soft tissue and neurovascular systems are all objectives of reduction, according to the British Orthopaedic Association [11].

In our case, treatment adhered to all these principles as part of damage control orthopedics.

Conversion to final fixation following acute care may be managed with a "window period" in a cast or may involve ex-fix removal and internal fixation in a single procedure [12]. Given the circumstances of our case, the patient undergoes monthly imaging and bone regrowth follow-up after external fixation, with treatment not yet complete. Results are expected within 6 months, with next steps based on soft-tissue health and pin tract infections.

CONCLUSION

Open fracture management involves understanding anatomy, mechanisms of injury, patient physiology, and surgical procedures. It involves soft tissue healing, rebuilding, fixation, and initial wound decontamination. Complications are influenced by injury severity, treatment method, and patient traits. Collaboration between orthopedic and plastic surgeons is crucial for effective care and efficient treatment.

References:

1. Alic, T., & Hassa, E. (2022). Open fractures from Gustilo and Anderson to the present: A bibliometric analysis with global productivity and research trends. *Indian Journal of Orthopaedics*, 56(12), 2119–2132. <https://doi.org/10.1007/s43465-022-00743-z>
2. Axelrod, D., Comeau-Gauthier, M., Prada, C., Bzovsky, S., Heels-Ansdell, D., Petrisor, B., Jeray, K., Bhandari, M., Schemitsch, E., & Sprague, S. (2022). Change in Gustilo-Anderson classification at time of surgery does not increase risk for surgical site infection in patients with open fractures: A secondary analysis of a multicenter, prospective randomized controlled trial. *OTA International: The Open Access Journal of Orthopaedic Trauma*, 6(1), Article e231. <https://doi.org/10.1097/or9.000000000000231>
3. Costa, F. C. D., Reis, J. M. D., Reis, S. P. D., Bartelega, L. A., Melo, N. F., & Araujo, C. D. M. (2022). Epidemiology of open fractures and degree of satisfaction of initial care. *Acta Ortopedica Brasileira*, 30(4), Article e245221. <https://doi.org/10.1590/1413-785220223004e245221>
4. Abghari, M., Monroy, A., Schubl, S., Davidovitch, R., & Egol, K. (2015). Outcomes following low-energy civilian gunshot wound trauma to the lower extremities: Results of a standard protocol at an urban trauma center. *The Iowa Orthopaedic Journal*, 35, 65–69.

5. Maqungo, S., Kauta, N., Held, M., Mazibuko, T., Keel, M. J., Laubscher, M., & Ahmad, S. S. (2020). Gunshot injuries to the lower extremities: Issues, controversies and algorithm of management. *Injury*, 51(7), 1426–1431. <https://doi.org/10.1016/j.injury.2020.05.024>
6. Yim, G. H., & Hardwicke, J. T. (2018). The evolution and interpretation of the Gustilo and Anderson classification. *Journal of Bone and Joint Surgery*, 100(24), Article e152. <https://doi.org/10.2106/jbjs.18.00342>
7. Halawi, M. J., & Morwood, M. P. (2015). Acute management of open fractures: An evidence-based review. *Orthopedics*, 38(11), e1025–e1033. <https://doi.org/10.3928/01477447-20151020-12>
8. Sudduth, J. D., Moss, J. A., Spittler, C. A., Pham, V. H., Jones, L. C., Brown, J. T., & Bergin, P. F. (2020). Open fractures: Are we still treating the same types of infections? *Surgical Infections*, 21(9), 766–772. <https://doi.org/10.1089/sur.2019.140>
9. Khatri, J. P., Kumar, M., & Singh, C. M. (2020). Primary internal fixation in open fractures of tibia following high-velocity gunshot wounds: A single-centre experience. *International Orthopaedics*, 44(4), 685–691. <https://doi.org/10.1007/s00264-019-04387-x>
10. Trompeter, A. J., Furness, H., Kanakaris, N. K., & Costa, M. L. (2020). Classification of open fractures: The need to modernize. *The Bone & Joint Journal*, 102-B(11), 1431–1434. <https://doi.org/10.1302/0301-620x.102b11.bjj-2020-0947>
11. Davies, M., Dorrell, V., Grainger, C., Ahluwalia, A., Vasireddy, A., & Ahluwalia, R. (2022). Assessing and managing open fractures: A systematic approach. *British Journal of Hospital Medicine*, 83(12), 1–9. <https://doi.org/10.12968/hmed.2021.0578>
12. Dheenadhayalan, J., Nagashree, V., Devendra, A., Velmurugesan, P. S., & Rajasekaran, S. (2023). Management of open fractures: A narrative review. *Journal of Clinical Orthopaedics and Trauma*, 44, Article 102246. <https://doi.org/10.1016/j.jcot.2023.102246>
13. Elniel, A. R., & Giannoudis, P. V. (2018). Open fractures of the lower extremity. *EFORT Open Reviews*, 3(5), 316–325. <https://doi.org/10.1302/2058-5241.3.170072>
14. Ovaska, M. (2015). Complications in ankle fracture surgery. *Acta Orthopaedica*, 86(Suppl. 358), 1–35. <https://doi.org/10.3109/17453674.2014.1002273>

წვივის ძვლების ღია მოტეხილობების მკურნალობის ტაქტიკა (საინტერესო შემთხვევის აღწერა)

ნიკოლოზ ავაბაშვილი^{1,2}, ლევან ჩიკვატია^{1,2}, კრუპა სარა ტომას¹, დივინა მარია პუტორან¹

¹ თსსუ-ის, ორთოპედიისა და ტრავმატოლოგიის დეპარტამენტი;

² ს.ს. „ვიანი“ - ივ. ბოკერიას საუნივერსიტეტო ჰოსპიტალი

პასუხისმგებელი პირი: სერგო კობალავა, sergokobalava@gmail.com

DOI: <https://doi.org/10.48412/GTBGS.2026.14-15.64-68>

რეზიუმე | ღია მოტეხილობები, მათი მკურნალობა, გართულებების მართვა და პაციენტების ოპერაციის შემდგომი რეაბილიტაცია წარმოადგენს თანამედროვე ტრავმატოლოგია-ორთოპედიის აქტუალურ პრობლემას. დღემდე არ არსებობს ამ დაზიანებების მკურნალობის ერთიანი ალგორითმი. დავის საგანს წარმოადგენს ასევე ოსტეოსინთეზის მეთოდების შერჩევა და მათი შესრულების ოპტიმალური ვადები. ნაშრომში მოცემულია თსსუ-ის ტრავმატოლოგიისა და ორთოპედიის თანამშრომლების და ამავე უნივერსიტეტის სტუდენტების მიერ, ს.ს. „ვიანი“ - ივ. ბოკერიას საუნივერსიტეტო კლინიკაში ნამკურნალები პაციენტის (რომელსაც აღენიშნებოდა ქვედა კიდურის ძვლების ღია, ცეცხლნასროლი მოტეხილობა) საინტერესო შემთხვევის აღწერა. მიღებულ შედეგებზე დაყრდნობით გამოტანილი დასკვნების საფუძველზე გაკეთებულია ამგვარი ტრავმული დაზიანებების მკურნალობის ტაქტიკის შემუშავების კიდევ ერთი მცდელობა.

საკვანძო სიტყვები: მოტეხილობა, გარეგანი ფიქსაცია, ოსტეოსინთეზი

INNOVATIVE APPROACHES FOR OPTIMIZING THE TREATMENT OF ARTHROSIS WITH AUTOLOGOUS ADIPOSE TISSUE STROMAL-VASCULAR FRACTION (SVF) TRANSPLANTATION

Shalva Gabadadze, Givi Chikobava, Davit Kochiashvili, Alexandre Tsalughelashvili, Irakli Nadiradze, Malkhaz Pirpilashvili, Tamaz Kerdzevadze

Georgia Israeli Joint Clinic "Gidmedi"

Contact person: Shalva Gabadadze, ga20ebuli@gmail.com

DOI: <https://doi.org/10.48412/GTBGS.2026.14-15.69-77>

Rezume | **Aim:** Non-operative arthrosis treatment via stem cell transplantation is a current medical priority. Standard stromal-vascular fraction (SVF) transplantation yielded unsatisfactory results in some patients, prompting development of a modified, more effective protocol.

Methods: 20 patients (18F, 2M; ages 42–72) with grade I–II hip arthrosis were divided equally into a study group (modified protocol) and control group (standard method). Outcomes were assessed via instrumental imaging (ultrasound, X-ray, CT, MRI), laboratory tests, the Lequesne algofunctional index, and modified Harris scale. The modified method comprised three phases:

- Phase I – Pre-transplant elimination of acute inflammation and pain relief;
- Phase II – SVF preparation from autologous adipose tissue and joint injection;
- Phase III – Post-transplant management via magnetotherapy, early rehabilitation, and infection prevention.

Adipose tissue (80–120 ml) was harvested by liposuction and processed using Arthrex technology, yielding 10–12 ml of injectable SVF.

Results: In the study group, 8/10 patients fully restored limb support and joint function within 6 months, exceeding 90 points on the Harris scale. The control group showed slow, unstable recovery; only 3/10 achieved a clinically good result.

Conclusion: The modified SVF transplantation method is significantly more effective than the standard approach. Key success factors include pre-transplant inflammation control, post-transplant magnetotherapy, and infection prevention. No reliable laboratory marker for regeneration dynamics was identified; CT and MRI remain the primary monitoring tools. The authors recommend broader clinical trials with larger patient cohorts and longer observation periods.

Key words: Arthrosis, Regeneration, Transplantation, Stromal-Vascular Fraction (SVF), Standard method, Innovative method, Early rehabilitation.

RELEVANCE

Conservative treatment (treatment with medications, injection therapy, physiotherapy, and others) of the spine and joints is mainly aimed at eliminating pathological symptoms and restoring and rehabilitating joint function. However, the issue of regeneration – restoration of the injured tissue system is not considered in this chain [27, 28, 29, 39], which is why long-standing, continuous treatment often ends with an endoprosthesis, and an endoprosthesis has both positive and negative side effects [38].

Treatment of arthrosis without surgery is a significant challenge in modern medicine and biomedical engineering. It is possible only with timely started regenerative therapy, namely, with transplantation of stem cells in the injured joint [9, 12, 16, 20, 22, 35], however, transplantation conducted by us with standard method (taking adipose tissue from organism, preparation of the stromal-vascular fraction containing mesenchymal stem cells and injecting in target joint) showed a less effective result in the part of patients; Namely, the tempo of transformation of stem cells into collagen cells, accordingly, regeneration of tissues and restoration of joint were ongoing ineffectively

and dully, and in single case, it ended up in failure. Since the treatment of arthrosis with stem cell transplantation is, in principle, the most correct and physiologically the most correct form [4, 5, 6, 14], we doubted not the method but its management.

Clinical practice has shown that not only restyling but also a completely new design of the standard stem cell transplantation method is necessary to increase treatment efficiency.

For this purpose, we studied and analyzed the management of standard treatment, in which several organizational and medical reasons for low efficiency were identified, namely:

1. underestimation of the stem cell resource in patients' bodies,
2. transplantation of non-autologous stem cell mass into the target joint (low concentration of stem cells in material to be transplanted, insufficient volume of material),
3. coexistence of an acute or chronic inflammatory process in the joint along with arthrosis,
4. systemic and infectious diseases of connective tissue (viral, bacterial and fungal).

From an organizational perspective, standard treatment did not properly address patient preparation before transplantation, management of regeneration, or timely initiation of rehabilitation. Monitoring the patient's condition to prevent infectious and somatic diseases was overlooked, as was providing appropriate treatment when needed. Furthermore, in rare cases, necrotic-inflammatory processes caused by rough mechanical exposure of the joint's hard tissues during transplantation prevented regeneration, resulting in endoprosthesis placement.

Considering the fundamental shortcomings and incorrect approaches of the standard method for treating arthrosis with mesenchymal stem cell transplantation, we aimed to develop a modified and, most importantly, practically effective treatment method.

AIM OF THE STUDY

1. Investigation of the causes of the low effectiveness of the standard method for treating arthrosis with autologous adipose tissue stromal-vascular fraction (SVF) transplantation.
2. Creation of a new, modified, and effective method of treatment for arthrosis, taking into account the causes of the low effectiveness of stromal-vascular fraction transplantation treatment.
3. Comparison of the results of the modified and standard methods of treating arthrosis with stromal-vascular fraction transplantation.
4. Justification of the superiority of the modified treatment method compared to the standard one, based on the data from our own clinical studies, and its implementation in clinical practice.

MATERIAL AND METHODS

We studied 20 patients with I and II degrees of hip joint arthrosis. Of the patients, 18 were women, and 2 were men. Their ages were from 42 to 72. 10 patients underwent treatment with transplantation of autologous mesenchymal stem cells according to our protocol (the study group), and 10 patients underwent the same procedure using the standard method (the control group).

To monitor the degree of injury to the cartilage-ligament-bone tissues of the joint and the regeneration-restoration process, we used ultrasound, X-ray, densitometry (DEXA), computed tomography (CT), and magnetic resonance imaging (MRI) as needed.

During physical examinations, we evaluated joint shape, the condition of covering tissues, joint mobility, muscular power, and the support capacity of extremities by visual examination, using a dynamometer and a protractor. We assessed joint pain intensity using the Lequesne algofunctional scale [11] and qualitatively evaluated the treated joint using the Harris scale [7].

From laboratory tests, we studied complete blood count with a leukocyte formula, CRP, rheumatoid factor, uric acid content/level, calcium (total and ionized), alka-

line phosphatase in the blood, seromucoid (alpha-1-acid glycoprotein), and synovial fluid.

Patients in both groups were examined before transplantation and after 3 and 6 months from transplantation.

Based on clinical, laboratory, and instrumental examinations, we compared innovative and standard stem cell transplantation methods for the treatment of arthrosis.

The treatment protocol in the study group consisted of 3 steps:

Before transplantation

I Stage

a) Resolution of the acute inflammatory process in the musculoskeletal system of the macroorganism (patient) (if present), and the transfer of the chronic inflammatory process into recession.

b) Pain relief (or pain control) in the target joint(s) (if present).

II Stage

Preparation of the stromal-vascular fraction of mesenchymal stem cells from autologous adipose tissue and transplantation into the target joint. Stimulation of stem cell generation in the body and an increase in their absolute number.

After transplantation

III Stage

Management of the regeneration-restoration process of damaged tissue(s) after transplantation, and provision of therapeutic and prophylactic services to the patient to prevent infectious diseases or provide timely treatment if necessary.

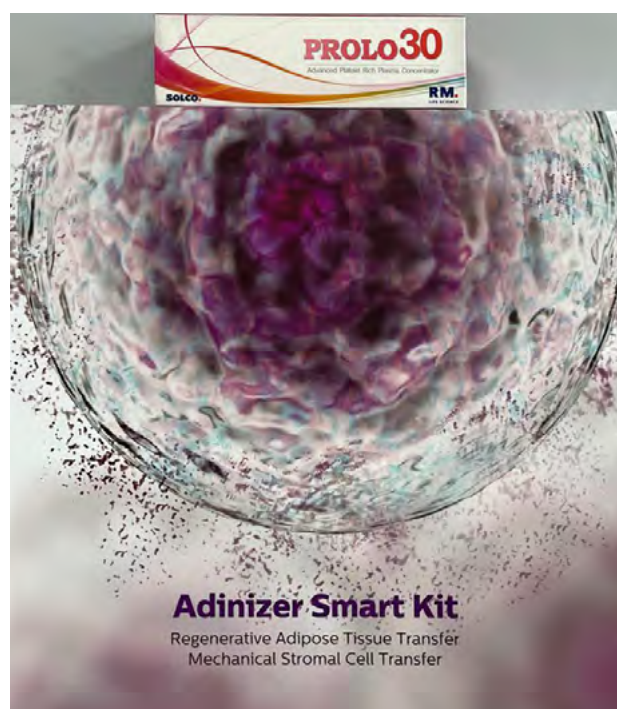


Photo 1.

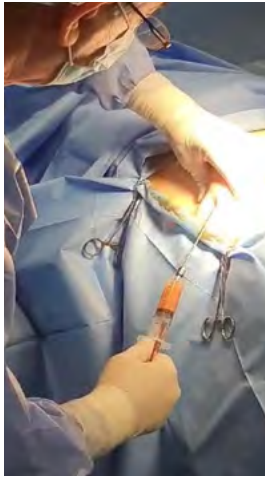


Photo 2.

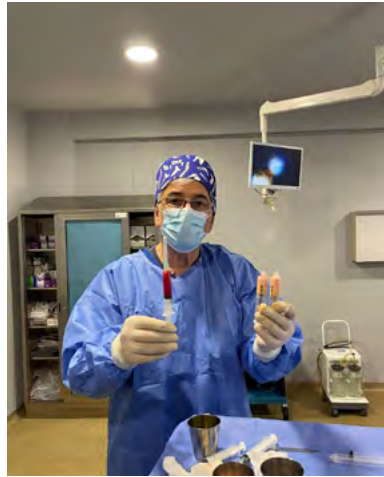

Photo 3.

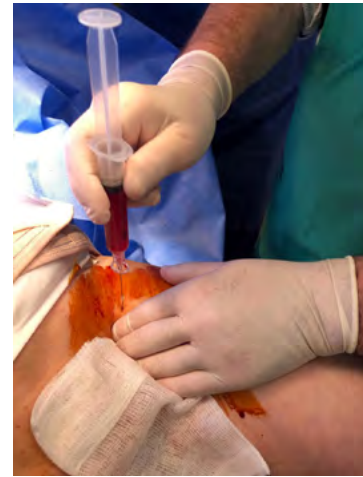

Photo 4.

TRANSPLANTATION TECHNIQUE

Transplantation place - surgical room.

Materials and tools required for transplantation: A toolkit from the South Korean firm "Adinizer" (Photo 1). Centrifuge SMART FUGE (Turkey).

We will mark the incision and liposuction sites on the front surface of the abdomen with a marker.

After aseptic processing of the surgical field and infiltration anesthesia of the adipose tissue (Sol. Lidocaine 1%, 120 ml + Sol. Adrenalinum 0.1%, 0.5 ml), we made two small cuts, each measuring 0.5 cm. Through the wounds, we insert a 20 cm-long titanium cannula fitted with a Luer-Lock syringe into the fatty tissue. (Photo 2) We perform liposuction by periodically moving the cannula back and forth and by constant aspiration (Photo 2). We inject the stem cell mass obtained by processing the fatty material (photo 3) into the target joint (Photo 4). We will place ice cubes in the liposuction area.

Technological assurance for the preparation of the stromal-vascular fraction containing mesenchymal stem cells from autologous adipose tissue.

Adipose tissue was harvested from the patient using the method described by Sydney R. Coleman [31]. The stromal-vascular fraction was prepared from adipose tissue using Arthrex technology [34] and a set of instruments from the South Korean company Adinizer. The processed adipose tissue was separated using the Turkish-manufactured centrifuge SMART FUGE.

COMPARATIVE CHARACTERIZATION OF STANDARD AND INNOVATIVE METHODS OF TREATING ARTHROSIS WITH STEM CELL TRANSPLANTATION

Joint mobility

As shown in Table 1, more than half of the patients in the study group had decreased flexion before transplantation. After 3 months, and especially after 6 months, joint mobility was notably improved; 7 patients flexed from 91° to 110°, and 3 patients flexed from 111° to 140°.

In the control group, the number of patients with flexion disability (5 patients) prevailed even 6 months after transplantation. 3 patients were able to extend the lower extremity at the hip from 91° to 110°, whereas only 2 extended it from 111° to 140°.

Before transplantation, only 5 patients in the study group could perform abduction from 16° to 30°, and only 1 could do so from 31° to 60°. After 6 months from transplantation, 6 and 4 patients were able to do it. Abduction was difficult for patients in the control group; only 2 patients were able to abduct the hip joint from 31° to 60°.

In the study group, 4 patients achieved adduction from 0° to 15° before transplantation, and 6 achieved adduction from 16° to 60°. After 6 months, all 10 patients achieved adduction from 16° to 60°! As for the control group, only 7 patients were able to do it.

In the study group, 7 patients performed external rotation from 0° to 30°, and only 3 performed it from 31° to 60° before transplantation. After 6 months of transplantation, 6 patients had already achieved external rotation from 31° to 60°, whereas only 3 patients in the control group had achieved the same.

Efficiency of pain cessation

Although 10 patients in the study group received anti-inflammatory, antispasmodic, and analgesic therapy before transplantation, only 4 patients did not experience night pain. In comparison, 5 and 1 patients experienced pain during movement and in a static position, respectively (Table 2).

After 6 months from transplantation, all patients of the study group completely recovered from night pain and discomfort.

Among the control group patients, only 1 patient did not experience night pain before transplantation from 10 patients! 6 and 3 patients complained about pain during movement or in a static position, respectively, after 6 months from transplantation, 3 patients had night pain, 3

Table 1. Assessment of movement in the hip joint in the study and control groups

Form of movement in joint	Angle of movement in the joint in degrees	Study group N10			Control group N10		
		Patient's quantity with separate form of movement in joint			Patient's quantity with separate form of movement in joint		
		Before transplantation	After 3 months from transplantation	After 6 months from transplantation	Before transplantation	After 3 months from transplantation	After 6 months from transplantation
Flexion	0-45	4	0	0	6	1	0
	45-90	5	2	0	3	6	5
	91-110	1	6	7	1	2	3
	111-140	0	2	3	0	1	1
Abduction	0-15	4	0	0	6	3	2
	16-30	5	8	6	3	6	6
	31-60	1	2	4	1	1	2
Adduction	0-15	4	2	0	7	6	3
	16-60	6	8	10	3	4	7
External rotation	0-30	7	6	4	8	8	7
	31-60	3	4	6	2	2	3

Table 2. Pain assessment in the study and control groups according to the Lequesne scale

Parameters	Importance	Points	Study group N10			Points	Control group N10		
			Patients's quantity according to separate parameter				Patients's quantity according to separate parameter		
			Before transplantation	After 3 months from transplantation	After 6 months from transplantation		Before transplantation	After 3 months from transplantation	After 6 months from transplantation
Night pain and discomfort	No	0	4	8	10	0	1	5	1
	While moving or in a certain position	1	5	2	0	1	6	4	6
	At the time of immobility	2	1	0	0	2	3	1	3
Duration of morning stiffness or pain after getting up	No	0	6	8	10	0	4	5	7
	<15	1	4	2	0	1	3	3	
	>=15	2	0	0	0	2	6	2	0
Pain increases after 30 minutes of standing	No	0	3	10	10	0	2	4	9
	Yes	1	7	0	0	1	8	3	1
Pain at the time of walking	No	0	0	9	10	0	0	4	8
	While passing a certain distance	1	3	1	0	1	4	4	2
	At the time of starting walk	2	7	0	0	2	6	2	0
At the time of sitting After 2 hours	No	0	2	7	10	0	4	6	8
	Yes	1	8	3	0	1	6	4	2

patients had pain at the time of movement, and all of them were recovered from pain in a static condition.

In the study group, 4 patients experienced morning stiffness syndrome characteristic of arthrosis; however, they mentioned that stiffness and discomfort lasted less than 15 minutes.

Morning stiffness was relieved in all patients after 6 months of transplantation.

In the control group, only 4 patients did not experience morning stiffness. 6 patients complained of pain upon waking. After 6 months of transplantation, morning stiffness resolved in 7 patients, and 3 patients still had mild pain upon waking.

In the study group, unlike the control group, pain on sitting, standing, and walking was significantly reduced before stem cell transplantation and was completely re-

Table 3. Assessment of the patients' condition in the study and control groups after 6 months from stem cells transplantation according to Harris scale

Type of complaint and physical activity	Intensity	Study group	Control group
Pain	Is not marked	10	7
	Insignificant		3
	Small at the time of activation		
	Strong at the time of activation		
	Permanent		
	Can't walk		
Movement in joint	Complete	10	8
	Insignificant restriction		2
	Moderate restriction		
	Important restriction		
	Strong restriction		
	Contracture		
Lameness	Is not marked	10	10
	Small		
	Moderate		
	Strong		
	Can't walk		
Assistive devices	Cane at long distance	10	7
	Cane always		3
	Two canes		
	Crutches		
Distance of walking	Unrestricted	10	7
	Up to 1 km		3
	Up to 200 m		
	Only at home		
	Can't walk		
Putting on socks and shoes	For 1 hour on any chair	10	7
	On low chair 0,5	2	3
	Can't		
Sitting	For 1 hour on any chair	10	7
	On low chair 0,5	2	3
	Can't		
Getting into transport	Can	10	10
	Can't		
Going up the stairs	Without railing	10	8
	With railing		
	Somehow		
	Can't		
Deformation	Is not marked	10	10
	Is marked		

Table 4. Qualitative assessment of results of treatment according to Harris scale (After 6 months)

Assessment	Point	Study group N10	Control group N10
Poor	<70	0	
Average	70-79	0	2
Good	80-90	2	5
Very good	>90	8	3
Good	80-90	2	5
Very good	>90	8	3

lieved after 6 months. During the same period, the degree of recovery in patients in the control group was noticeably lower than that of patients in the study group (see Table 2).

Types of patients' complaints and physical activities.

To assess the effectiveness of the innovative protocol, we compared the study and control groups, as well as the patients, on key criteria, including the type of complaint and physical activities.

As shown in Table 3, after 6 months of stem cell transplantation, walking distance and self-care ability are limited in the control group. Patients have difficulty climbing stairs, putting on socks, and putting on shoes. It should be noted that there is no difference between the groups in terms of lameness and joint deformity.

In the study group, in contrast to the control group, pain was relieved in all patients, and full joint movement was restored, indicating a significant advantage of the innovative treatment method over the standard one.

Qualitative assessment of the results of treatment according to the Harris scale (After 6 months).

As it can be seen from Table 4, after 6 months from transplantation in the control group, average result (70-79 points) was observed in 2 patients, good result (80-90 points) in 5 patients, very good result (more than 90 points) in only 3 patients, while in the study group, poor and average result was not observed in any patient. A good result was observed in 2 patients and a very good result in 8, demonstrating the clear advantage of the innovative treatment protocol we provide for arthrosis compared to the standard approach.

Discussion about the obtained results

Years of practical experience have shown us that treating arthrosis with medication, injection therapy, physiotherapy, and other routine methods is ineffective and often ends in surgery.

Modern medicine and bioengineering have shown that effective regeneration and restoration of the joint's degenerated hard and soft tissues are possible with mesenchymal stem cell transplantation. However, the standard transplantation we performed did not yield the desired result. Given that the treatment of arthrosis with stem cell transplantation is a fundamentally correct and physiologically most justified approach, we did not doubt the method itself, but rather its management. We aimed to identify shortcomings of standard stem cell transplantation through clinical studies and to develop a modified stem cell transplantation method for treating arthrosis.

The conducted studies revealed several medical and organizational shortcomings of the standard method of transplantation of the stromal-vascular fraction (SVF) containing mesenchymal stem cells of arthrosis.

Because stromal-vascular fraction (SVF) transplantation is often performed in one session, sufficient attention is not paid to the coexistence of infectious (viral, bacterial, fungal), non-infectious (contact with toxins, allergic reac-

tions, metabolic disorders), or mixed genesis inflammatory process in the target joint, along with arthrosis, which requires complete treatment before stem cell transplantation. Against the background of the inflammatory process, the rate of stem cell transformation into collagen cells, and, accordingly, tissue regeneration and joint restoration, is reduced.

Another disadvantage of the standard method of treating arthrosis with stromal-vascular fraction (SVF) is the neglect of periodic oxygenation of periarticular tissues after transplantation, early initiation of premature rehabilitation, and preventive measures for infectious diseases for the patient. The regenerative process stops against the background of prolonged febrile diseases with chills.

Our modified method of treating arthrosis with stromal-vascular fraction (SVF) transplantation significantly accelerated tissue regeneration, the restoration process, and the degree of recovery. namely: prior to transplantation, the inflammatory process in the target joints of patients in the study group had resolved, pain had been alleviated, and there was a marked reduction in soft-tissue edema. After 2 months of transplantation, the supportive capacity of the extremity began to improve, and it was corrected over 6 months; joint movement function was restored, and the patient regained the ability to perform physical activity. According to the Harris Scale, in 8 out of 10 cases, a very good result was obtained (>90 points)!

During the same observation period, the recovery process with standard treatment was slow; patients had difficulty with self-care, e.g., putting on socks, walking short and medium distances, and climbing and descending stairs, and, in most cases, used assistive devices (e.g., a cane). Good results were achieved in only 3 of 10 patients, demonstrating the clear advantage of our innovative stem cell transplantation method over the standard method for treating arthrosis.

It is noteworthy that no clinically valuable test reflecting the dynamics of the regenerative process has been found in laboratory studies. Also, instrumental examinations such as CT, MRI, ultrasound, and X-ray, especially during the first six months after transplantation, cannot accurately reflect the true state of regeneration and restoration of the damaged hard and soft tissues of the joint.

PRACTICAL RECOMMENDATIONS

1. Our innovative method of treating arthrosis with stem cell transplantation is much more effective than the standard one.
2. For successful treatment of arthrosis with transplantation of the stromal-vascular fraction (SVF) containing mesenchymal stem cells, it is advisable to follow the 3-stage protocol provided by us, namely consistently:

Before transplantation,

- a) Creating favorable conditions for stem cell proliferation and tissue regeneration in the target joint (reducing the inflammatory process, relieving pain).

During transplantation,

- a) Ensuring that a sufficient number of stem cells are introduced into the target joint.

After transplantation,

- a) Managing the process of regeneration-restoration of the degenerated tissues of the target joint (oxygenation of the joint, improvement of blood and lymph microcirculation in the hard and soft tissues of the joint.
 - b) Prevention of infectious diseases and, if necessary, immediate referral of the patient to a medical institution of the appropriate profile.
 - c) Timely activation of early rehabilitation.
3. It is recommended that the patient be at rest for 1 week after transplantation.
 4. Treatment of arthrosis with stromal-vascular fraction transplantation is recommended to be repeated 8-12 months after the first transplantation - especially in elderly patients (60-74).
 5. Since X-ray and ultrasound examinations, CT, and MRI (especially in the first six months after transplantation) do not reflect the real picture of regeneration-restoration, we can use the Lequesne and Harris algofunctional index to assess the result of treatment.
 6. In order to increase the validity of the innovative treatment method we provide, we consider it appropriate to expand further studies to preliminarily identify stem cells to be injected into the target joint and determine the optimal number of stem cells in the transplantation material. In addition, to fully reflect the process of tissue regeneration and restoration, it is necessary to create optimal laboratory and instrumental research methods.
 7. The study was conducted in a small group of patients, and the treatment outcomes were observed over a short period. Therefore, we also consider it advisable to broadly evaluate the presented treatment method and its conclusions in interested clinics, with the extensive involvement of specialists in the relevant fields.

CONCLUSION:

Treating arthrosis by transplanting adipose tissue stromal-vascular fraction is fundamentally correct and physiologically justified. Standard transplantation with a stromal-vascular fraction is relatively easy to implement, but the modified, complex treatment we present is much more effective.

The effectiveness of the treatment depends on a) accelerating the regeneration of damaged tissues by eliminating the inflammatory process in the target joint before transplantation; b) managing the regeneration-restoration process in the joint after transplantation, by timely initiation of early rehabilitation with magnetotherapy for oxygenation of hard and soft tissues. Practice has shown that providing prophylactic services in the post-transplantation period is essential to protect treated patients from infectious diseases. (The regenerative process stops against the

background of infectious diseases with fever and chills, and renewal becomes impossible!].

No clinically valuable test reflecting the dynamics of the regenerative process has been identified in the laboratory. We can assess the arrangement of articular cartilage, tendons, and bone tissues using CT and magnetic resonance imaging. The clinical course of the disease objectively reflects the patient's recovery.

Given the growing evidence supporting the modified method of treating osteoarthritis with transplantation of

the stromal-vascular fraction of autologous adipose tissue, we consider it appropriate to expand further studies to identify stem cells in the transplant material to be injected into the target joint and determine their optimal number.

The study was conducted in a small group of patients, and the evaluation of treatment results was carried out over a short period; therefore, we also consider it advisable to widely test the modified method and the conclusions presented by us in interested clinics, with broad involvement of relevant specialists.

References:

1. Centeno, C. J., Busse, D., Kisiday, J., Keohan, C., Freeman, M., & Karli, D. (2008). Regeneration of meniscus cartilage in a knee treated with percutaneously implanted autologous mesenchymal stem cells. *Medical Hypotheses*. <https://doi.org/10.1016/j.mehy.2008.06.042> [Archived September 11, 2017, at <https://web.archive.org/web/20170911235326/https://www.ncbi.nlm.nih.gov/pubmed/18786777>]
2. Chanda, D., Kumar, S., & Ponnazhagan, S. (2010). Therapeutic potential of adult bone marrow-derived mesenchymal stem cells in diseases of the skeleton. *Journal of Cellular Biochemistry*, 111, 249–257.
3. Dominici, M. L., Le Blanc, K., Mueller, I., Slaper-Cortenbach, I., Marini, F. C., Krause, D., & Horwitz, E. M. (2006). Minimal criteria for defining multipotent mesenchymal stromal cells: The International Society for Cellular Therapy position statement. *Cytotherapy*, 8(4), 315–317.
4. Erden, S. (2014). Stem cells and clinical applications [In Turkish]. *Journal of New Results in Engineering and Natural Sciences*, 3, 1–8.
5. Gözen, A., Unsal, S. S., & Gökcalp, M. A. (2015). Mesenchymal stem cell applications in orthopedics [In Turkish]. *Van Medical Journal*, 22, 131–137.
6. Han, Y., Li, X., Zhang, Y., Chang, F., & Ding, J. (2019). Mesenchymal stem cells for regenerative medicine. *Cells*.
7. Harris Hip Scale. (n.d.). Retrieved from <https://base.garant.ru/42576422/dbddb101044a4418b09fc135194e29d2>
8. Iskender, B., & Canatun, H. (2013). Induced pluripotent stem cells and cell therapy [In Turkish]. *Journal of Clinical and Experimental Investigations*, 4, 550–561.
9. Can, A. (2021). Stem cell biology, types, and therapeutic applications [In Turkish]. *Akademisyen Kitabevi*.
10. Kulakov, A., Kogan, E., Brailovskaya, T., Vedyeva, A., Zharkov, N., Krasilnikova, O., Krashennikov, M., Baranovskii, D., Rasulov, T., & Klabukov, I. (2021). Mesenchymal stromal cells enhance vascularization and epithelialization within 7 days after gingival augmentation with collagen matrices in rabbits. *Dentistry Journal*, 9(9), 101. <https://pubmed.ncbi.nlm.nih.gov/34562975>
11. Lequesne, M. (n.d.). Lequesne index. Retrieved from <https://base.garant.ru>
12. Liu, G., David, B. T., Trawczynski, M., & Fessler, R. G. (2020). Advances in pluripotent stem cells: History, mechanisms, technologies, and applications. *Stem Cell Reviews and Reports*, 16, 3–32.
13. Lyamina, S., Baranovskii, D., Kozhevnikova, E., Ivanova, T., Kalish, S., Sadekov, T., Klabukov, I., Maev, I., & Govarun, V. (2023). Mesenchymal stromal cells as a driver of inflammation. *International Journal of Molecular Sciences*, 24(7), 6372. <https://pubmed.ncbi.nlm.nih.gov/37047346> ISSN 1422-0067.
14. Oren, H. (2019). Stem cells [In Turkish]. *Dokuz Eylül University Faculty of Medicine Journal*, 33, 271–279.
15. Takahashi, K., & Yamanaka, S. (2006). Induction of pluripotent stem cells from mouse embryonic and adult fibroblast cultures by defined factors. *Cell*, 126, 663–676. Petit-Zeman, S. (2001). Regenerative medicine. *Nature Biotechnology*, 19, 201–205.
16. Bahar, L., & Akkuş, M. (2023). Stem cells and regenerative medicine – I [In Turkish]. *Efeakademi Yayınları*.
17. Şahin, F., Saydam, G., & Omay, S. B. (2005). Stem cell plasticity and stem cell therapy in clinical practice [In Turkish]. *Turkish Journal of Hematology-Oncology*, 15, 48–56.
18. Göksoy, T. (2024, March). Stem cell therapy [Presentation]. Istanbul, Turkey.
19. Nadareishvili, T. (2024, October 20). The first stem cell laboratory [Television broadcast]. Georgian Television, Channel 1.
20. Tekeli, S., Naghavi, E. A., Gökçe, B., et al. (2016). Stem cells, mesenchymal stem cells and current clinical applications [In Turkish]. *Istanbul Bilim University Florence Nightingale Transplantation Journal*, 1, 72–83.
21. Pendik Regional Hospital. (2024, September 3). Treatment of musculoskeletal diseases with stem cells. Istanbul, Turkey. <http://bolgehas-taneinternational.com>
22. Ural, A. U. (2006). Stem cells [In Turkish]. *Journal of the Turkish Association of Orthopaedics and Traumatology*, 5, 140–145.
23. Yamazaki, K., Kawabori, M., Seki, T., & Houkin, K. (2020). Clinical trials of stem cell treatment for spinal cord injury. *International Journal of Molecular Sciences*, 21, 3994.
24. Yu, J., Vodyanik, M. A., Smuga-Otto, K., Antosiewicz-Bourget, J., Frane, J. L., Tian, S., Nie, J., Jonsdottir, G. A., Ruotti, V., Stewart, R., Slukvin, I. I., & Thomson, J. A. (2007). Induced pluripotent stem cell lines derived from human somatic cells. *Science*. <https://doi.org/10.1126/science.1151526> [Archived September 22, 2018, via Wayback Machine]
25. Paltsev, M. A. (Ed.). (2009). *Biology of stem cells and cell technologies: A textbook for medical students (Vols. 1–2)* [In Russian; original title: Биология стволовых клеток и клеточные технологии]. Russian Academy of Sciences and Russian Academy of Medical Sciences.
26. Попов, В. (2010). *Introduction to the cell biology of stem cells* [In Russian; original title: Введение в клеточную биологию стволовых клеток]. ISBN 978-5-299-00430-4.

27. Vainboim, P. (2004). *Stem cells and regenerative medicine* [In Russian; original title: Стволовые клетки и регенеративная медицина]. Partner, 82(7). Partner Medien Haus GmbH & Co. KG, Dortmund, Germany.
28. Vermel, A. E. (2004). *Stem cells: General characteristics and prospects for application in clinical practice* [In Russian; original title: Стволовые клетки: общая характеристика и перспектива применения в клинической практике]. *Clinical Medicine*, (1), 5–11.
29. Deev, R. V. (2005). *The scientific legacy of Alexander Maksimov and the present day* [In Russian; original title: Научное наследие Александра Максимова и современность]. *Cell Transplantology and Tissue Engineering*, (1), 4–11.
30. Shlyakhto, E. V. (Ed.). (2010). *Transplantation medicine: Collection of scientific papers* [In Russian; original title: Трансплантационная медицина] (416 p.). Federal State Institution "Federal Almazov North-West Medical Research Centre," Ministry of Health and Social Development of the Russian Federation, St. Petersburg.
31. Zikiyarakhodzhaev, A. D., Ermoshenkova, M. V., Sergeeva, N. S., Saribekyan, E. K., Ueberreiter, K. (2015). *Lipofilling: Historical aspects and development prospects* [In Russian; original title: Липофилинг. Исторические аспекты и перспективы развития]. *Oncology: P.A. Herten Journal*, 4(4), 75–79. <https://doi.org/10.17116/onkolog20154475-77>
32. Leonova, E. V., Vismont, F. I., & Chanturiya, A. V. (2006). *Therapeutic principles in medicine: Their scientific foundations* [In Russian; original title: Лечебные принципы в медицине, их научные основы] (Educational-methodological manual). Minsk.
33. Belousov, Yu. B., et al. (2005). *Some current problems of clinical research on stem cells* [In Russian; original title: Некоторые актуальные проблемы клинических исследований стволовых клеток]. In Yu. B. Belousov (Gen. Ed.), *Ethical review of biomedical research* (Vol. 7, No. 1).
34. Pavlov, V. N., Kazikhinturov, A. A., Kazikhinturov, R. A., Agaverdiyev, M. A., Gareev, I. F., Beylerli, O. A., & Mazorov, B. Z. (2021). *Stromal vascular fraction: Biology and potential applications* [In Russian; original title: Стромально-васкулярная фракция: биология и потенциальное применение]. *Creative Surgery and Oncology*, 11(1), 92–99. <https://doi.org/10.24060/2076-3093-2021-11-1-92-99>
35. Shevela, E. Ya., Nitsa, N. A., Starostina, N. M., Baranov, S. I., Kozhevnikov, Yu. A., Popova, N. D., Batorov, E. V., Ostanin, A. A., & Chernykh, E. R. (2013). *First clinical results of the use of stromal vascular fraction cells from lipoaspirate in patients with gonarthrosis* [In Russian; original title: Первые клинические результаты применения клеток стромально-васкулярной фракции липоаспирата у пациентов с гонартрозом]. Federal State Budgetary Scientific Institution "Research Institute of Fundamental and Clinical Immunology," Novosibirsk. St. Petersburg Regional Branch of the Russian Association of Allergologists and Clinical Immunologists.
36. Semenov, M. G., Stepanova, Yu. V., & Troshchieva, D. O. (2016). *Prospects for the use of stem cells in reconstructive and restorative surgery of the maxillofacial region* [In Russian; original title: Перспективы применения стволовых клеток в реконструктивно-восстановительной хирургии челюстно-лицевой области].
37. Polyulyakh, M. V. (n.d.). *Review of materials from open sources* [In Russian; original title: Обзор материалов из открытых источников].
38. Polyulyakh, M. V. (2022, June 27). *Complications arising during joint arthroplasty and their prevention: Review of materials from open sources* [In Russian; original title: Осложнения, возникающие при эндопротезировании суставов и их профилактика]. Kyiv, Ukraine.
39. Brown, J. S., & Katz, A. J. (2019). *Principles of regenerative medicine* (3rd ed.). [Chapter: Cellular characteristics of the stromal vascular fraction] [In Russian translation; original title: Принципы регенеративной медицины (третье издание, 2019)].
40. Okhobetov, D. A., Pavlova, G. V., Zaraysky, E. I., & Kamalov, A. A. (2007). *Stem cells and their use in clinical practice: A literature review* [In Russian; original title: Стволовые клетки и их использование в клинической практике (обзор литературы)]. *Medical Sciences*, (5), 24.
41. Talantov, P. V. (2019). *0.05: Evidence-based medicine from magic to the search for immortality* [In Russian; original title: 0,05: Доказательная медицина от магии до поисков бессмертия] (560 p.). AST: CORPUS, Moscow.
42. Zorin, V., Cherkasov, V. R., Zorina, A. I., & Deev, R. V. (2010). *Characteristics of the global cell technology market* [In Russian; original title: Характеристика мирового рынка клеточных технологий].
43. Korochkin, L. I. (2005). *What are stem cells?* [In Russian; original title: Что такое стволовые клетки]. *Priroda [Nature]*, (6). <http://cbio.ru/page/43/id/147631>.

ინოვაციური მიღგომები ართროზის აუტოლოგიური ცხიმოვანი ქსოვილის სტრომულ-ვასკულური ფრაქციის (SVF) ტრანსპლანტაციით მკურნალობის ოპტიმიზაციისთვის

შალვა გაბადაძე, გივი ჩიქობავა, დავით ქორჩიაშვილი, ალექსანდრე ცალუღელაშვილი, ირაკლი ნადირაძე, მალხაზ ფირფილაშვილი, თამაზ კერძევაძე

საქართველო-ისრაელის ერთობლივი კლინიკა „გიდმედი“

პასუხისმგებელი პირი: შალვა გაბადაძე, gab20ebuli@gmail.com

DOI: <https://doi.org/10.48412/GTBGS.2026.14-15.69-77>

რეზიუმე

ართროზის უოპერაციოდ მკურნალობა თანამედროვე მედიცინის და ბიოსამედიცინო ინჟინერიის უაღრესად აქტუალური გამოწვევაა და დროულად დაწყებული რეგენერაციული თერაპიით, კერძოდ, დაზიანებულ სახსარში ლეროვანი უჯრედების ტრანსპლანტაციითაა შესაძლებელი [20,29,34].

კლინიკური კვლევის მიზანი იყო სტანდარტული ტრანსპლანტაციის დადებითი და უარყოფითი შედეგების გათვალისწინებით ართროზის სტრომულ-ვასკულური ფრაქციით (SVF) მკურნალობის მოდიფიცირებული, კომპლექსური და კლინიკურად ეფექტური მეთოდის შექმნა.

მასალა და მეთოდები: შესწავლილი იყო 20 პაციენტის (18 ქალი, 2 მამაკაცი, ასაკი - 42-72 წელი) მენჯ-ბარძაყის სახსრის I და II ხარისხის ართროზის მკურნალობის შედეგები. 10 პაციენტს (საკონტროლო ჯგუფი) აუტოლოგიური ცხიმოვანი ქსოვილის SVF-ით მკურნალობა ჩაუტარდა სტანდარტული, 10-ს (საკვლევი ჯგუფი) - კი მოდიფიცირებული მეთოდით.

სახსრის ქსოვილების დაზიანების ხარისხის და რეგენერაცია-რესტავრაციის პროცესის მონიტორინგისთვის გამოყენებული იყო ინსტრუმენტული და ლაბორატორიული კვლევები. მკურნალობის ეფექტურობა შეფასდა ლეკვესნეს ალგოფუნქციური ინდექსით [11] და ჰარისის მოდიფიცირებული სკალით (Harris HS) [7].

ართროზის SVF-ით მკურნალობის, ჩვენს მიერ მოდიფიცირებული, მეთოდი შედეგობდა 3 ეტაპისაგან: I ეტაპი - ტრანსპლანტაციამდე, დაზიანებულ სახსარში მწვავე ანთებით პროცესის აღგება, ქრონიკული ანთებით პროცესის რემისიაში გადაყვანა, ტკივილის კუპირება. II ეტაპი - აუტოლოგიური ცხიმოვანი ქსოვილისაგან მეზენქიმური ლეროვანი უჯრედების შემცველი SVF-ის მოზადება და სამიზნე სახსარში ტრანსპლანტაცია. III ეტაპი - ტრანსპლანტაციის შემდეგ სახსრის დაზიანებულ ქსოვილებში რეგენერაცია-რესტავრაციის პროცესის მართვა.

ტექნოლოგიური უზრუნველყოფა: პაციენტისაგან ცხიმოვანი ქსოვილის აღება წარმოებდა S. R. Coleman-ის მიხედვით [31], ცხიმოვანი ქსოვილისაგან SVF-ის მოზადება - ფირმა Arthrex-ის ტექნოლოგიით [34] და სამხრეთ კორეული ფირმა Adinizer-ის ინსტრუმენტთა ნაკრებით. გადამუშავებული ცხიმოვანი მასალისაგან SVF-ის სეპარაცია თურქული წარმოების ცენტრიფუგით SMART FUGE. ლიპოსაქციით მიღებული აუტოლოგიური ცხიმოვანი ქსოვილის რაოდენობა საშუალოდ 80-120 მლ-ს შეადგენდა სტრანსპლანტაციო SVF - 10-12 მლ-ს [39].

სტრომულ-ვასკულური ფრაქციის მოზადების და სამიზნე სახსარში ტრანსპლანტაციის პროტოკოლი.

პროცედურის ჩატარების ადგილი - საოპერაციო დარბაზი. მუცლის წინა კედლის ქვედა ნაწილის ასეპტიკური დამუშავების და ცხიმოვანი ქსოვილის ინფილტრაციული ანესთეზიის შემდეგ (Sol. Lidocaini 1%, 120ml+Sol. Adrenalinum 0.1% +0.5ml) საოპერაციო ველის მარჯვენა და მარცხენა ლატერალურ მიდამოებში ვატარებთ მცირე ზომის (0.5სმ) 2 განაკვეთს. ჭრილობებიდან ცხიმოვანი ქსოვილში შეგვყავს ლუერ-ლოკის შპრიცზე მორგებული ტიტანის კანიულა სიგრძით 20 სმ. კანიულის წინ და უკან გადაადგილებით, მუდმივი ასპირაციით ვაწარმოებთ ლიპოსაქციას, მიღებული ცხიმოვანი ქსოვილი იქვე გადაამუშავდება სპეციალური ტექნოლოგიით და მეზენქიმური ლეროვანი უჯრედებით მდიდარი SVF (10-12 მლ-ის ოდენობით) შეგვყავს მენჯ-ბარძაყის სახსარში.

შედეგები: ართროზის SVF-ით მკურნალობამ დააჩქარა დაზიანებულ ქსოვილთა რეგენერაცია-რესტავრაციის პროცესი. კერძოდ: ტრანსპლანტაციამდე საკვლევი ჯგუფის პაციენტების დაზიანებულ სახსრებში განსხვავებით საკონტროლო ჯგუფისაგან, აღაგდა ანთებითი პროცესი, მოიხსნა ტკივილი, შემცირდა პერიარტიკულური რბილი ქსოვილების შეშუპება. ტრანსპლანტაციიდან მე-2 თვეს, 10-დან 8 პაციენტში დაიწყო და რ თვის განმავლობაში სრულიად აღდგა კიდურების საყრდენუნარიანობა, სახსრის მოძრაობის ფუნქცია და ფიზიკური აქტივობის უნარი. პარისის სკალით გამოჯანმრთელების ინდექსმა 90 ქულას გადაჭარბა. დაკვირვების იგივე პერიოდში სტანდარტული მეთოდით მკურნალობისას საკონტროლო ჯგუფის პაციენტებში გამოჯანმრთელების პროცესი მიმდინარეობდა შედარებით ნელა და არასტაბილურად. კლინიკურად კარგი შედეგი მიღებული იქნა 10-დან მხოლოდ 3 პაციენტში.

დასკვნა: ცხიმოვანი ქსოვილის SVF-ის ტრანსპლანტაციით ართროზის მკურნალობა პრინციპულად სწორი და ფიზიოლოგიურად გამართლებულია. SVF სტანდარტული ტრანსპლანტაცია პრაქტიკულად ადვილი განსახორციელებელია, მაგრამ ჩვენს მიერ წარმოდგენილი მკურნალობის მოდიფიცირებული, კომპლექსური მეთოდი გაცილებით ეფექტურია.

მკურნალობის ეფექტურობას განაპირობებს: ა) ტრანსპლანტაციამდე სამიზნე სახსარში ანთებითი პროცესის აღაგებით დაზიანებული ქსოვილების რეგენერაციის დაჩქარება, ბ) ტრანსპლანტაციის შემდეგ სახსარში რეგენერაცია-რესტავრაციის პროცესის მართვა (მაგარი და რბილი ქსოვილების ოქსიგენაცია, მაგნიტოთერაპია და ადრეული რეაბილიტაციის დროული დაწყება), გ) ტრანსპლანტაციის შემდგომ პერიოდში პროფილაქტიკური ხასიათის სერვისების მიწოდებით პაციენტების ინფექციური დაავადებებისგან დაცვა..

რეგენერაციული პროცესის დინამიკის ამსახველი კლინიკურად ღირებული ტესტი ვერ იქნა ნაპოვნი. სახსრის ხრტილოვანი, მესოვანი და ძლოვანი ქსოვილების განახლებაზე შეგვიძლია, ვიმჯდეთ კტ და მაგნიტურ-რეზონანსული გამოკვლევებით. პაციენტის გამოჯანმრთელებას ობიექტურად ასახავს დაავადების მიმდინარეობის კლინიკური სურათი.

ჩვენი აზრით, მეთოდის ვალიდურობის გაზრდის მიზნით მიზანშეწონილია: 1) სამიზნე სახსარში შესავანი ლეროვანი უჯრედების წინასწარი იდენტიფიკაცია და მათი ოპტიმალური რაოდენობის განსაზღვრა; 2) კვლევის გაფართოება უფრო დიდ პაციენტთა ჯგუფში და უფრო ხანგრძლივი დაკვირვების პერიოდით; 3) მეთოდის ფართო აპრობაცია დაინტერესებულ კლინიკებში შესაბამისი პროფილის ექიმ-სპეციალისტთა ჩართულობით.

საკვანძო სიტყვები: ართროზი, რეგენერაცია, ტრანსპლანტაცია, სტრომულ-ვასკულური ფრაქცია (SVF), სტანდარტული მეთოდი, ინოვაციური მეთოდი, ადრეული რეაბილიტაცია.

THE EFFECT OF BARIATRIC SURGERY ON LIPID PROFILE AND LIVER FUNCTION IN PATIENTS WITH TYPE 2 DIABETES

Tamar Shervashidze¹, Rusudan Kvanchakhadze¹, David Abuladze², Liana Jashi³,
Miranda Shervashidze⁴, Iamze Taboridze¹

¹David Aghmashenebeli University of Georgia, ²Davit Abuladze Georgian-Italian Clinic,
³"Avicena" Batumi Medical University, ⁴Batumi Batumi Shota Rustaveli State University

Contact person: iamze Taboridze, iataboridze@yahoo.com

DOI: <https://doi.org/10.48412/GTBGS.2026.14-15.78-82>

Resume | **Background:** In patients with morbid obesity, with or without diabetes, bariatric surgery is more effective in improving metabolic disturbances compared to other treatment methods. Mechanisms contributing to dyslipidemia remission after bariatric surgery may include positive effects on fat distribution and function, improved insulin sensitivity, and reductions in liver fat content and improved liver function.

Objective: To evaluate changes in lipid profile and liver function following bariatric surgery.

Materials and Methods: We examined 91 patients with type 2 diabetes and morbid obesity who underwent bariatric surgery—sleeve gastrectomy— at the “David Abuladze Georgian-Italian Clinic”. Patients ranged in age from 23 to 67 years (mean 46.67 ± 8.60), including 50 women and 41 men. Clinical and laboratory data were compared before surgery and 2–4 years after surgery. We evaluated demographic characteristics, type and frequency of diet, preoperative weight loss, diabetes characteristics and duration, antihyperglycemic medications used preoperatively, liver function tests, lipid profile, and the number of “Healthy days” before and after surgery.

Results: A significant decrease in weight was observed postoperatively (from 146.8 kg to 97.9 kg). The frequency of fatty liver disease significantly decreased (from 88 patients [96.7%] to 18 patients [19.78%], $p < 0.0001$), as did the frequency of dyslipidemia (from 66 patients [72.53%] to 37 patients [40.66%], $p < 0.0001$). The number of patients with elevated liver function tests also decreased significantly. The frequency of elevated ALT decreased from 27.47% to 1.10% ($p < 0.0001$), and elevated AST and GGT were no longer observed after surgery. Fatty liver and dyslipidemia were negatively correlated with diabetes remission.

The likelihood of fatty liver remission after surgery increases with preoperative weight loss of 5–10%, increased physical activity, and diabetes remission. Conversely, it is reduced by alcohol consumption, a sedentary lifestyle, thyroid dysfunction, a high-fat diet, and preoperative weight loss of less than 5%.

Conclusions: In type 2 diabetes, bariatric surgery not only leads to weight loss but also promotes metabolic normalization. Diabetes remission after surgery is negatively correlated with dyslipidemia and fatty liver disease. Further reductions in fatty liver disease are predicted by diabetes remission and behavioral factors.

Key words: Bariatric surgery, dyslipidemia, behavioral factors, weight loss.

The past four decades have witnessed a marked increase in the prevalence of obesity and related metabolic disorders, particularly type 2 diabetes mellitus and nonalcoholic fatty liver disease. Currently, bariatric surgery is the most effective treatment for this growing global health problem, influencing food intake, gut hormone secretion, metabolic signaling pathways, and adipose tissue function [1].

Hepatic steatosis associated with metabolic disorders represents a serious public health problem [2, 3].

In patients with or without diabetes mellitus, bariatric surgery more effectively improves metabolic abnormalities than other treatment methods in cases of morbid obesity [4,5].

Mechanisms that contribute to dyslipidemia remission after bariatric surgery may include: positive effects on adipose tissue distribution and function, improved insulin sensitivity, reduced liver fat content, and improved hepatic function.

In the literature, bariatric and metabolic surgeries have been linked to dyslipidemia. However, there are limited

large-scale, long-term (>2 years) comparative studies examining the remission and relapse frequency of dyslipidemia after these procedures [6].

In the study by Natália S. Lira et al., the SG group showed a significant improvement in total cholesterol levels, although the change was less pronounced than in the RYGB group. Total cholesterol decreased by 8.7% at three months postoperatively and by 6.7% after 24 months of follow-up [7].

Total cholesterol (TC) and triglyceride levels generally decrease, while high-density lipoprotein (HDL) levels increase within 2 years after surgery [8].

According to research by Charu Sharma and others, patients' lipid profiles improved 3 years after sleeve gastrectomy. The results particularly confirmed an increase in high-density lipoprotein (HDL) levels [9].

In a study published in journal "Endocrinología, Diabetes y Nutrición", the effects of bariatric surgery on lipid profiles were evaluated over the next 60 months. The results showed that RYGB (Roux-en-Y gastric bypass) sig-

nificantly reduced total cholesterol levels, whereas SG (sleeve gastrectomy) did not. These findings suggest that RYGB may be more effective overall in reducing cholesterol levels in the long term.

At the end of the 60-month observation period, 54.8% of patients in the RYGB group met the criteria for complete remission of hypercholesterolemia ($P < .001$), compared to only 14.3% in the SG group ($P = ns$).

Nonalcoholic fatty liver disease (NAFLD) is very common in type 2 diabetes mellitus (T2DM), likely due to the high prevalence of obesity and insulin resistance associated with T2DM [10].

Our research aims to assess changes in the lipid profile and liver function.

MATERIALS AND METHODS:

We studied 91 patients with type 2 diabetes and morbid obesity at the David Abuladze Georgian-Italian Clinic, where they underwent bariatric surgery (sleeve gastrectomy). The patients' ages ranged from 23 to 67 years (mean age: 46.67 ± 8.60), and the group included 50 women and 41 men.

We compared patients' clinical and laboratory data before surgery and 2 to 4 years after surgery.

We studied the patients' demographic characteristics, type and frequency of diet, preoperative weight loss, diabetes characteristics, age, preoperative medications (A/D), liver function tests, lipid profile, and the number of healthy days before and after surgery.

Additionally, we compared patient characteristics by gender before and after surgery.

According to the Third National Cholesterol Education Program (NCEP) report, dyslipidemia is considered present in a patient when at least one of the following serum lipid indicators is abnormal:

- Total cholesterol $\geq 200\text{mg/dL}$;
- LDL $\geq 130\text{mg/dL}$;
- Triglycerides $\geq 150\text{mg/dL}$;
- HDL $< 50\text{mg/dL}$ for women or $< 40\text{mg/dL}$ for men [11].

Statistical analysis

For qualitative indicators, frequency and percentage values were determined; for quantitative indicators, the mean and standard deviation were calculated. Qualitative indicators were compared between groups using Fisher's exact test (F criterion), and changes before and after surgery were assessed using the Wilcoxon Signed Ranks Test.

Quantitative characteristics were compared using Student's t-test for independent samples. The equality of variances was tested using Levene's test. To compare quantitative data before and after surgery, the paired Student's t-test was applied.

Results were considered statistically significant when $p < 0.05$.

Statistical analysis was performed using SPSS version 23.

RESULTS:

Significant weight loss was observed in patients following bariatric surgery. The changes in

The weight change after surgery is shown in Diagram 1.

As shown in the diagram, the decrease in average patient weight after the operation appears reliable. Weight loss is accompanied by the normalization of metabolism. A reliable decrease in the frequency of patients exhibiting liver function abnormalities is also noted.

The change in liver function in patient samples after surgery is presented in Table 1.

The frequency of fatty liver disease and dyslipidemia is significantly reduced. The frequency of patients with elevated liver function tests is also significantly reduced.

There is no longer an increase in AST and GGT levels after surgery.

In this phase of the study, we analyzed the distribution of fatty liver disease by gender (Table 2). Patients demonstrated a decrease in the frequency of consuming simple carbohydrates and an increase in the frequency of consuming protein-rich foods.

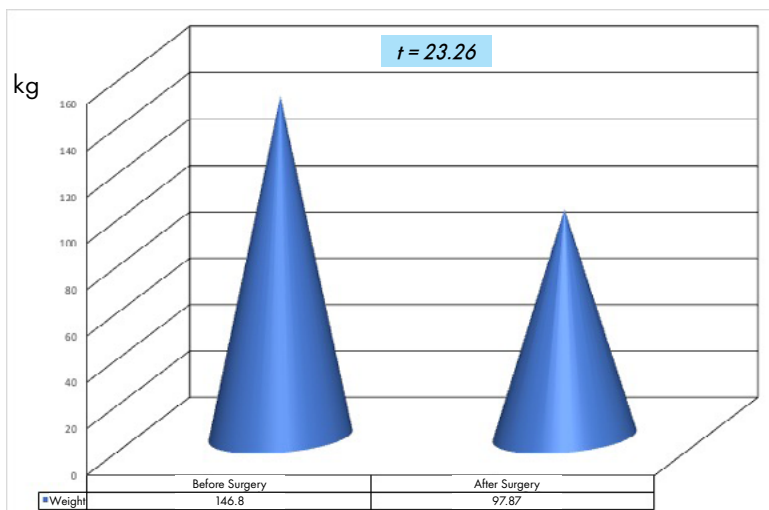


Diagram 1. Weight change after surgery

Table 1. Changes in clinical and laboratory characteristics after surgery

Factors		Before the Surgery		After the Surgery		p
		n	%	n	%	
Liver function sample elevation	ALT	25	27.47	1	1.10	<0.0001
	AST	24	26.37	0	0.00	<0.0001
	GGT	28	30.77	0	0.00	<0.0001
Comorbidities	Hypertension	75	82.42	27	29.67	0.000
	Fatty liver disease	88	96.7	18	19.78	<0.0001
	Dyslipidemia	66	72.53	37	40.66	<0.0001
Food type	Mixed	91	100	75	82.42	0.0001
	Simple Carbohydrates	58	63.74	19	20.88	<0.0001
	Protein	25	27.47	6	6.59	0.0003
	Complex Carbohydrates	78	85.71	5	5.49	<0.0001

Table 2. Distribution of fatty liver disease by gender

Factors	Man		Woman		F	p
Increased fatty liver (hepatosis) before surgery	51	98.08	37	94.87	0.71	0.4024
Fatty liver after surgery	12	23.08	6	15.38	0.82	0.3675
	<0.0001		<0.0001			

As observed, there was no statistically significant difference between sexes in the prevalence of fatty hepatosis before surgery, with 98.08% of males and 94.87% of females affected. After surgery, the frequency of fatty hepatosis decreased significantly in both groups, and no significant difference between the sexes was observed.

We conducted a correlation analysis to determine the relationship between fatty liver disease reduction and diabetes remission (Table 3).

Postoperative fatty hepatosis and dyslipidemia were negatively correlated with diabetes remission.

We used regression analysis to estimate the probability of remission of fatty hepatosis after surgery.

The relative chance of remission of fatty hepatosis after surgery is determined by: preoperative weight loss of 5-10%, increased physical activity, type 2 diabetes diabetes remission, reduced: alcohol consumption, sedentary lifestyle, thyroidopathy, fatty diet, preoperative weight loss <5%.

Table 3. The relationship between type 2 diabetes remission and liver function tests

		Diabetes remission
Fatty hepatosis after surgery	r	-0.252 *
	p	0.016
Dyslipidemia after surgery	r	-0.237 *
	p	0.024

Table 4. Estimation of the relative chance of remission of fatty hepatosis after surgery

Predictors	B	SE	Forest	p	Exp(B)	95% CI for EXP(B)	
						Lower	Upper
Sedentary lifestyle	-5.26	1.89	7.74	0.0054	0.005	0.001	0.211
Thyreopathy	-2.29	1.16	3.92	0.0476	0.101	0.010	0.976
Fatty diet	-3.13	1.06	8.69	0.0032	0.044	0.005	0.351
Preoperative weight loss 5%-10%	8.21	2.72	9.10	0.0026	369.527	17.773	7680.148
Preoperative weight loss <5%	-3.15	1.34	5.56	0.0184	0.043	0.003	0.587
Alcohol Consumption	-6.00	2.00	8.99	0.0027	0.002	0.001	0.125
Remission of type 2 diabetes	3.20	1.02	9.79	0.0018	24.419	3.300	180.685
Increase in physical activity	3.48	1.22	8.13	0.0044	32.516	2.968	356.182

DISCUSSION:

Bariatric surgery has a beneficial effect not only on weight loss but also on metabolic changes [12], as it alters usual lifestyle habits, leading to medical interventions [13].

The lipid profile of patients 3 years after sleeve gastrectomy, as reported by Charu Sharma et al., confirms improvements in outcomes, particularly an increase in high-density lipoproteins (HDL). A study published in "Endocrinologia, Diabetes y Nutrición" evaluated lipid profiles up to 60 months after surgery. The results showed that RYGB (Roux-en-Y gastric bypass) significantly reduced total cholesterol levels, whereas SG (sleeve gastrectomy) did not. RYGB may be more effective than other procedures in reducing total cholesterol and improving long-term prognosis. At the end of follow-up (60 months), 54.8% of patients in the RYGB group met the criteria for complete remission of hypercholesterolemia ($P < .001$), compared to only 14.3% in the SG group ($P = ns$) [9].

According to our study, both liver function parameters and lipid profiles normalize with weight loss following bariatric surgery.

Bariatric surgery provides intermediate benefits in the treatment of fatty liver disease associated with metabolic dysfunction [14].

According to our data, after bariatric surgery, the incidence of fatty liver disease decreases, and liver function test results normalize.

Predictors of reduced fatty liver disease include pre-operative weight loss of less than 5%, increased physical activity, and remission of type 2 diabetes.

CONCLUSIONS:

In type 2 diabetes, bariatric surgery not only results in weight loss but also normalizes metabolism. Following bariatric surgery, diabetes remission is negatively correlated with both dyslipidemia and fatty liver disease. Further reductions in fatty liver disease are predicted by diabetes remission and behavioral factors.

References:

1. Lefere, S., Onghena, L., Vanlander, A., Van Nieuwenhove, Y., Devisscher, L., & Geerts, A. (2021). Bariatric surgery and the liver—Mechanisms, benefits, and risks. *Obesity Reviews*, 22(9), e13294.
2. Chong, B., Kong, G., Shankar, K., Chew, H. J., Lin, C., Goh, R., Chin, Y. H., Tan, D. J., Chan, K. E., Lim, W. H., & Syn, N. (2023). The global syndemic of metabolic diseases in the young adult population: A consortium of trends and projections from the Global Burden of Disease 2000–2019. *Metabolism*, 141, 155402.
3. Sayiner, M., Koenig, A., Henry, L., & Younossi, Z. M. (2016). Epidemiology of nonalcoholic fatty liver disease and nonalcoholic steatohepatitis in the United States and the rest of the world. *Clinics in Liver Disease*, 20(2), 205–214.
4. Gentileschi, P., Bianciardi, E., Benavoli, D., & Campanelli, M. (2021). Metabolic surgery for type II diabetes: An update. *Acta Diabetologica*, 58(9), 1153–1159.
5. Shervashidze, T., Kvanchakhadze, R., Abuladze, D., Jashi, L., Shervashidze, M., Sakvarelidze, I., Makharadze, M., & Taboridze, I. (2025). The impact of bariatric surgery on type 2 diabetes mellitus remission in the Georgian population. *Georgian Medical News*, (358), 106–112.
6. Ricci, C., Gaeta, M., Rausa, E., Macchitella, Y., & Bonavina, L. (2014). Early impact of bariatric surgery on type II diabetes, hypertension, and hyperlipidemia: A systematic review, meta-analysis and meta-regression on 6,587 patients. *Obesity Surgery*, 24, 522–528.
7. Lira, N. S., Macedo, C. E., Belo, G. M., Santa-Cruz, F., Siqueira, L. T., & Ferraz, Á. A. (2018). Análise do perfil lipídico de pacientes submetidos à gastrectomia vertical e à derivação gástrica em Y de Roux. *Revista do Colégio Brasileiro de Cirurgiões*, 45, e1967.
8. Gómez-Martin, J. M., Balsa, J. A., Aracil, E., Cuadrado-Ayuso, M., Rosillo, M., De la Peña, G., Lasunción, M. A., Escobar-Morreale, H. F., & Botella-Carretero, J. I. (2018). Beneficial changes on plasma apolipoproteins A and B, high density lipoproteins and oxidized low density lipoproteins in obese women after bariatric surgery: Comparison between gastric bypass and sleeve gastrectomy. *Lipids in Health and Disease*, 17(1), 145. <https://doi.org/10.1186/s12944-018-0794-5>
9. Sharma, C., Platat, C., Gariballa, S., Muhairi, S. J. A., Aidaros, A. A., Mannaerts, G. H. H., Al Afari, H. S., Yasin, J., Al-Dirbashi, O. Y., & Alkaabi, J. (2021). Metabolomic profiling of lipids and fatty acids: 3 years postoperative laparoscopic sleeve gastrectomy. *Biology*, 10(4), 298. <https://doi.org/10.3390/biology10040298>
10. Bhatt, H. B., & Smith, R. J. (2015). Fatty liver disease in diabetes mellitus. *Hepatobiliary Surgery and Nutrition*, 4(2), 101.
11. National Cholesterol Education Program (NCEP) Expert Panel on Detection, Evaluation, and Treatment of High Blood Cholesterol in Adults (Adult Treatment Panel III). (2002). Third report of the National Cholesterol Education Program (NCEP) Expert Panel on Detection, Evaluation, and Treatment of High Blood Cholesterol in Adults (Adult Treatment Panel III) final report. *Circulation*, 106(25), 3143–3421.
12. Sabench, F., Rusu, E. C., Clavero-Mestres, H., Arredondo-Prats, V., Veciana-Molins, M., Muñoz-Piera, S., Vives, M., Aguilar, C., Bartra, E., París-Sans, M., & Alibalic, A. (2024). Metabolic-associated fatty liver disease and weight loss after bariatric surgery: A systematic review and meta-analysis. *Obesity Surgery*. Advance online publication.
13. Liu, D. F., Ma, Z. Y., Zhang, C. S., Lin, Q., Li, M. W., Su, K. Z., Li, Y. R., Wang, H. D., Zang, Q., & Dong, J. (2021). The effects of bariatric surgery on dyslipidemia and insulin resistance in overweight patients with or without type 2 diabetes: A systematic review and network meta-analysis. *Surgery for Obesity and Related Diseases*, 17(9), 1655–1672.
14. Navarro-Masip, È., Mestres, N., Zorzano-Martínez, M., Salinas-Roca, B., Sánchez, E., López-Cano, C., Herrerías, F., de la Fuente, M. C., Santamaría, M., León-Mengibar, J., & Soler, A. G. (2024). Mid-term effects of bariatric surgery on metabolic dysfunction-associated fatty liver disease remission and predictive factors: A prospective study with a focus on non-invasive diagnosis. *Obesity Surgery*, 34(3), 841–849.

ბარიატრიული ქირურგიის ეფექტი ლიპიდურ პროფილსა და ღვიძლის ფუნქციაზე ტიპი 2 დიაბეტის მქონე პაციენტებში

თამარ შერვაშიძე¹, რუსუდან კვანჭახაძე¹, დავით აბულაძე², ლია ჯაში³, მირანდა შერვაშიძე⁴, იამზე თაბორიძე¹

¹საქართველოს დავით აღმაშენებლის სახელობის უნივერსიტეტი; ²დავით აბულაძის ქართულ-იტალიური კლინიკა, ³„ავიციენა“ ბათუმის სამედიცინო უნივერსიტეტი, ⁴ბათუმის შოთა რუსთაველის სახელმწიფო უნივერსიტეტი

პასუხისმგებელი პირი: იამზე თაბორიძე, iataboridze@yahoo.com

DOI: <https://doi.org/10.48412/GTBGS.2026.14-15.78-82>

რეზიუმე მორბილული სიმსუქნის მქონე პაციენტებში, დიაბეტით ან მის გარეშე, ბარიატრიული ქირურგია უფრო ეფექტურად აუმჯობესებს მეტაბოლურ დარღვევებს, ვიდრე მკურნალობის სხვა მეთოდები. მექანიზმები, რომლებიც ხელს უწყობენ დისლიპიდემიის რემისიას ბარიატრიული ოპერაციის შემდეგ, შეიძლება მოიცავდეს დადებით გავლენას ცხიმოვანი ქსოვილის განაწილებაზე/ფუნქციაზე, ინსულინის მგრძობელობაზე, ღვიძლის ცხიმის შემცველობაზე/ფუნქციაზე. ჩვენი კვლევის მიზანია ლიპიდური სპექტრის და ღვიძლის ფუნქციის ცვლილების შეფასება.

მასალა და მეთოდები: შევისწავლეთ შაქრიანი დიაბეტით დაავადებული, მორბილული სიმსუქნის მქონე 91 პაციენტი, რომელთაც „დავით აბულაძის ქართულ-იტალიური კლინიკაში“ ჩატარდა ბარიატრიული ოპერაცია - კუჭის „სახელო-სებრი რეზექცია“ პაციენტების ასაკი მერყობდა 23-დან 67 წლამდე (46.67±8.60), მათ შორის 50 ქალი და 41 კაცი. შევადარეთ პაციენტთა კლინიკური და ლაბორატორიული მონაცემები ოპერაციამდე და ოპერაციიდან 2-4 წლის შემდეგ. შევისწავლეთ პაციენტთა დემოგრაფიული მახასიათებლები, კვების ტიპი და ჯერადობა, წინასაოპერაციო წონაში კლება, დიაბეტის მახასიათებლები და ხანდაზმულობა, ა/დ მედიკამენტები (ოპერაციამდე), ღვიძლის ფუნქციური სინჯები და ლიპიდური სპექტრი, „ჯანმრთელი დღეების“ რიცხვი ოპერაციამდე და ოპერაციის შემდეგ.

შედეგები: ბარიატრიული ოპერაციების შემდეგ პაციენტებში აღინიშნა წონის მკვეთრი კლება (146.8 ოპერაციამდე და 97.9 ოპერაციის შემდეგ). სარწმუნოდ მცირდება ცხიმოვანი ჰეპატოზის სიხშირე (შესაბამისად - 88 (96.7) და 18 (19.78), p<0.0001) და დისლიპიდემიის სიხშირე (66 (72.53) და 37 (40.66), p<0.0001).

სარწმუნოდ მცირდება იმ პაციენტთა სიხშირე, რომელთაც აღენიშნებოდათ ღვიძლის ფუნქციური სინჯების მატება. მცირდება ALT-ს მომატებული სიხშირე, შესაბამისად 25 (27.47) და 1 (1.10), (p <0.0001) საერთოდ აღარ გვაქვს AST და GGT-ს მომატებული მნიშვნელობა.

ოპერაციის შემდეგ ცხიმოვანი ჰეპატოზი და დისლიპიდემია უარყოფით კორელაციაშია დიაბეტის რემისიასთან. რეგულაციული ანალიზის საშუალებით განვსაზღვრეთ ცხიმოვანი ჰეპატოზის რემისიის ალბათობა ოპერაციის შემდეგ. ცხიმოვანი ჰეპატოზის რემისიის ფარდობით შანსს ოპერაციის შემდეგ ზრდის: წინა საოპერაციო წონაში კლება <5%, ფიზიკური აქტივობის გაზრდა, შაქრიანი დიაბეტის რემისია, ამცირებს: ალკოჰოლის მოხმარება, მჯდომარე ცხოვრება, თირეოპათია, ცხიმოვანი დიეტა, წინა საოპერაციო წონაში კლება <5%

დასკვნები:

- ტიპი 2 დიაბეტის დროს ბარიატრიული ოპერაცია, გარდა წონაში კლებისა, იწვევს მეტაბოლიზმის ნორმალიზებას;
- ბარიატრიული ოპერაციის შემდეგ, დიაბეტის რემისია უარყოფით კორელაციაშია დისლიპიდემიასთან და ცხიმოვან ჰეპატოზთან;
- ოპერაციის შემდგომი ცხიმოვანი ჰეპატოზის შემცირების პროგნოზს განსაზღვრავს დიაბეტის რემისია და ქცევითი ფაქტორები.

საკვანძო სიტყვები: ბარიატრიული ქირურგია, დისლიპიდემია, ქცევითი ფაქტორები, წონაში კლება.

A CASE OF MALIGNANT PERITONEAL MESOTHELIOMA AND ACUTE KIDNEY FAILURE FOLLOWING VIRAL INFECTION IN A MANGANESE MINER

Nino Chagiashvili^{1,2,5}, Nino Potckhverashvili⁵, Gia Tomadze^{4,5},
Marita Gugunava⁵, Tamar Chagiashvili³

¹Grigol Robakidze University, ²Georgian National University (SEU), ³Tbilisi State University, ⁴Tbilisi State Medical University, ⁵Pineo Medical Ecosystem

Contact person: Nino Chagiashvili, nchagiashvili1974@gmail.com

DOI: <https://doi.org/10.48412/GTBGS.2026.14-15.83-86>

Resume Malignant peritoneal mesothelioma (MPM) is a rare cancer typically linked to asbestos exposure, but other environmental factors, such as manganese dust, may also increase risk. This case report describes a 56-year-old male with diabetes, arterial hypertension, and a history of long-term manganese mining exposure, who developed acute kidney failure and massive ascites after a viral infection. Despite initial treatment, his condition worsened, and MPM was diagnosed after analysis of bloody ascitic fluid. This case emphasizes the role of occupational exposure in the development of MPM and highlights the diagnostic challenges posed by nonspecific symptoms. Early detection and better therapeutic options are needed to improve outcomes for MPM patients.

Key words: Malignant Peritoneal Mesothelioma, kidney failure, massive ascites, manganese dust, asbestosis

INTRODUCTION:

According to the American Cancer Society, asbestos exposure is the main cause of pleural mesothelioma. About 8 out of 10 people with mesothelioma have been exposed to asbestos. When asbestos fibers are breathed in, they travel to the ends of small air passages and reach the pleura, where they can cause inflammation and scarring. This may damage cells' DNA and cause changes that result in uncontrolled cell growth. If swallowed, these fibers can reach the abdominal lining, where they may contribute to peritoneal mesothelioma. But most people exposed to asbestos, even in large amounts, do not get mesothelioma [1]. Malignant peritoneal mesothelioma (MPM) is a rare but aggressive tumor arising from the peritoneal mesothelial cells. While asbestos exposure is the most well-established risk factor, other occupational exposures, including exposure to various minerals and fibers, can also increase the risk of developing mesothelioma. This case presents a 56-year-old male with a history of diabetes mellitus (DM) and hypertension (HTN), who worked in a manganese mine for several years. The patient developed acute kidney failure, anuria, and massive ascites following a viral infection. Despite initial supportive treatment, the diagnosis of MPM was confirmed after diagnostic procedures.

CASE PRESENTATION:

A 56-year-old male with a history of DM, HTN, and a known long-term occupational exposure to manganese dust presented with progressive abdominal distention, anuria, and acute kidney failure. Ten days prior, the patient had experienced a viral upper respiratory infection, after which he developed these symptoms. The patient had worked in a manganese mine for over 25 years, which

potentially contributed to his risk of developing mesothelioma. Additionally, the patient had been living with a Parkinson-like tremor for more than 15 years, a condition that might be linked to his chronic exposure to manganese, and a long-standing history of diabetes mellitus, further complicating his clinical presentation. His clinical course was marked by progressive worsening of renal function, requiring dialysis, and the development of significant ascites.

Initial treatment included diuretics, steroids, and albumin to manage fluid retention and renal failure. While partial diuresis occurred, with some improvement in urine output, the patient's condition continued to worsen. Ascites persisted, and despite adequate management, the patient's clinical status deteriorated further.

A CT scan confirmed the presence of ascitic fluid and peritoneal thickening (Figure 1), but despite appropriate diuresis, the ascites continued to increase. Peritoneal centesis was performed to analyze the ascitic fluid, which revealed bloody fluid. A biopsy confirmed the diagnosis of malignant peritoneal mesothelioma.

DISCUSSION:

This case emphasizes the importance of considering occupational exposure as a potential risk factor for malignant peritoneal mesothelioma (MPM), in addition to the well-established association with asbestos exposure. Although MPM is rare and its association with manganese exposure is not as well-established as with asbestos, some studies suggest that exposure to mineral dust, including manganese, can increase the risk of developing mesothelial tumors [2]. In this case, the patient's history of working in a manganese mine is an important factor to consider, as prolonged exposure to industrial dusts and fibers has been

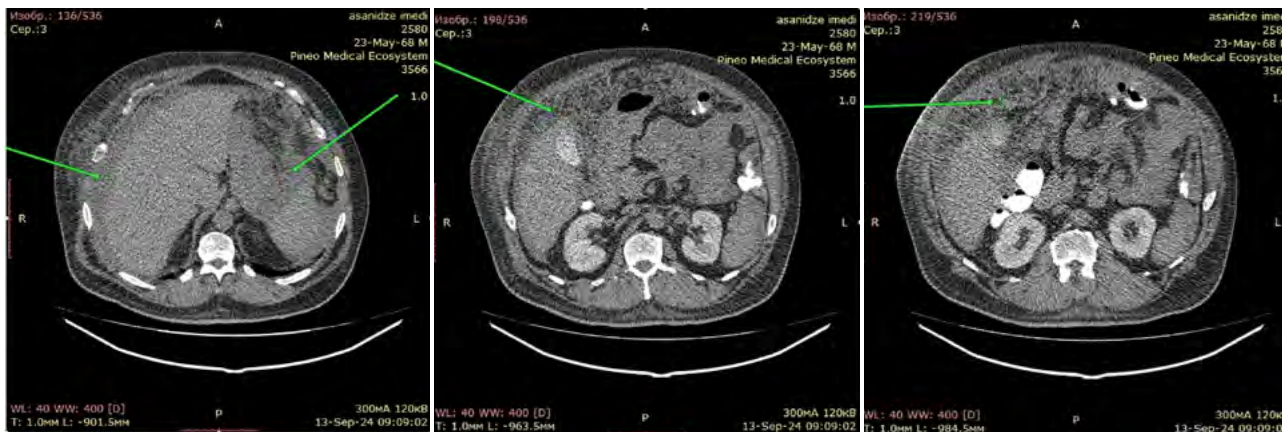


Figure 1. CT scan shows massive ascites, and peritoneal thickening

implicated in a variety of occupational lung diseases and malignancies, including mesothelioma. The exact mechanisms remain unclear, but it is believed that inhalation of certain particulate matter may lead to chronic inflammation or mesothelial cell damage, eventually leading to malignancy. Occupational exposure, particularly in industries such as mining, can pose a significant long-term risk to workers, even if the specific risk of MPM is lower than that of asbestos. According to the researchers Halina B. R Ilin and Claudina M. C. A. Nogueira, manganese is a natural element found in the environment, present in rocks, soil, water, air, and food. It's mainly used in steel production to make steel harder, and in many other industries, such as batteries, agriculture, ceramics, and glass. It's also an essential trace element for the body, helping with various biological functions and overall health. However, both too little and too much manganese can be harmful. Excessive manganese intake through breathing or swallowing can lead mostly to manganese buildup. In the brain, which causes brain damage and neurological problems. People working in industries like mining, welding, or steel production, where exposure to high levels of manganese is common, have been found to develop conditions like manganese poisoning and manganism (a disorder with symptoms similar to Parkinson's disease). There's growing concern about environmental manganese exposure as well, especially in vulnerable populations, although the full effects of lower levels of exposure are still unclear and require more research [3]. According to the literature, although less evidence directly links manganese exposure to peritoneal mesothelioma, it is plausible that manganese shares mechanisms with asbestos, especially with chronic exposure. Like asbestos, manganese can cause inflammation, oxidative stress, and DNA damage, which may contribute to cancer development. In occupational settings where both manganese and asbestos are present, the combined exposure could potentially heighten the risk of mesothelioma. Further research is necessary to fully understand the relationship between manganese and mesothelioma, but it is possible that manganese may contribute to the disease,

particularly when combined with other environmental toxins [4].

Acute kidney injury (AKI) is a known complication of viral infections, particularly in individuals with pre-existing comorbidities such as diabetes and hypertension. The viral infection in this patient likely contributed to the renal dysfunction, possibly through direct viral effects or through an inflammatory response that exacerbated renal impairment. However, the persistent ascites and eventual identification of MPM suggest that the renal failure was likely compounded by the underlying malignant peritoneal disease rather than being solely attributable to the viral infection. MPM often presents with nonspecific abdominal symptoms, including distention and ascites, and can be easily confused with other causes of abdominal fluid buildup [5,6]. In this patient, ascites was one of the earliest signs, but its cause remained unclear initially. Despite partial diuresis and steroid treatment, the patient's condition deteriorated, which is consistent with the clinical progression of MPM, where peritoneal involvement leads to increasing ascites and organ dysfunction. The diagnosis of MPM in this case was delayed, highlighting the challenge of diagnosing this condition in its early stages, especially when initial biopsies fail to yield definitive results. Peritoneal centesis, revealing bloody ascitic fluid, was essential to suspect the diagnosis. The cytological examination revealed abundant mesothelial cells with pleomorphism, large nuclei, and prominent nucleoli. Immunohistochemical staining, which showed mesothelin-positive results confirmed the diagnosis of MPM.

MPM is often diagnosed at advanced stages due to its nonspecific presentation. In this case, an initial biopsy did not yield a clear diagnosis, necessitating a further diagnostic workup. The bloody ascitic fluid obtained through peritoneal centesis was a key diagnostic clue, prompting further investigation. Imaging modalities such as CT scans may reveal signs of peritoneal thickening or fluid accumulation, but definitive diagnosis often requires aspiration of the ascitic fluid or biopsy of affected tissues [7,8,9]. The treatment options for MPM are limited, particularly in advanced cases where the malignancy has led to signifi-

cant organ dysfunction. Modern treatment for advanced peritoneal mesothelioma includes: cytoreductive surgery (CRS), hyperthermic intraperitoneal chemotherapy (HIPEC), systemic chemotherapy, targeted therapy (e.g., VEGF inhibitors [e.g., bevacizumab]), and immunotherapy (e.g., checkpoint inhibitors [e.g., nivolumab]). Cytoreductive surgery combined with hyperthermic intraperitoneal chemotherapy (HIPEC) is the standard treatment approach in selected cases, but the prognosis remains poor [10, 11, 12, 13]. In our case, the patient's renal failure, along with the worsening ascites despite diuretic therapy, suggests that the disease was far advanced at the time of diagnosis. The patient's prognosis is likely poor, and supportive care, including renal dialysis, may be the primary management approach.

The presented case highlights the importance of considering both occupational exposure and viral infections

in the differential diagnosis of patients with abdominal distention and ascites. While viral infections can lead to acute kidney injury, the persistence of ascites despite treatment should raise suspicion for a peritoneal malignancy, particularly in patients with potential occupational risks. Cytology, along with immunohistochemistry, plays a vital role in diagnosing peritoneal mesothelioma, especially when ascitic fluid is available for analysis. Pathological findings, including the identification of mesothelial cell proliferation and distinctive cellular features, along with specific immunohistochemical markers, are crucial for confirming the diagnosis and differentiating MPM from other abdominal malignancies. Future research should focus on improving early detection methods for MPM, especially in populations with known occupational exposures, to improve the prognosis of this rare and aggressive cancer.

References:

1. American Cancer Society medical and editorial content team. (n.d.). What causes mesothelioma? American Cancer Society. <https://www.cancer.org/cancer/risk-prevention/chemicals/asbestos.html>
2. Liu, Z., Zhang, L., & Cheng, W. (2017). Manganese exposure and its effects on human health: A review of recent evidence. *Journal of Environmental Health Science and Engineering*, 15, 9. <https://doi.org/10.1186/s40201-017-0302-9>
3. Röllin, H. B., & Nogueira, C. M. C. A. (2019). Manganese: Environmental pollution and health effects. In J. Nriagu (Ed.), *Encyclopedia of Environmental Health* (2nd ed., pp. 229–242). Elsevier. <https://doi.org/10.1016/b978-0-12-409548-9.11530-1>
4. Wang, L. I., Neuberger, D., & Christiani, D. C. (2004). Asbestos exposure, manganese superoxide dismutase (MnSOD) genotype, and lung cancer risk. *Journal of Occupational and Environmental Medicine*, 46(6), 556–564. <https://doi.org/10.1097/01.jom.0000128155.86648.a4>
5. Cicco, R., Di Maio, D., & Ferrante, D. (2019). Occupational exposure to manganese and risk of mesothelioma: A review of the literature. *Environmental Toxicology and Pharmacology*, 67, 62–68. <https://doi.org/10.1016/j.etap.2019.01.008>
6. Kauffman, S. A., Scherzer, L., & Roessler, E. (2015). Diagnostic approaches to peritoneal mesothelioma: Role of imaging, biopsy, and cytology. *European Journal of Surgical Oncology*, 41(5), 627–635. <https://doi.org/10.1016/j.ejso.2015.01.023>
7. Tsimaratos, M., Lebas, S., & Terrier, L. (2015). Malignant peritoneal mesothelioma: Clinical features, diagnostic and treatment approaches. *Journal of Clinical Oncological Surgery*, 32(6), 423–429. <https://doi.org/10.1016/j.jcos.2015.04.003>
8. Huang, X., Hong, Y., Xie, S.-Y., et al. (2022). Malignant peritoneal mesothelioma with massive ascites as the first symptom: A case report. *World Journal of Clinical Cases*, 10(28), 10317–10325. <https://doi.org/10.12998/wjcc.v10.i28.10317>
9. Gregory, S. N., Sarvestani, A. L., & Blakel, A. M. (2022). Malignant peritoneal mesothelioma literature review: Past, present, and future. *Journal of Clinical Oncology*, 40(12), 1309–1321. <https://doi.org/10.1200/JCO.21.01313>
10. Helm, J. H., Miura, J. T., Glenn, J. A., Marcus, R. K., Larrieux, G., Jayakrishnan, T. T., Donahue, A. E., Gamblin, T. C., Turaga, K. K., & Johnston, F. M. (2015). Cytoreductive surgery and hyperthermic intraperitoneal chemotherapy for malignant peritoneal mesothelioma: A systematic review and meta-analysis. *Annals of Surgical Oncology*, 22, 1686–1693.
11. Broeckx, G., & Pauwels, P. (2018). Malignant peritoneal mesothelioma: A review. *Translational Lung Cancer Research*, 7, 537–542.

ვირუსული ინფექციის შემდეგ მანიფესტირებული ავთვისებიანი პერიტონეალური მეზოთელიომისა და თირკმლის მწვავე უკმარისობის შემთხვევა მანგანუმის საბადოზე მომუშავე პირთან (შემთხვევის აღწერა)

ნინო ქალაიშვილი^{1,2,5}, ნინო ფოცხვერაშვილი⁵, გია თომაძე^{4,5}, მარიტა გუგუნავა⁵, თამარ ქალაიშვილი³

¹ გრივოლ რობაქიძის უნივერსიტეტი, ² საქართველოს ეროვნული უნივერსიტეტი, ³ თბილისის სახელმწიფო უნივერსიტეტი, ⁴ თბილისის სახელმწიფო სამედიცინო უნივერსიტეტი, ⁵ პინეო სამედიცინო ეკოსისტემა

პასუხისმგებელი პირი: ნინო ქალაიშვილი, nchagiasvili1974@gmail.com

DOI: <https://doi.org/10.48412/GTBGS.2026.14-15.83-86>

რეზიუმე პერიტონეუმის მეზოთელიომა არის იშვიათი კიბო, რომელიც ძირითადად ასბესტთან დაკავშირებულია, თუმცა სხვა გარემო ფაქტორები, როგორცაა მანგანუმის მტვერი, ასევე ზრდის ზ/ა განვითარების რისკს. სტატიაში აღწერილია 56 წლის მამაკაცის შემთხვევა, რომელსაც აქვს დიაბეტი, არტერიული ჰიპერტენზია. ანამნეზიდან ირკვევა ხანგრძლივი მუშაობა მანგანუმის საბადოზე. პაციენტს ვირუსული ინფექციის შემდეგ განუვითარდა თირკმლის მწვავე უკმარისობა, ასციტი. კომპლექსური მკურნალობის ფონზე მდგომარეობა არ გაუმჯობესდა, ჩაუტარდა ასციტური სითხის ციტოლოგიური გამოკვლევა, რითაც დადგინდა პერიტონეუმის მეზოთელიომა. ეს შემთხვევა ხაზს უსვამს მანგანუმის ზემოქმედების როლს მეზოთელიომის განვითარებაში. ავთვისებიანი პერიტონეუმის მეზოთელიომის დროული დიაგნოზი არის თანამედროვე მედიცინის დიდი გამოწვევა, მნიშვნელოვანია დაავადების დროული აღმოჩენა რათა მოხდეს მკურნალობის დროული დაწყება.

საკვანძო სიტყვები: ავთვისებიანი პერიტონეალური მეზოთელიომა, თირკმლის უკმარისობა, მასიური ასციტი, მანგანუმის მტვერი, აზბესტოზი

HEART FAILURE WITH PRESERVED LEFT VENTRICULAR EJECTION FRACTION IN PATIENTS WITH NORMAL SINUS RHYTHM AND ATRIAL FIBRILLATION: THE COMPARISON OF RISK FACTORS, SYMPTOMS, LABORATORY FINDINGS, AND ECHOCARDIOGRAPHIC PARAMETERS OF RIGHT VENTRICULAR DYSFUNCTION

Sergo Kobalava, Mikheil Tsverava

David Agmashenebeli University of Georgia (DAUG) and Department of Cardiology of Jerarsi Clinic

Contact person: Sergo Kobalava, sergokobalava@gmail.com

DOI: <https://doi.org/10.48412/GTBGS.2026.14-15.87-99>

Resume

Chronic heart failure with preserved left ventricular contractile function is of great interest to the modern medical community, especially to cardiologists. In chronic heart failure with preserved left ventricular contractility, the risk factors and comorbidities, including atrial fibrillation, underlying the development of HFpE are of relevance. Right ventricular involvement is a major concern in patients with HFpEF. RV dysfunction is associated not only with the severity of clinical signs and heart failure but also with future prognosis and disease outcome.

As atrial fibrillation itself contributes significantly not only to HFpE development but also to the secondary involvement of the RV in this process, it is interesting to identify possible differences in symptomatology, risk factors, and laboratory and instrumental study responses between patients with sinus rhythm and those with atrial fibrillation.

Methods: We looked at 34 patients with chronic heart failure with preserved left ventricular contractility. We divided the patients into two independent groups based on heart rhythm characteristics: sinus rhythm and atrial fibrillation. The analysis examined the data separately in two different groups and compared the results.

All major risk factors and comorbidities underlying HFpE and the parameters of diastolic dysfunction, as revealed by the increase in pulmonary artery pressure (PAP) and E/e' ratio, and the left atrial volume index (LAVI), were addressed. The functional status of the right ventricle and the incidence and degree of pulmonary hypertension were also investigated using echocardiographic parameters such as right ventricular fractional area (FAC), right ventricular myocardial performance index (RIMP), tricuspid annulus excursion (TAPSE), mean pulmonary artery pressure (mPAP), and tricuspid annular systolic velocity (S'). Finally, we compared the data from the two patient groups.

Conclusion: 1. The most common contributing factors to HFpEF are arterial hypertension, advanced age, atrial fibrillation, and acquired valvular pathology. 2. Increased left ventricular pressure is observed in both HFpEF groups, although this is more strongly related to the concurrent presence of AFib. 3. FAC is the least informative of the echocardiographic parameters of right ventricular dysfunction. TAPSE decreases in both patient groups, with greater decreases in the AFib group. S' is not an important diagnostic marker because of its decrease in a small patient population. The most informative parameter reflecting RV dysfunction is the RIMP, which increases by almost the same amount in sinus rhythm and atrial fibrillation. 4. Right atrial fibrillation is an important marker of right ventricular dysfunction in patients with HFpEF, particularly in AFib. 5. Pulmonary hypertension is present in all patients with HFpEF and AFib, as a secondary symptom of right-sided dysfunction.

Key words: Chronic heart failure with preserved left ventricular function (HFpEF), sinus rhythm, atrial fibrillation, right ventricular dysfunction, diastolic dysfunction, pulmonary artery hypertension (PAH), left atrium volume index (LAVI).

INTRUCTION

Chronic heart failure with preserved left ventricular contractility is of great interest to the modern medical community, especially to cardiologists. This pathology is particularly remarkable for the involvement of the right ventricle in the pathological process, in the context of its systolic and diastolic dysfunction, and for the increase in morbidity, hospitalization, and mortality.

In chronic heart failure with preserved left ventricular function, the greatest concern is for the risk factors and comorbidities that exist in specific patients. Also of interest are the patients' age and gender, which are highly correlated with HFpE development. Numerous peer-reviewed

papers and articles have been devoted to these topics. For example, a study by Sacha Bhatia, which looked at the incidence of comorbidities and risk factors in HFpE patients, found that the majority of patients were over 75 years of age, mostly women (66%), and usually had arterial hypertension (55%). In addition, HFpEF patients were more likely to have diabetes mellitus and hyperlipidemia, and were more likely to smoke. It is worth noting that HFpEF, unlike HFrEF, where coronary and peripheral vascular disease predominate, has been associated with increased incidence of arrhythmias, especially atrial fibrillation [1].

One of the major pathological mechanisms for the development of chronic heart failure with preserved left ven-

tricular contractility is the loss of left ventricular contractility and so-called diastolic dysfunction. This process always leads to secondary remodeling of the left atrium, which in turn increases the risk of various arrhythmias, particularly atrial fibrillation. Available data suggest that atrial fibrillation occurs in 20–65% of patients with HFpEF [2]. Furthermore, HFpEF predominantly affects elderly individuals, who are more likely to have coexisting conditions that further increase the risk of atrial fibrillation [3].

In HFpEF patients with normal sinus rhythm, RV dysfunction occurs in approximately 31–53% of cases, whereas in patients with atrial fibrillation, the prevalence increases to 65–73% [2].

There are many theories as to the mechanism by which atrial fibrillation leads to worsening of right ventricular dysfunction in patients with HFpEF. Some researchers believe the simultaneous remodeling of the right atrium may explain this condition. Left atrial remodeling may also contribute to increased left ventricular pressure, reflected by the E/e' ratio and pulmonary artery pressure. Interestingly, in the Ulric Sartipy study, the incidence of atrial fibrillation in HFpEF patients was also explained by severe diastolic dysfunction and an increase in the left ventricular pressure, which in turn contributed to a pronounced remodeling of the left atrium and ultimately resulted in a high risk of AF. In support of this idea, the author noted that NT-proBNP levels were significantly higher in patients with HFpEF and AF [4]. This fact further supports the idea of left atrial fibrillation and pronounced remodeling.

Assaf Ben Arzi also discusses mechanisms of arrhythmia development in HFpEF patients in his work, focusing primarily on atrial fibrillation. According to the author, diastolic dysfunction of the left ventricle, increased left ventricular filling pressure, and left atrial remodeling are the main reasons that increase the risk of atrial fibrillation in this group [5].

Regarding NT-proBNP, Carolyn Lam's article states that the diagnostic value of this laboratory marker for verifying HFpEF in patients with AF should be assessed with caution, since it is not uncommon for patients to experience no subjective symptoms of HF despite an increase in NT-proBNP. The increase in this indicator is primarily due to the existing arrhythmia itself and pronounced left atrial remodeling. Therefore, the author calls for the use of additional diagnostic parameters, primarily the left atrial volumetric index (LAVi) [6].

Some studies suggest that in the setting of AF, the longitudinal contractile function of the right ventricle is more impaired. This concept is further supported by echocardiographic studies showing that restoration of sinus rhythm results in parallel improvement in parameters assessing RV longitudinal contractility [7]. Incidentally, Maja Cikes also named the cause of the predominant involvement of the RV in atrial fibrillation in HFpEF patients as its longitudinal contractility disorder [3].

Based on the above, in our patients, it would be interesting to assess whether there is a certain difference between the sizes and volumes of the right atrium, as well as

whether there is a higher rate of increase in left ventricular filling pressure in patients with HFpEF in two independent groups of sinus rhythm and atrial fibrillation.

MATERIALS AND METHODS

Characteristics of the study population

A prospective study, the aim of which was to study the involvement of the right ventricle according to the analysis of echocardiographic parameters in patients with chronic heart failure with preserved left ventricular contractile function in patients with sinus rhythm and atrial fibrillation separately and to compare the above data with each other, was conducted at David Agmashenebeli University of Georgia (DAUG) and Department of Cardiology of Jerarsi Clinic. During the study, data from 34 patients were analyzed, collected from January 2024 to December 2024.

The ethical issues of this study were discussed and approved by the Scientific Council of the DAUG. All patients involved in the study signed a consent form approved by the Scientific Council of the DAUG.

Chronic heart failure with preserved left ventricular ejection fraction (HFpEF) was confirmed in all patients by

1. The subjective and objective symptoms characteristic of HFpEF.
2. Identifying risk factors that contributed to the development of HFpEF.
3. The presence of a minimum of 4 and a maximum of 9 points of H2FpEF.
4. NT-proBNP testing, the target value of which in patients with sinus rhythm was ≥ 220 pg/ml and in patients with atrial fibrillation was ≥ 660 pg/ml. In all patients, the left ventricular (LV) ejection fraction (EF) was $\geq 50\%$.

The exclusion criteria for this study were as follows: refusal to sign the informed consent form, left ventricular ejection fraction $< 50\%$, inappropriate increase in NT-proBNP, other clear causes of NT-proBNP elevation, including (myocarditis, hypertrophic cardiomyopathy with or without outflow tract obstruction), myocardial trauma, pericardial diseases, severe infection, recent blood and blood component infusion, severe and critical anemia, severe liver cirrhosis, severe acquired heart disease, any type of congenital heart disease, acute cardiac or neurological problem (MI, angina, stroke) within 3 months prior to the study, coronary revascularization (PCI or CABG) within 3 months prior to the study, presence of an artificial heart valve, current and active viral hepatitis, active oncological disease, pathologies, terminal stage of chronic renal failure and acute renal failure, patients with any primary pathology that may affect the functional state of the right ventricle (severe COPD, bronchial asthma, pulmonary tuberculosis and other diseases of a specific nature, interstitial/inflammatory pathologies of the lungs of various causes, severe pulmonary fibrosis, oncological diseases of the lungs, acute pulmonary embolism or pulmonary hypertension developed against the background of chronic pulmonary embolism - CTEPH, severe sleep apnea syndrome), patients with unsatisfactory echocardiography

in whom it will be technically impossible to perform a cardiac ultrasound examination.

Patients were divided into two large groups: the first group included individuals with sinus rhythm, and the second group included patients with atrial fibrillation.

Demographic parameters were studied in all patients, including gender, age, height, weight, body mass index (BMI), and smoking status.

Laboratory studies included NT-proBNP, complete blood count, troponin, creatinine, eGFR, glycemic status, and iron levels (for patients with anemia). The study was conducted at the Jerarsi Clinic.

Electrocardiography was studied. The following parameters were measured in patients with sinus rhythm: heart rate, RR, PQ (PR), QRS, QT, and QTc. In patients with atrial fibrillation, heart rate, QRS, QT, and QTc parameters were studied.

All patients included in the study underwent a comprehensive cardiac ultrasound examination using the MIN-DRAY Resona I9. Linear measurements and volume estimation of cardiac chambers and vessels were performed according to the 2015 guidelines of the American Society of Echocardiography and the European Association of Cardiovascular Imaging: Recommendations for Cardiac Chamber Quantification by Echocardiography in Adults: An Update from the American Society of Echocardiography and the European Association of Cardiovascular Imaging. The right ventricle was assessed using the 2010 Guidelines for the Echocardiographic Assessment of the Right Heart in Adults: A Report from the American Society of Echocardiography and the 2020 Guidelines for the Echocardiographic Assessment of the Right Heart in Adults: A Practical Guideline from the British Society of Echocardiography, and other relevant literature and guidelines. Diastolic function was assessed according to the 2016 guidelines of the American Society of Echocardiography and the European Association of Cardiovascular Imaging: Recommendations for the Evaluation of Left Ventricular Diastolic Function by Echocardiography: An Update from the American Society of Echocardiography and the European Association of Cardiovascular Imaging.

The left ventricle was studied using the 17-segment method. Diastolic function was assessed using the fol-

lowing parameters: mitral pulse-wave Doppler (PW Doppler), mitral annulus tissue Doppler, deceleration time (DT), isovolumic relaxation time (IVRT), left atrial volume (LA volume) and volumetric index (LAVi), and tricuspid valve peak flow velocity (TR velocity).

The data of the right chambers, including the right ventricle, were evaluated using the following parameters: linear measurements of the right chambers and their volumes, fractional shortening area (FAC), tricuspid annular plane systolic excursion (TAPSE), tricuspid annular tissue S' peak (TDI RV S'), RV index of myocardial performance (RIMP), and Eccentric Index (EI). The following parameters were taken as indicators of the norm: FAC < 35%, RIMP > 0.54, TAPSE < 20 mm, RV S' < 10, and EI < 1.

Based on the obtained data, we drew the appropriate conclusions, which will be discussed in detail below.

Statistical analysis

Patients in this study were divided into two main groups: those with sinus rhythm and those with atrial fibrillation. The data from both groups were entered into a single, common table and then analyzed separately. To test the null hypothesis, the independent-samples Mann-Whitney U test was used.

To perform the comparative analysis, Levene's Test for Equality of Variances was used. According to this analysis, the estimated difference in the pro-BNP index between patients with sinus rhythm and those with atrial fibrillation was examined.

Correlation analysis was also performed between echocardiographic parameters of right ventricular systolic and diastolic dysfunction and pro-BNP, NYHA class of heart failure, and diastolic dysfunction parameters such as PCWP, E/e' ratio, and LAVi index, using the Pearson correlation test.

In statistical analysis, if P < 0.05, the data were reliable; if P > 0.05, the data were less reliable and unreliable.

RESULTS

Our study included 34 patients. Of these, 29 patients were female (85.3%), and 5 patients were male (14.7%) (table 1).

Table 1. Distribution of patients by gender

		Frequency	percent	valid percent	cumulative percent
Valid	Female	29	85.3	85.3	85.3
	Male	5	14.7	14.7	100.0
	Total	34	100.0	100.0	

Table 2. Distribution of patients by heart rhythm

		Frequency	percent	valid percent	cumulative percent
Valid	Sinus Rhythm	14	41.2	41.2	41.2
	Atrial fibrillation	20	58.8	58.8	100.0
	Total	34	100.0	100.0	

Table 3. Minimum, maximum, and average patient ages

N	Valid	34
	Missing	0
Mean	79.24	
Std. Deviation	8.557	
Minimum	52	
Maximum	91	

Table 4. Minimum, maximum, and average patient weights

N	Valid	34
	Missing	0
Mean	81.332	
Std. Deviation	14.1150	
Minimum	55.0	
Maximum	120.0	

Of these 34 patients, 14 (41.2%) had normal sinus rhythm, while 20 (58.8%) had atrial fibrillation. Accordingly, almost the same number of patients were included in the sinus rhythm and AFiB groups (table 2).

Based on the patients' data, their age and weight were studied. After analysis, the average age of the subjects in the study was 79 years (M = 79.24; SD = 8.577), with a minimum of 52 years and a maximum of 91 years (table 3).

Among the anthropometric indicators, attention was paid to patients' weight, which was necessary when summing the H2FPEF scores. Accordingly, the average weight of the subjects was 81 kg (M = 81.33; SD = 14.11), with a minimum of 55 kg and a maximum of 120 kg (table 4).

CLINICAL FEATURES

In the management of HFpEF, a significant emphasis is placed on the risk factors and comorbidities that markedly elevate the likelihood of developing this specific type of chronic heart failure. Throughout our research, we sought to determine whether there is a notable distinction in risk factors and comorbidities between patients with sinus rhythm and those with atrial fibrillation. To this end, we used specialized questionnaires distributed to study participants, along with a thorough examination of their medical records, which enabled us to gather extensive data on the presence of comorbidities. Below, we present a table that effectively illustrates the distribution of the most critical

comorbidities and risk factors among patients with sinus rhythm and those with atrial fibrillation (diagram 1).

Patients also completed a questionnaire related to the study, in which they documented symptoms and complaints experienced prior to their participation. Analysis of these symptoms was instrumental in accurately diagnosing HFpEF and in the proper evaluation of the H2FpEF scoring system. Based on the gathered information, it was intriguing to investigate whether there were any shared symptoms prevalent among patients with sinus rhythm and those with atrial fibrillation. Additionally, we noted certain distinctions between the subjects in these two groups, particularly regarding which symptoms were more indicative of one group than the other. Below is a compilation of the most frequently reported subjective and objective symptoms observed in individuals with sinus rhythm and atrial fibrillation (diagram 2).

LABORATORY CHARACTERISTICS

Given that pro-BNP serves as a crucial diagnostic laboratory marker for chronic heart failure characterized by preserved left ventricular contractile function, we examined its parameters across all patients. Our initial focus was on determining the maximum, minimum, and mean pro-BNP values, leading to the following findings. In patients with sinus rhythm, the minimum pro-BNP value was 475.40 pg/ml, and the maximum was 8528.61 pg/ml. Conse-

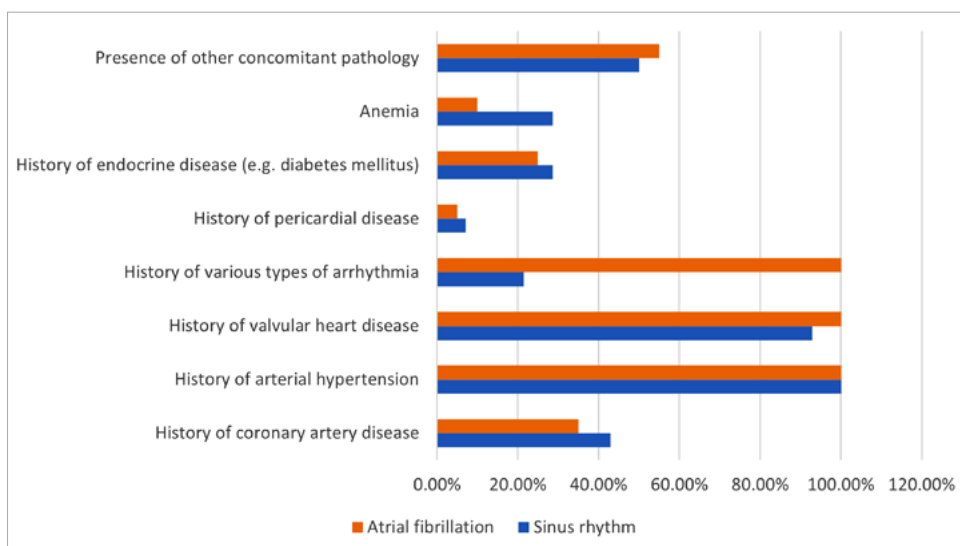


Diagram 1. The distribution of risk factors and comorbidities among patients exhibiting sinus rhythm and those with atrial fibrillation

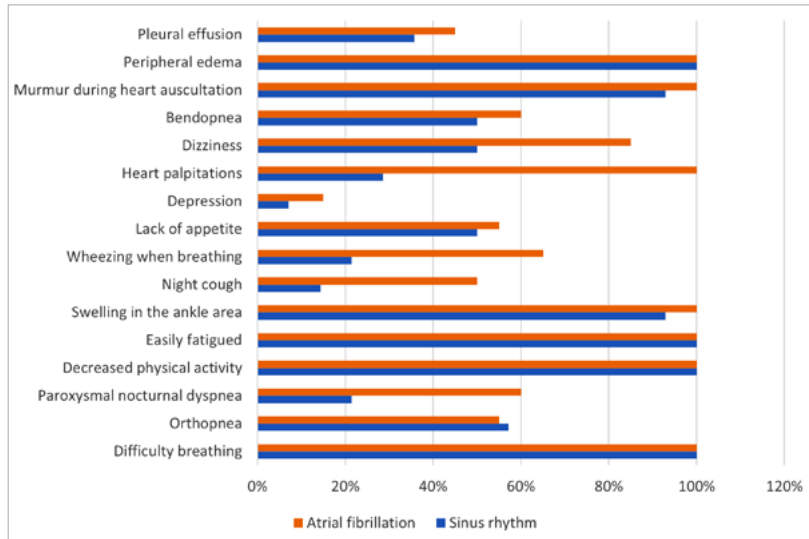


Diagram 2. The distribution of both subjective and objective symptoms among patients experiencing sinus rhythm and those with atrial fibrillation

Table 5. Minimum, maximum, and average pro-BNP levels observed in patients exhibiting sinus rhythm and those with atrial fibrillation

NT-proBNP (pg/ml)			
Sinus rhythm	N	Valid	14
		Missing	0
	Mean	2428.9643	
	Std. Deviation	2262.85817	
	Maximum	7671.90	
Atrial fibrillation	N	Valid	19
		Missing	1
	Mean	6571.1084	
	Std. Deviation	8528.61693	
	Maximum	35000.00	
<i>t</i> statistics - 2.07039, <i>p</i> -value - 0.04982			

quently, we calculated the mean value to be 2428 pg/ml (M = 2428.96; SD = 2262.85).

In patients diagnosed with atrial fibrillation, the minimum pro-BNP level recorded was 1274 pg/ml, while the maximum reached 8528.61 pg/ml. Consequently, the av-

erage pro-BNP level was calculated to be 6571.10 pg/ml (M = 6571.10; SD = 8528.61) (table 5).

It was intriguing to examine the degree of difference in pro-BNP increase between patients in the sinus rhythm and atrial fibrillation groups. The correlation analysis indicated no statistically significant difference in this variable between the two groups (P = .056). However, it is important to note that individuals with atrial fibrillation showed a greater increase in pro-BNP than those with sinus rhythm (table 6).

ECHOCARDIOGRAPHIC FEATURES

As previously mentioned in the literature review, the likelihood of developing atrial fibrillation in patients with HFpEF is heightened by several significant factors, including diastolic dysfunction, elevated left ventricular pressure, and left atrial remodeling. Conversely, alterations associated with HFpEF, particularly impaired diastolic function and left atrial remodeling, may contribute to the onset of AFib. In light of this perspective, it was pertinent to investigate the frequency of diastolic dysfunction parameters and elevated left ventricular filling pressure, including pulmonary capillary wedge pressure (PCWP), the increased

Table 6. Variations in pro-BNP levels between patients exhibiting sinus rhythm and those with atrial fibrillation

NT-proBNP (pg/ml)		Levene's Test for Equality of Variances		t-test for Equality of Means						
		F	Sig.	t	df	Sig. (2-tailed)	Mean Difference	Std. Error Difference	95% Confidence Interval of the Difference	
									Lower	Upper
NT-proBNP (pg/ml)	Equal variances assumed	6.883	.013	-1.765	31	.087	-4142.14414	2346.49165	-8927.84541	643.55714
	Equal variances not assumed			-2.023	21.334	.056	-4142.14414	2047.93341	-8396.99743	112.70916

E/e' ratio, and the augmented left atrial volumetric index (LAVi), within our study population. Additionally, we sought to determine whether there was a more distinct and specific variation in the aforementioned echocardiographic parameters between two independent cohorts: individuals in sinus rhythm and those with atrial fibrillation.

PCWP was determined using the equation $PWCP = 1.24 \times (E/e') + 1.9$, where E represents the peak height of the E wave measured by transmitral PW Doppler, and e' denotes the average values of the septal e' and lateral e' parameters acquired through tissue Doppler assessment of the mitral annulus. The standard PCWP threshold was set at <15 mmHg. Furthermore, the mean values of E and e' were utilized to approximate the filling pressure of the left ventricles when the normal E/e' ratio was ≤ 9 .

Consequently, the analysis of these parameters indicated that among 14 individuals with sinus rhythm, 9 patients demonstrated elevations in both the PCWP and E/e' ratio, suggesting an increase in left ventricular filling pres-

sure (64.3%). Conversely, 5 patients (35.7%) were found not to exhibit this issue (table 7).

Among the 20 participants categorized within the atrial fibrillation group, an elevation in PWCP and E/e' ratio, leading to left ventricular enlargement, was noted in 17 instances (85%), whereas the existence of the previously mentioned issue was refuted in merely 3 instances (15%) (table 8).

The left atrial volumetric index (LAVi) is an independent risk factor for the onset of atrial fibrillation. It is evident that, in the context of HFpEF, with left atrial remodeling and a corresponding rise in LAVi, the likelihood of developing this arrhythmia significantly increases, a point we have elaborated on previously. Conversely, atrial fibrillation, which is frequently considered a primary contributor to HFpEF, can also lead to left atrial remodeling and an increase in LAVi.

In our research, we aimed to determine which group predominantly showed an increase in LAVi and by how

Table 7. The rate at which left ventricular filling pressure rises in individuals exhibiting sinus rhythm

AF * Filling cavities Crosstabulation					
			Filling cavities		Total
			Elevated left ventricular filling pressure has not been observed	Elevated left ventricular filling pressure has been observed	
AF	Sinus rhythm	Count	5	9	14
		Expected Count	3.3	10.7	14.0
		% within AF	35.7%	64.3%	100.0%
	Atrial fibrillation	Count	3	17	20
		Expected Count	4.7	15.3	20.0
		% within AF	15.0%	85.0%	100.0%
Total	Count	8	26	34	
	Expected Count	8.0	26.0	34.0	
	% within AF	23.5%	76.5%	100.0%	

As per Fisher's analysis, the P value was determined to be 0.1611, indicating a lack of statistical significance

Table 8. The rate at which left ventricular filling pressure rises in individuals diagnosed with atrial fibrillation

AF * Filling cavities Crosstabulation					
			Filling cavities		Total
			Elevated left ventricular filling pressure has not been observed	Elevated left ventricular filling pressure has been observed	
Atrial fibrillation	Count	3	17	20	
	Expected Count	4.7	15.3	20.0	
	% within AF	15.0%	85.0%	100.0%	
Total	Count	8	26	34	
	Expected Count	8.0	26.0	34.0	
	% within AF	23.5%	76.5%	100.0%	

As stated by Fisher, the P value was recorded at 0.3507, indicating a lack of significance

much. The normal range for LAVi was established as < 34 ml/m². A mild increase was classified as 34–41 ml/m²; a LAVi measurement of 42–48 ml/m² was deemed moderately elevated, while values exceeding 48 ml/m² were categorized as markedly elevated. Based on these criteria, among 14 patients with sinus rhythm, LAVi remained within normal limits for 7 individuals (50%), whereas the remaining 7 patients (50%) exhibited elevated levels; within this group, a mild increase in LAVi was noted in 3 patients (21.4%), a moderate increase was identified in 2 patients (14.3%), and a significant increase was also recorded in 2 patients (14.3%) (table 9).

Regarding the 20 individuals diagnosed with atrial fibrillation, we obtained varied responses: only 1 patient had a normal LAVi (5%). Among the individuals assessed,

LAVi was slightly elevated in 7 patients (35%), moderately elevated in 4 patients (20%), and substantially elevated in 8 patients (40%) (table 10).

The primary objective of the research was to determine the extent to which deviations from the normative values of right ventricular dysfunction parameters were more pronounced in patients with sinus rhythm than in those with atrial fibrillation. Our focus was on identifying the parameter that most accurately indicated right ventricular dysfunction, regardless of the subject's group. Additionally, we sought to explore the relationship between echocardiographic parameters of right ventricular dysfunction and the characteristics of the rhythm. To achieve this, we examined indicators that reflect the functional status of the right ventricle, including FAC, TAPSE, RIMP, and S[∞].

Table 9. LAVi measurement in individuals exhibiting sinus rhythm

AF * LAVi_Groups Crosstabulation			LAVi_Groups				Total
			Normal	Slight enhancement	Moderate enhancement	Significant enhancement	
AF	Sinus rhythm	Count	7	3	2	2	14
		Expected Count	3.3	4.1	2.5	4.1	14.0
		% within AF	50.0%	21.4%	14.3%	14.3%	100.0%

Table 10. LAVi measurement in individuals exhibiting atrial fibrillation

AF * LAVi_Groups Crosstabulation			LAVi_Groups				Total
			Normal	Slight enhancement	Moderate enhancement	Significant enhancement	
Atrial fibrillation		Count	1	7	4	8	20
		Expected Count	4.7	5.9	3.5	5.9	20.0
		% within AF	5.0%	35.0%	20.0%	40.0%	100.0%

The analysis revealed that FAC had the lowest specificity for indicating right ventricular dysfunction in patients from both groups. A reduction in FAC to below 35% was observed in only 2 of 34 patients, with 1 in the sinus rhythm group and 1 in the atrial fibrillation group (table 11).

In the context of TAPSE, a reduction in this measurement (<20 mm) was observed in 20 of 34 patients (50.8%). Among the 14 patients with sinus rhythm, 6 (42.9%) had a decline in TAPSE below the relevant threshold. Conversely,

within the group of 20 patients diagnosed with atrial fibrillation, a decrease in this metric was recorded in 14 patients (70%) (table 12).

While analyzing S[∞], we observed a reduction (< 10 cm/s) in 11 patients, representing 32.4% of the total 34 patients. Furthermore, 4 cases (28.6%) were identified within the sinus rhythm group, while 7 patients (35%) were categorized in the atrial fibrillation group (table 13).

Table 11. The rate at which FAC decreases in patients from both groups

AF * FAC_1 Crosstabulation					
			FAC_1		Total
			Normal	Decreased	
AF	Sinus rhythm	Count	13	1	14
		% within AF	92.9%	7.1%	100.0%
	Atrial fibrillation	Count	19	1	20
		% within AF	95.0%	5.0%	100.0%
Total		Count	32	2	34
		% within AF	94.1%	5.9%	100.0%

As stated by Fisher, the P value was recorded at 0.6613, indicating a lack of statistical significance

Table 12. The rate at which FAC decreases in patients from both groups

AF * TAPSE_1 Crosstabulation					
			TAPSE_1		Total
			Normal	Decreased	
AF	Sinus rhythm	Count	8	6	14
		% within AF	57.1%	42.9%	100.0%
	Atrial fibrillation	Count	6	14	20
		% within AF	30.0%	70.0%	100.0%
Total		Count	14	20	34
		% within AF	41.2%	58.8%	100.0%

As stated by Fisher, the P value was recorded at 0.1097, indicating a lack of statistical significance

Table 13. The rate at which S` decreases in patients from both groups

AF * S_1 Crosstabulation			S_1		Total
			Normal	Decreased	
AF	Sinus rhythm	Count	10	4	14
		% within AF	71.4%	28.6%	100.0%
	Atrial fibrillation	Count	13	7	20
		% within AF	65.0%	35.0%	100.0%
Total		Count	23	11	34
		% within AF	67.6%	32.4%	100.0%

Fisher reported a P value of 0.4945, indicating that it was not statistically significant

Table 14. The rate at which RIMP decreases in patients from both groups

AF * RIMP_1 Crosstabulation			RIMP_1		Total
			Normal	Decreased	
AF	Sinus rhythm	Count	2	12	14
		% within AF	14.3%	85.7%	100.0%
	Atrial fibrillation	Count	5	15	20
		% within AF	25.0%	75.0%	100.0%
Total		Count	7	27	34
		% within AF	20.6%	79.4%	100.0%

As stated by Fisher, the P value was 0.3775, indicating that it was not statistically significant

Regarding the rise in RIMP (>0.54), it was observed in 27 of the 34 individuals assessed (79.4%). Furthermore, among the 14 patients in sinus rhythm, deviations from the standard for this parameter were identified in 12 cases (85.7%), whereas in the group of 20 patients with atrial fibrillation, deviations were observed in 15 cases (75%) (table 14).

Upon further examination of the distribution of FAC, TAPSE, RIMP, and S` deviations from the normative values in individuals exhibiting sinus rhythm and those with atrial fibrillation, we can identify the following response patterns: Deviations in FAC from the norm were noted equally, at 50%, in both cohorts, although such deviations were the least frequently observed. Regarding TAPSE, deviations from the norm were present in 30% of patients with sinus rhythm, while 70% of subjects in the atrial fibrillation cohort exhibited such deviations. Deviations in S` from the norm were identified in 36.4% of individuals with sinus rhythm and in 63.6% of those with atrial fibrillation. Regarding RIMP, deviations from the norm were observed in 44.4% of individuals with sinus rhythm and 55.6% with atrial fibrillation (table 15).

When discussing right ventricular dysfunction, it is essential to examine not only the echocardiographic parameters previously highlighted but also the right ventricular dimensions and volumes. These parameters were similarly assessed in our study participants. We specifically focused on the basal right ventricular size in the apical 4-chamber view, with a normative value of < 41 mm, irrespective of gender. By analyzing data from 34 patients, we found that the basal right ventricular size was elevated in 7 individuals (20.6%). Among these, 1 patient was categorized in the sinus rhythm group (7.1%), while 6 individuals were categorized in the atrial fibrillation group (30%) (table 16).

We also examined right ventricular end-diastolic volume, with normal values < 44 ml in men and < 36 ml in women. Our focus was on the extent of right ventricular dilatation in both groups of participants. The findings were as follows: in a cohort of 29 female patients, 14 instances (48.3%) of right ventricular dilatation were noted, irrespective of heart rhythm, whereas in the male group, this number was 5 (100%) (table 17).

Table 15. Deviation from the standard of TAPSE, S`, FAC, and RIMP observed in patients from both groups

Impaired contractile function of the right ventricle Crosstabulation			AF		Total
			Sinus rhythm	Atrial fibrillation	
Impaired contractile function of the right ventricle	FAC_1	n	1	1	2
		%	50.0%	50.0%	
	RIMP_1	n	12	15	27
		%	44.4%	55.6%	
	TAPSE_1	n	6	14	20
		%	30.0%	70.0%	
	S_1	n	4	7	11
		%	36.4%	63.6%	
Total		n	13	19	32

Percentages and totals are based on respondents.

a. Dichotomy group tabulated at value 1.

Fisher reported that the P value for the FAC parameter was 0.6667, indicating a lack of significance. Fisher indicated that the P value for the RIMP parameter was 0.5011, which was also not significant. Fisher noted that the P value for the TAPSE parameter was 0.3003, demonstrating no significance. Fisher stated that the P value for the S` parameter was 0.5331, which did not reach significance.

Table 16. Deviation from the standard size of the right ventricle in individuals from both groups

AF * Basalsize_Groups Crosstabulation					
			Basalsize_Groups		Total
			Normal	Decreased	
AF	Sinus rhythm	Count	13	1	14
		% within AF	92.9%	7.1%	100.0%
	Atrial fibrillation	Count	14	6	20
		% within AF	70.0%	30.0%	100.0%
Total		Count	27	7	34
		% within AF	79.4%	20.6%	100.0%

Fisher reported a P value of 0.1153, indicating that it was not statistically significant

Table 17. Deviation from the standard of RVEDV observed in patients from both groups

RVED_Gender						
Gender			Frequency	Percent	Valid Percent	Cumulative Percent
Female	Valid	Normal	15	51.7	51.7	51.7
		Right ventricular dilatation	14	48.3	48.3	100.0
		Total	29	100.0	100.0	
Male	Valid	Right ventricular dilatation	5	100.0	100.0	100.0

As per Fisher's analysis, the P value was determined to be 0.05572, which is near the threshold of confidence

In general, when examining deviation of RVEDV from the norm in patients with sinus rhythm compared to those with atrial fibrillation, the following conclusion can be drawn: right ventricular dilatation was observed in 42.9% of patients in the sinus rhythm cohort and in 65% of patients with atrial fibrillation (table 18).

The focus of our research was right atrial dilatation, a significant aspect of overall right ventricular remodeling and dysfunction. The standard volume of the right atrium was found to be less than 18 cm² for both genders. Consequently, based on the data analysis, we concluded that right atrial dilatation was identified in 22 of the 34 individuals assessed (64.7%). Within this group, 6 patients were classified as having sinus rhythm (42.9%), while 16 patients were categorized under the atrial fibrillation group (80%) (table 19).

Ultimately, right ventricular dysfunction in individuals with HFpEF is typically linked to pulmonary hypertension, which in turn often plays a role in the emergence of symp-

toms associated with chronic heart failure, including shortness of breath and breathing difficulties, among others. Our objective was to assess the presence and severity of pulmonary hypertension in patients from both cohorts. To achieve this, we evaluated mean pulmonary arterial pressure (mPAP), with a normative value set at <20 mmHg. A mPAP ranging from 20 to 40 mmHg indicated mild pulmonary hypertension; a range of 41 to 55 mmHg was classified as moderate hypertension, while a mPAP exceeding 55 mmHg was deemed severe pulmonary hypertension.

Based on the aforementioned findings, among the 14 patients in the sinus rhythm cohort, only 1 (7.1%) exhibited normal pulmonary pressure, whereas mild hypertension was identified in 13 (92.9%). In the group of 20 patients with atrial fibrillation, pulmonary hypertension was noted in 16 individuals (80%). Within this subgroup, moderate hypertension was observed in 3 cases (15%), and severe hypertension was present in 1 case (5%) (table 20, 21).

Table 18. The deviation of RVEDV from the standard in individuals exhibiting sinus rhythm and those with atrial fibrillation, considered separately.

AF * RVED_Gender Crosstabulation					
			RVED_Gender		Total
			Normal	Decreased	
AF	Sinus rhythm	Count	8	6	14
		% within AF	57.1%	42.9%	100.0%
	Atrial fibrillation	Count	7	13	20
		% within AF	35.0%	65.0%	100.0%
Total		Count	15	19	34
		% within AF	44.1%	55.9%	100.0%

Fisher reported that the P value was 0.1766, indicating a lack of significance

Table 19. The distribution of right atrial dilation among patients in both groups

AF * RAcm_Groups Crosstabulation					
			RAcm_Groups		Total
			Normal	Right atrial dilatation	
AF	Sinus rhythm	Count	8	6	14
		% within AF	57.1%	42.9%	100.0%
	Atrial fibrillation	Count	4	16	20
		% within AF	20.0%	80.0%	100.0%
Total		Count	12	22	34
		% within AF	35.3%	64.7%	100.0%

As stated by Fisher, the P value was 0.03106, indicating a clear level of significance

Table 20. The prevalence of pulmonary hypertension among individuals exhibiting sinus rhythm

AF * Mpap_Groups Crosstabulation			Mpap_Groups				Total
			Normal	Mild	Moderate	Severe	
AF	Sinus rhythm	Count	1	13	0	0	14
		% within AF	7.1%	92.9%	0.0%	0.0%	100.0%

Table 21. The prevalence of pulmonary hypertension among individuals exhibiting atrial fibrillation

AF * Mpap_Groups Crosstabulation			Mpap_Groups				Total
			Normal	Mild	Moderate	Severe	
	Atrial fibrillation	Count	0	16	3	1	20
		% within AF	0.0%	80.0%	15.0%	5.0%	100.0%

DISCUSSION

The involvement of the right ventricle in patients suffering from chronic heart failure with preserved left ventricular function is a significant issue that has garnered considerable interest from the scientific community. Among the various factors contributing to the onset of HFpEF, atrial fibrillation is prominent. Furthermore, it is important to highlight that individuals with HFpEF face an elevated risk of developing AFib, particularly due to the presence of left atrial remodeling and dilation.

The degree to which the right ventricle participates in the pathological mechanisms of HFpEF, the manner in which its dysfunction is reflected through deviations from standard echocardiographic metrics, and the identification of secondary indicators of RV dysfunction, particularly pulmonary hypertension, constituted the primary aims and inquiries of our research. Additionally, we sought to determine whether there were variations in these parameters between two distinct cohorts: individuals with sinus rhythm and those with atrial fibrillation.

To tackle these pertinent questions, we analyzed all significant echocardiographic metrics indicative of right ventricular dysfunction, such as TAPSE, RIMP, S', and FAC. We investigated the occurrence of pulmonary hypertension and utilized the highly sensitive measure of mean pulmonary arterial pressure (mPAP) to address this concern.

Furthermore, we examined critical comorbidities associated with HFpEF, including diastolic dysfunction, elevated left ventricular filling pressure, left atrial enlargement, and left ventricular volumetric index, to assess their prevalence among HFpEF patients and their distribution across different cardiac rhythms. Consequently, our objective was to determine whether there is a significant difference in the aforementioned parameters between patients with HFpEF who present with sinus rhythm and those who present with atrial fibrillation.

CONCLUSION

A total of 34 patients were categorized into two distinct groups. Among these, 14 patients were assigned to

the sinus rhythm group, and 20 to the atrial fibrillation group. Through the analysis of their outcomes, we initially identified that the primary risk factor, which is crucial in the onset of HFpEF, irrespective of heart rhythm characteristics, is arterial hypertension (observed in 100% of cases across both groups) along with a history of valvular heart disease (92.9% in individuals with sinus rhythm and 100% in those with atrial fibrillation). For evident reasons, a history of arrhythmia was presented in 100% of cases among individuals with atrial fibrillation. Notably, Ulrik Sartipy, who examined the occurrence of AF in patients suffering from chronic heart failure with both preserved and reduced left ventricular contractile function, noted that this type of rhythm disorder is found in 21 to 65% of patients with HFpEF, which is significantly higher than the prevalence of the same arrhythmia in patients with HFrEF, which ranges from less than 10% to 50% [x].

Interestingly, age, a primary criterion for diagnosing H2FpEF, significantly contributed to the progression of this condition, irrespective of heart rhythm: advanced age (>60 years) was observed in 92.9% of cases in the sinus rhythm cohort and in 100% of those with atrial fibrillation.

Upon reviewing the diagnostic criteria for H2FpEF, it was also found that severe arterial hypertension, necessitating the administration of two or more antihypertensive medications, was present in 92.9% of individuals exhibiting sinus rhythm and in 100% of those with atrial fibrillation.

The prevalence of pulmonary hypertension (PASP > 35 mmHg as determined by Doppler) and elevated left ventricular filling pressure ($E / e' > 9$ as measured by Doppler) was markedly higher in both cohorts: 85.7% and 78.6% among individuals with sinus rhythm and 80% and 90% among those with atrial fibrillation, respectively (table 22).

We received a noteworthy response regarding the pro-BNP index, revealing that an elevation in this crucial laboratory marker of heart failure was observed in both cohorts; however, it was more pronounced in patients with concurrent atrial fibrillation.

The left ventricular filling pressure was assessed by calculating the ratio of the pulmonary capillary wedge

Table 22. The allocation of diagnostic criteria for H2FpEF among patients in both groups

H2FpEF_Criteria Crosstabulation		H2FpEF_Criteria						Total	
		Excess weight (Heavy) 2 point	Severe hypertension (Hypertensive) 1 point	Atrial Fibrillation (Atrial Fibrillation) 3 point	Pulmonary Hypertension (Pulmonary Hypertension) 1 point	Adult age (Elder) 1 point	Filling Pressure (Filling Pressure) 1 point		
AF	Sinus rhythm	Count	6	13	3	12	13	11	14
		% within AF	42.9%	92.9%	21.4%	85.7%	92.9%	78.6%	
	Atrial fibrillation	Count	7	20	20	16	20	18	20
		% within AF	35.0%	100.0%	100.0%	80.0%	100.0%	90.0%	
Total		Count	13	33	23	28	33	29	34

Percentages and totals are based on respondents

a. Dichotomy group tabulated at value 1

pressure (PCWP) to the average of the transmitral E peak and the mitral annulus e` peaks. Based on PCWP and E/e', an increase in left ventricular filling pressure was identified in 64.3% of patients with sinus rhythm (9 patients) and in 85% of patients with atrial fibrillation (17 patients). Thus, it is evident that PCWP is a vital indicator of rising left ventricular filling pressure, and this parameter is more frequently elevated in individuals with AFib.

The phenomenon of left atrial remodeling was examined meticulously, with the primary focus being the left atrial volumetric index (LAVi), which was ultimately analyzed at the conclusion of the study. In subjects with sinus rhythm, left atrial dilatation and remodeling were identified in 50% of cases, whereas in those with atrial fibrillation, this percentage rose to 94.7% (19 cases). It is also important to highlight that among individuals with atrial fibrillation, moderate to severe instances of left atrial dilatation/remodeling were predominantly noted, while only 35% exhibited mild abnormalities. In contrast, among individuals maintaining sinus rhythm, the occurrence of pronounced dilatation/remodeling was significantly lower, at 14.3%. Consequently, the hypothesis suggesting that left atrial dilatation/remodeling is more pronounced in patients with HFpEF when atrial fibrillation is present has been substantiated.

A noteworthy conclusion regarding this matter is presented in an article by Dipak Kotecha, who examined the prevalence of atrial fibrillation (AF) in patients with heart failure with preserved ejection fraction (HFpEF). In patients exhibiting this arrhythmia, a marked elevation in NT-proBNP levels, significant left atrial enlargement, and pronounced diastolic dysfunction were frequently noted; furthermore, the predominant demographic consisted of older adults [xi]. Consequently, the genuine correlation observed in our research regarding atrial remodeling, elevated left ventricular filling pressure, and the frequency of atrial fibrillation in patients with HFpEF has similarly been recognized by other scholars.

Regarding the echocardiographic indicators of the functional condition of the right ventricle, we concentrated on TAPSE, FAC, S`, RIMP, and the parameter for pulmonary hypertension, specifically mPAP.

Regarding FAC, our findings indicated that this parameter showed the least variation, suggesting RV dysfunction in both groups. Although pathological alterations in FAC were noted in 50% of patients within each group, deviations from the normal range were only identified in one patient from the sinus rhythm group and one patient experiencing atrial fibrillation. Thus, FAC should not be regarded as a specific echocardiographic marker of RV dysfunction in either patient group.

Regarding TAPSE, which primarily assesses the longitudinal contractile function of the right ventricle, we observed notably different results. Specifically, a reduction in TAPSE was found in patients from both groups, with this parameter being predominantly affected in patients with atrial fibrillation (70%). Consequently, evaluating RV contractility along the longitudinal axis and, by extension, calculating TAPSE can be deemed a significant diagnostic criterion for investigating RV dysfunction, particularly in individuals with AFib.

The reduction in the S` parameter did not show significant diagnostic value, as a decrease was observed in only 28.6% of individuals with sinus rhythm and 35.0% with atrial fibrillation.

Regarding RIMP, a parameter that reflects both systolic and diastolic function of the right ventricle, an increase was observed at nearly identical frequencies in both cohorts: 44.4% among individuals with sinus rhythm and 55.6% among those with atrial fibrillation. Notably, the rise in RIMP was similarly observed with almost equivalent frequency, irrespective of whether the patient maintained a normal sinus rhythm or experienced atrial fibrillation: 85.7% and 75%, respectively. This suggests that RIMP serves as a definitive indicator of right ventricular dysfunction, independent of the patient's rhythm type.

The assessment of right ventricular dilatation involved calculating RV basal size and RVEDV. Our findings indicate that the basal size of the right ventricle may remain within the normal limits, irrespective of any impairment in its systolic and/or diastolic function, as evidenced by parameters such as FAC and TAPSE. Consequently, the basal size of the right ventricle does not serve as a reliable indicator of its functional status across demographic groups. Mea-

asuring the right ventricular volume was a considerable challenge, given that normal RVEDV values differ between males and females. Since the majority of participants in our study were female (29 women and 5 men), a thorough gender-based analysis of this parameter was unfeasible. Furthermore, among the female participants, RVEDV values were nearly evenly distributed between normal and pathological ranges, at 51.7% and 48.3%, respectively, whereas all five male participants (100%) exhibited pathological RVEDV values.

Concerning right atrial dilatation, it was relatively straightforward to reach conclusions, as the normative value for this parameter is identical for both men and women (< 18 cm²). Consequently, upon analyzing the data, we found that right atrial dilatation occurs in the majority of HFpEF cases (64.7%) and, among those with atrial fibrillation, it was observed more frequently (80% of cases).

In our investigation of pulmonary hypertension, we observed that the condition developed in nearly all patients, irrespective of rhythm disturbances: 92.9% in sinus rhythm and 100% in atrial fibrillation. Notably, moderate hypertension was more prevalent among individuals with atrial fibrillation (15.0%). In contrast, moderate hypertension was absent in patients with sinus rhythm, with all issues in this group being limited to mild pulmonary hypertension.

In conclusion, our research allows us to establish the following points: 1. The primary factors contributing to HFpEF are arterial hypertension, older age, atrial fibrillation, and acquired valvular diseases. 2. An elevation in left ventricular filling pressure is noted in both patient groups with HFpEF, although this is more closely linked to

the concurrent presence of AFiB. Furthermore, patients with AFib frequently experience issues related to left atrial enlargement/remodeling, which is predominantly indicated by an increase in the LAVi index. 3. Among the echocardiographic indicators of right ventricular dysfunction, including TAPSE, S', RIMP, and FAC, FAC is the least informative, as its reduction is rarely observed, irrespective of the patient's heart rhythm. TAPSE, which assesses RV longitudinal contractile function, shows a decrease in both patient groups, though it is more pronounced in AFiB. S' does not serve as a significant diagnostic marker, given that its reduction is seen in a limited number of patients, regardless of heart rhythm. RIMP stands out as the most informative parameter indicative of RV dysfunction, increasing with nearly equal frequency, irrespective of whether sinus rhythm or atrial fibrillation is present. 4. Right atrial enlargement is a crucial marker of right ventricular dysfunction in patients with HFpEF, particularly in the context of AFiB. 5. Pulmonary hypertension, recognized as a concomitant symptom of right-sided dysfunction, is present in all patients with HFpEF alongside AFiB and is frequently observed in those with sinus rhythm. Additionally, AFiB is more closely associated with mild hypertension compared to sinus rhythm.

BASIC LIMITATIONS

The study's predominant patient demographic was female; therefore, a detailed analysis of the data stratified by gender would be unreliable.

References:

1. Bhatia, R. S., Tu, J. V., Lee, D. S., Austin, P. C., Fang, J., Haouzi, A., Gong, Y., & Liu, P. P. (2006). Outcome of heart failure with preserved ejection fraction in a population-based study. *New England Journal of Medicine*, 355(3), 260–269. <https://doi.org/10.1056/NEJMoa051530>
2. Machino-Ohtsuka, T., Seo, Y., Ishizu, T., Yamamoto, M., Hamada-Harimura, Y., Machino, T., Yamasaki, H., Sekiguchi, Y., Nogami, A., Aonuma, K., & Ieda, M. (2019). Relationships between maintenance of sinus rhythm and clinical outcomes in patients with heart failure with preserved ejection fraction and atrial fibrillation. *Journal of Cardiology*, 74(3), 235–244. <https://doi.org/10.1016/j.jjcc.2019.02.014>
3. Cikes, M., Claggett, B., Shah, A. M., Desai, A. S., Lewis, E. F., Shah, S. J., Anand, I. S., O'Meara, E., Rouleau, J. L., Sweitzer, N. K., Fang, J. C., Saksena, S., Pitt, B., Pfeffer, M. A., & Solomon, S. D. (2018). Atrial fibrillation in heart failure with preserved ejection fraction: The TOPCAT trial. *JACC: Heart Failure*, 6(8), 689–697. <https://doi.org/10.1016/j.jchf.2018.05.005>
4. Sartipy, U., Dahlström, U., Fu, M., & Lund, L. H. (2017). Atrial fibrillation in heart failure with preserved, mid-range, and reduced ejection fraction. *JACC: Heart Failure*, 5(8), 565–574. <https://doi.org/10.1016/j.jchf.2017.05.001>
5. Ben-Arzi, A., Hazanov, E., Ghanim, D., Rozen, G., Marai, I., Grosman-Rimon, L., Kachel, E., Amir, O., & Carasso, S. (2021). Left atrial minimal volume: Association with diastolic dysfunction and heart failure in patients in sinus rhythm or atrial fibrillation with preserved ejection fraction. *BMC Medical Imaging*, 21(1), 76. <https://doi.org/10.1186/s12880-021-00606-3>
6. Lam, C. S. P., Rienstra, M., Tay, W. T., Liu, L. C. Y., Hummel, Y. M., van der Meer, P., de Boer, R. A., Van Gelder, I. C., van Veldhuisen, D. J., Voors, A. A., & Hoendermis, E. S. (2017). Atrial fibrillation in heart failure with preserved ejection fraction: Association with exercise capacity, left ventricular filling pressures, natriuretic peptides, and left atrial volume. *JACC: Heart Failure*, 5(2), 92–98. <https://doi.org/10.1016/j.jchf.2016.10.005>
7. Gorter, T. M., van Melle, J. P., Rienstra, M., Borlaug, B. A., Hummel, Y. M., van Gelder, I. C., Hoendermis, E. S., Voors, A. A., van Veldhuisen, D. J., & Lam, C. S. P. (2018). Right heart dysfunction in heart failure with preserved ejection fraction: The impact of atrial fibrillation. *Journal of Cardiac Failure*, 24(3), 177–185. <https://doi.org/10.1016/j.cardfail.2017.11.005>
8. Kotecha, D., Lam, C. S., van Veldhuisen, D. J., van Gelder, I. C., Voors, A. A., & Rienstra, M. (2016). Heart failure with preserved ejection fraction and atrial fibrillation: Vicious twins. *Journal of the American College of Cardiology*, 68(20), 2217–2228. <https://doi.org/10.1016/j.jacc.2016.08.048>

მარცხენა პარკუჭის შენახული კუმშვადი ფუნქციით მიმდინარე გულის ქრონიკული უკმარისობა პაციენტებში სინუსური რიტმის და წინაგულთა ფიბრილაციის დროს

(რისკ-ფაქტორების, სიმპტომების, ლაბორატორიული მაჩვენებლების და მარჯვენა პარკუჭის დისფუნქციის ექოკარდიოგრაფიული პარამეტრების შედარება)

სერგო კობალავა, მიხეილ წვერავა

საქართველოს დავით აღმაშენებლის სახელობის უნივერსიტეტი (სდასუ),

კლინიკა „ჯერარსის“ კარდიოლოგიური დეპარტამენტი

პასუხისმგებელი პირი: სერგო კობალავა, sergokobalava@gmail.com

DOI: <https://doi.org/10.48412/GTBGS.2026.14-15.87-99>

რეზიუმე გულის ქრონიკული უკმარისობა მარცხენა პარკუჭის შენახული კუმშვადი ფუნქციით, თანამედროვე სამედიცინო საზოგადოებისთვის და უპირატესად კარდიოლოგებისთვის დიდი ინტერესის საგანს წარმოადგენს. მარცხენა პარკუჭის შენახული კუმშვადი ფუნქციით მიმდინარე გულის ქრონიკული უკმარისობის დროს, მნიშვნელოვან ენიჭება იმ რისკ-ფაქტორებს და თანდართულ დაავადებებს, მათ შორის წინაგულთა ფიბრილაციას, რაც ქმნის HFpEF - ის განვითარების საფუძველს. მარჯვენა პარკუჭის ჩართულობა HFpEF პაციენტებში ერთ-ერთი საყურადღებო პრობლემაა. RV - ის დისფუნქციას უკავშირდება არა მარტო კლინიკური გამოვლინების და გულის უკმარისობის ხარისხის სიმძიმე, არამედ დაავადების სამომავლო პროგნოზი და გამოსავალი.

იქიდან გამომდინარე, რომ წინაგულთა ფიბრილაციას საკუთარი, უდიდესი წვლილი შეაქვს არა მარტო HFpEF - ის განვითარებაში, არამედ პროცესში მეორადად RV - ის ჩართულობის საკითხში, საინტერესო იქნება დადგინდეს სიმპტომებს, რისკ-ფაქტორებს, ლაბორატორიული და ინსტრუმენტული კვლევების პასუხებს შორის არსებული ის სავარაუდო განსხვავება, რაც შესაძლებელია არსებობდეს პაციენტებში სინუსური რიტმის და წინაგულთა ფიბრილაციის ფონზე.

მეთოდები: ჩვენ გამოვიკვლიეთ 34 პაციენტი, რომლებსაც დადგინდათ ჰქონდათ გულის ქრონიკული უკმარისობა მარცხენა პარკუჭის შენახული კუმშვადი ფუნქციით. პაციენტები დაგვავით ორ დამოუკიდებელ ჯგუფად გულის რიტმის თავისებურების მიხედვით: სინუსური რიტმი და წინაგულთა ფიბრილაცია. მონაცემები შესწავლილი იყო სათითაოდ ორ განსხვავებულ ჯგუფში და შემდგომში მოხდა აღნიშნული შედეგების შედარება. ჩვენი ინტერესის საგანს წარმოადგენდა ყველა ის ძირითადი რისკ-ფაქტორი და თანდართული დაავადება, რაც საფუძვლად ედო HFpEF - ის განვითარებას, ასევე დიასტოლური დისფუნქციის პარამეტრები, გამოვლენილი პულმონური კაპილარული ჩაჭედვის წნევის (PCWP) და E/e` თანაფარდობის მატეებით, მარცხენა წინაგულის მოცულობითი ინდექსის (LAVi) ზრდით. ჩვენს ასევე შევისწავლეთ მარჯვენა პარკუჭის ფუნქციური მდგომარეობა და პულმონური ჰიპერტენზიის არსებობა და მისი ხარისხი ისეთი ექოკარდიოგრაფიული პარამეტრების გამოყენებით, როგორც არის მარჯვენა პარკუჭის ფრაქციული დამოკლების ფართობი (FAC), მარჯვენა პარკუჭის მოკარდიუმის დამყოლობის ინდექსი (RIMP), სამკარიანი სარქველის რგოლის სისტოლური ექსპურსიის გამოთვლა (TAPSE), სამკარიანი რგოლის ექსპურსიის ქსოვილოვანი S` პიკი, საშუალო პულმონური წნევა (mPAP). ორი ჯგუფის პაციენტებისგან მიღებული მონაცემები საბოლოოდ შევადარეთ ერთმანეთს.

დასკვნა: 1. HFpEF - ის მთავარ ხელშემწყობ ფაქტორთა შორის ყველაზე ხშირად ვლინდება არტერიული ჰიპერტენზია, მოზრდილი ასაკი, წინაგულთა ფიბრილაცია და შეძენილი სარქველოვანი პათოლოგიები. 2. მარცხენა ღრუების ავსების წნევის მატემა შეინიშნება ორივე ჯგუფის პაციენტში HFpEF - ის დროს, თუმცა ეს გარემოება მეტად უფრო ასოცირებულია AFib - ის პარალელური არსებობასთან. 3. მარჯვენა პარკუჭის დისფუნქციის ექოკარდიოგრაფიულ პარამეტრებს შორის, ყველაზე ნაკლებ ინფორმატიული გახლავთ FAC. TAPSE ქვეითდება ორივე ჯგუფის პაციენტში, თუმცა უპირატესად AFib - ის ფონზე. S` არ გახლავთ მნიშვნელოვანი სადიაგნოსტიკო მარკერი, რადგან მისი კლება ვლინდება პაციენტების მცირე პოპულაციაში. RIMP წარმოადგენს RV - ის დისფუნქციის ამსახველ ყველაზე ინფორმატიულ პარამეტრს, რომელიც თითქმის ერთნაირი სიზშირით იზრდება, მიუხედავად სინუსური რიტმისა თუ წინაგულთა ფიბრილაციის არსებობისა. მარჯვენა წინაგულის დილატაცია მარჯვენა ღრუების დისფუნქციის ერთ-ერთი მნიშვნელოვანი მარკერია HFpEF პაციენტებში, განსაკუთრებით AFib - ის არსებობის ფონზე. პულმონური ჰიპერტენზია, როგორც მარჯვენამხრივი დისფუნქციის ერთ-ერთი თანმდევი სიმპტომი ვლინდება ყველა პაციენტში HFpEF დროს AFib - ის არსებობის პარალელურად.

საკვანძო სიტყვები: გულის ქრონიკული უკმარისობა მარცხენა პარკუჭის შენახული კუმშვადი ფუნქციით (HFpEF), სინუსური რიტმი, წინაგულთა ფიბრილაცია, მარჯვენა პარკუჭის დისფუნქცია, დიასტოლური დისფუნქცია, მარცხენა წინაგულის მოცულობითი ინდექსი (LAVi), პულმონური ჰიპერტენზია.

PERINDOPRIL IN PATIENTS WITH HEART FAILURE REDUCED EJECTION FRACTION - HFrEF

Natia Nazghaidze¹, Solomon Zeikidze¹, Archil Chukhrukidze³,
Zviad Kereselidze³, Shalva Petriashvili²

¹David Agmashenebeli University of Georgia, ²East-West University, ³Tbilisi Heart Center

Contact person: Natia Nazghaidze, natia.nazghaidze@yahoo.com

DOI: <https://doi.org/10.48412/GTBGS.2026.14-15.100-106>

Rezume

Heart failure (HF) has been known since ancient times. The first cases were described in Egypt, and later Avicenna and other leading historical figures discussed this pathology. William Harvey made a significant contribution to defining the physiological foundations of heart function and blood circulation, and in the 20th century, E.H. Starling formulated the "law of the heart", which became the basis for the hemodynamic understanding of heart function.

HF is a growing global problem, the second most common cardiovascular disease, and the leading cause of hospitalization. Properly selected drug treatment for patients is the cornerstone of the management of this nosology. Studies show that after 6 months of drug discontinuation, most patients relapse, contractile function decreases, and hospitalization is required. This emphasizes the importance of properly selected and continuous therapy.

The sympathetic nervous system and renin-angiotensin-aldosterone system (RAAS) play a leading role in heart failure. Their activation causes hemodynamic disturbances, cardiac remodeling, and chronic dysfunction.

According to the classification, heart failure is distinguished according to the ejection fraction:

- HFrEF – reduced (EF < 40%);
- HFmrEF – moderately reduced (EF 41–49%);
- HFpEF – preserved (EF ≥ 50%).

Heart failure with reduced ejection fraction is characterized by frequent exacerbations and high mortality. The main goals of treatment are: reducing mortality, reducing hospitalizations, and improving quality of life.

According to the therapeutic standard, first-line medications for HFrEF include ACE inhibitors, ARNI, beta-blockers, spironolactone, SGLT2 inhibitors, and diuretics.

Perindopril – an ACE inhibitor characterized by long-lasting action and relatively low side effects (e.g., dry cough). It has proven efficacy in various cardiovascular nosologies in clinical trials: ASCOT, EUROPA, PROGRESS, PREAMI, and ADVANCE.

However, it is important to clarify that, to date, no specific, high-quality study has demonstrated the direct efficacy of perindopril in patients with HFrEF. Analysis of the available data suggests a potential benefit, but targeted studies are necessary to meet evidence-based medicine standards.

Key words: Heart Failure; Reduced Ejection Fraction; HFrEF

HISTORICAL FACTS

The oldest known case of decompensated heart failure is a 3,500-year-old Egyptian nobleman named Nebiri, discovered in a looted tomb in the Valley of the Queens by Egyptologist Ernesto Schiaparelli. Now housed in the Egyptian Museum in Turin, Nebiri lived during the reign of 18th Dynasty pharaoh Thutmose III. Pathologist Andreas Nerlich examined the lung tissue, finding evidence of pulmonary edema presumably due to heart failure, after ruling out other causes such as tuberculosis, granulomas, or mycobacterial infections [1].

The medieval Arab scholar Ibn Sina, known in the West as Avicenna (980–1037), was renowned as a specialist in heart disease. His treatise *Kitab al-Adviyt-al-Qalbiye*, or "Book of Medicines for the Heart", discusses the treatment of dyspnea, palpitations, and syncope [2]. The turning point came in 1628, when William Harvey clearly described the circulation of blood and laid the foundation for understanding the hemodynamic abnormalities in heart

failure. A few years later, descriptions of heart failure caused by tamponade and mitral stenosis became available. In the mid-18th century, Lancisi noted that valvular regurgitation causes ventricular dilatation, but he noted that the ventricular cavity does not dilate in aortic stenosis. He also hypothesized that dilation weakens the heart [3].

The Romans were known to use digitalis as a "cure." Bloodletting and leeches were used for centuries. In 1785, William Withering published his work on the benefits of digitalis [4]. In the 19th and early 20th centuries, Southey's tubes were inserted into swollen limbs to drain fluid in heart failure. The discovery of X-rays by Roentgen and of electrocardiography by Einthoven in the 1890s improved understanding of heart failure. Later, echocardiography, cardiac catheterization, and nuclear medicine advanced diagnostic and investigative capabilities. By the 20th century, distinguishing types of cardiac enlargement became especially important. In 1918, E.H. Starling published his "Law of the Heart." His demonstration that increasing diastolic volume strengthens the heart surprised many, as

it went against the 19th-century view that dilation weakened the heart [5].

The study conducted in India was significant; it contributed to a new understanding and treatment of heart failure, leading to its recognition as a neuroendocrine disease rather than a heart disease. As a result, angiotensin-converting enzyme inhibitors (ACE inhibitors) and beta-blockers were successfully introduced for the treatment of heart failure. ACE inhibitors reduce the risk of death and hospitalization in all patients with heart failure who have a reduced ejection fraction (HFrEF), regardless of the severity of symptoms [6].

Heart failure is the final stage of most heart diseases and is one of the main causes of morbidity and mortality. In clinical practice, heart failure presents with symptoms such as shortness of breath, fatigue, and fluid retention, leading to frequent hospitalizations. As the population ages, the prevalence of heart failure will continue to rise, further straining healthcare systems through increased morbidity, mortality, and healthcare costs [7].

THE ESSENCE OF HEART FAILURE: EPIDEMIOLOGY, PATHOGENESIS, AND DEVELOPMENT MECHANISMS

The epidemiology of heart failure has been a subject of interest since 1997, when it was called a new pandemic. Today, the total number of patients is increasing alongside the world's population. At present, 64.3 million patients have been diagnosed with heart failure. In developed countries, 1-2% of adults suffer from heart failure, and this figure increases to 11.8% over the age of 65 [8].

By 2021, 6 million people in the United States had heart failure. It is the most common cause of hospitalization in people over 40 [9]. 40% of patients will be hospitalized 4 or more times in their lifetimes. The risk of rehospitalization is high, and mortality within 30 days is significant. In Europe [10], 1-2% of the population has heart failure, and the rate rises to 10-15% for those over 70.

Frequent and prolonged hospitalization imposes a significant financial burden on the country and the patient. It also causes stress for the patient and their family or caregiver.

With proper, timely treatment, it is possible to prevent and delay the development of heart failure and reduce hospitalization frequency.

Heart failure is not a specific pathological diagnosis but rather a clinical syndrome characterized by certain symptoms (shortness of breath, easy fatigue, etc.) and signs (swelling of the lower extremities, wet wheezing in the lungs, etc.). The pathogenesis of the disease involves structural and/or functional damage to the heart, leading to increased intracardiac pressures and/or decreased cardiac output. Heart failure most often occurs as the final stage of various cardiovascular nosologies. It is necessary to determine the cause of heart failure because the underlying disease dictates the appropriate course of treatment [11].

Heart failure is a progressive disease. Any acute damage to the heart's structure - whether caused by genetic mutation, infiltration of cardiac tissue, ischemia, valvular

disease, myocarditis, or acute myocardial injury - can trigger compensatory mechanisms that, after exhaustion, lead to maladaptation. In the early stages of heart failure, several compensatory mechanisms attempt to maintain cardiac output and meet systemic demands. Chronic activation of the sympathetic nervous system leads to decreased beta-receptor sensitivity and reduced adrenaline stores. This leads to alterations in myocyte regeneration, myocardial hypertrophy, and myocardial hypercontractility [12].

Increased sympathetic stimulation also activates the renin-angiotensin-aldosterone system (RAAS). This causes systemic vasoconstriction and sodium retention. RAAS releases angiotensin II, which increases myocardial cell hypertrophy and interstitial fibrosis. These changes promote myocardial remodeling [13].

The reduction in cardiac output stimulates the neuroendocrine system to release epinephrine, norepinephrine, endothelin-1 (ET-1), and vasopressin. These mediators cause vasoconstriction, thereby increasing afterload. Cyclic adenosine monophosphate (cAMP) increases, which leads to an increase in cytosolic calcium in myocytes. This increases myocardial contractility and further impairs myocardial relaxation. The increase in afterload and myocardial contractility, together with the impairment of myocardial relaxation, increases myocardial oxygen demand. This paradoxical need for increased cardiac output to meet myocardial demand ultimately leads to myocardial cell death and apoptosis. As apoptosis continues, the reduction in cardiac output with increased demand leads to a prolonged cycle of increased neurohumoral stimulation and maladaptive hemodynamic and myocardial responses [14].

THE RENIN-ANGIOTENSIN-ALDOSTERONE SYSTEM (RAAS) AND ITS ROLE IN THE PATHOGENESIS OF HFrEF

The renin-angiotensin-aldosterone system (RAAS) is an important mediator of cardiac, vascular, and renal physiology by regulating vascular tone and salt and water homeostasis. In addition to its basic physiological functions, the RAAS plays an important role in the pathophysiology of hypertension, heart failure, other cardiovascular diseases, and renal disease [15]. Blockade of renin-angiotensin-aldosterone hyperactivation with various medications improves the outcome of various cardiovascular and renal diseases [16].

Juxtaglomerular cells in the afferent arterioles of the kidney contain prorenin. Activation of juxtaglomerular cells results in the breakdown of prorenin to renin. Activation of prorenin occurs in the kidney by enzymes such as proconvertase 1 and cathepsin B. Mature renin is stored in the granules of juxtaglomerular cells and is released into the circulation by four main stimuli [17]:

1. Changes in renal perfusion, which are sensed by pressure transduction mechanisms in the afferent arterioles (reflecting stretch from mechanoreceptors in the arteriolar wall);

2. Sodium and chloride delivery to the distal convoluted tubule, which is perceived by the macula densa;
3. Increased beta-sympathetic flow, which acts through beta-1 adrenergic receptors, especially in the upright position;
4. Negative feedback from humoral factors such as angiotensin I, potassium (renin release increases with hypokalemia and decreases with hyperkalemia), and ANP (atrial natriuretic peptide) [18].

Accordingly, conditions that reduce renal perfusion and trigger tubular sodium retention stimulate renin release. The half-life of renin activity in the circulation is 10–15 minutes [19].

Angiotensinogen

This molecule is primarily synthesized and constitutively secreted by the liver. Renin cleaves the N-terminus of angiotensinogen, forming angiotensin I.

Angiotensin I

This peptide lacks known biological activity.

Angiotensin-converting enzyme (ACE)

This enzyme is expressed on the plasma membranes of vascular endothelial cells, mainly in the pulmonary circulation. It cleaves the C-terminal 2 amino acids of angiotensin I to form the peptide angiotensin II.

Angiotensin II

ACE produces angiotensin II by cleaving 2 amino acids from the C-terminus of angiotensin I. Angiotensin II is the principal mediator of the physiological effects of the renin-angiotensin-aldosterone system, including blood pressure, fluid volume regulation, and aldosterone secretion. The half-life of angiotensin II in the circulation is very short, less than 60 seconds. It is cleaved by peptidases to angiotensin III and IV. Angiotensin III has 100% of the aldosterone-stimulating effect of angiotensin II but only 40% of the pressor effects.

The physiological effects of angiotensin II on the regulation of extracellular volume and blood pressure are mediated through 5 pathways:

1. Vasoconstriction by contraction of vascular smooth muscle in arterioles [20];
2. Aldosterone secretion from the adrenal cortex into the zona glomerulosa, via transcription of CYP11B2 (aldosterone synthase);
3. Increase sodium reabsorption by increasing the activity of the Na-H antiporter in the proximal convoluted tubule;
4. Increase sympathetic outflow from the central nervous system;
5. Release of vasopressin from the hypothalamus [21].

Angiotensin II is also involved in many pathophysiological mechanisms and is known to induce oxidative stress, vascular smooth muscle contraction, endothelial dysfunction, fibrosis, and hypertrophic, antiapoptotic, and promi-

togenic effects. Through these effects, angiotensin II plays a fundamental role in the pathogenesis of hypertension, atherosclerotic disease, heart failure, and renal disease [22].

The most important role in the pathogenic mechanism of heart failure with reduced ejection fraction is played by pathological activation of the renin-angiotensin-aldosterone system, which leads to fluid retention, remodeling of the heart muscle, activation of the sympathetic nervous system, etc. Accordingly, it is not surprising that in both European and American heart failure guidelines [23], RAAS system inhibitors, in particular angiotensin-converting enzyme inhibitors (hereinafter ACE) are the foundation of treatment and first-line drugs, followed by β -blockers, mineralocorticoid antagonists, and SGLT2 inhibitors.

In 1987, the CONSENSUS-I trial first demonstrated a clear survival benefit of angiotensin-converting enzyme inhibitors in severe heart failure [13].

CLASSIFICATION AND TREATMENT PRINCIPLES OF HEART FAILURE

Heart failure is classified by various parameters; the most important is the division based on contractile function. Based on ejection fraction, heart failure is classified as reduced (<40%), moderate (41–49%), or preserved (>50%). The percentage distribution is as follows: 60% HFrEF, 24% HFmrEF, and 16% HFpEF. In Western and developed countries, the most common causes of heart failure are coronary artery disease and arterial hypertension. They are followed by valvular pathologies, arrhythmias, cardiomyopathies, and other conditions. In addition to the typical division, the American Heart Association and Cardiology Association suggest a division into stages:

Stage A: At risk of heart failure. There are no current or past symptoms, structural heart disease, or elevated cardiac biomarkers, but there are risk factors. Risk factors include hypertension, diabetes, metabolic syndrome, cardiotoxic medications, or having a genetic variant of cardiomyopathy.

Stage B: Pre-heart failure. Patients do not have signs or symptoms of heart failure but have risk factors and structural heart disease, evidence of increased filling pressures (invasively or noninvasively assessed), or persistently elevated cardiac markers in the absence of other causes of elevated markers, such as chronic kidney disease or myocarditis.

Stage C: Symptomatic heart failure stage. Patients with a current or past history of heart failure symptoms.

Stage D: Advanced heart failure. Patients with refractory symptoms that interfere with daily life or have repeated hospitalizations despite targeted guideline-based medical therapy [24].

Heart failure is classified into different severity categories based on clinical manifestations and natriuretic peptide levels. For example, one person with a 35% contractility may not be able to function at home, while another may be able to perform daily activities without symptoms. Clinical history, examination, and laboratory analysis de-

termine the clinical status and physiological level of left ventricular failure, allowing comparison with baseline parameters after treatment and the level of improvement.

The diagnosis of heart failure requires the presence of specific symptoms, signs, and evidence of cardiac dysfunction.

Heart failure with reduced ejection fraction is diagnosed by a combination of symptoms and signs, along with echocardiographic evidence of reduced ejection fraction. The natriuretic peptide NT-proBNP is an important tool for diagnosing the disease and assessing its severity, prognosis, and treatment effectiveness.

Medical treatment of heart failure is the cornerstone of the management of this disease. It must be included before and after the use of any instrumental method. The goals of treatment can be divided into three large groups:

1. Reducing mortality
2. Reduction in recurrent hospitalizations due to worsening heart failure
3. Improvement of clinical status, functional capacity, and quality of life.

There are various methods for assessing the effectiveness of drug treatment in HFrEF, including the increase in ejection fraction and the reduction in the size of the heart chambers, as well as the determination and normalization of intracardiac pressures, which are markers of effective treatment and correlate with both the decrease in NT-proBNP and the improvement in functional status. Determination of the NT-pro-BNP index is recommended for the diagnosis of HFrEF, which is responsible for determining the severity of the disease, and, on the background of treatment, for assessing the level of functional and prognostic improvement, as well as the need for treatment intensification [11].

The primary markers of treatment effectiveness for the patient are symptom reduction and improvement in quality of life, as measured by KCCQ questionnaire scores and NYHA functional class.

It is important to note that only in the case of heart failure with reduced ejection fraction does evidence-based medicine suggest therapeutic treatment that improves prognosis, morbidity, and mortality. The guideline calls for treating patients with moderately reduced contractility as if they had a reduced fraction [25]. Accordingly, the evidence for treating reduced ejection fraction extends to the second large group, which accounts for 2/3 of heart failure cases.

Modulation of the RAAS and sympathetic nervous systems with angiotensin-converting enzyme inhibitors (ACE-I) or angiotensin receptor neprilysin inhibitor (ARNI), beta-blockers, and mineralocorticoid receptor antagonists (MRAs) improves survival, reduces the risk of hospitalization for heart failure, and reduces symptoms in patients with heart failure with HFrEF. These drugs are the mainstay of pharmacotherapy for patients with HFrEF. The ACE-I/ARNI, beta-blocker, and MRA triad is recommended as the main therapy for these patients, and should be titrated to

the doses used in clinical trials (or to the maximum tolerated dose if this is not possible).

The sodium-glucose co-transporter 2 (SGLT2) inhibitors dapagliflozin and empagliflozin, added to ACE-I/ARNI/beta-blocker/MRA therapy, reduce the risk of cardiovascular death and worsening of heart failure in patients with HFrEF.

Dapagliflozin or empagliflozin is recommended for all patients with HFrEF who are already receiving an ACE-I/ARNI, a beta-blocker, and an MRA, regardless of diabetes status [11]. (Figure 1).

ACE inhibitors are recommended as first-line medications for patients with heart failure with reduced ejection fraction to reduce the risk of heart failure hospitalization and death.

In 1995, the European Society of Cardiology published guidelines for the diagnosis of heart failure. ACE inhibitors have been consistently proven in numerous studies to reduce mortality. They are the drugs of choice for the entire spectrum of cardiovascular diseases - heart failure, myocardial infarction, stroke, arterial hypertension, diabetes mellitus, stable angina, etc.

The list of angiotensin-converting enzyme inhibitors included in the European Society of Cardiology's heart failure guidelines has not changed for many years; it is as follows: captopril, enalapril, lisinopril, ramipril,trandolapril.

Perindopril

A prominent representative of ACE inhibitors is perindopril. Perindopril was developed in 1980 and received its first patent in 1981, with 4 additional patents since 1988. It has been used in clinical practice for 35 years. The most common side effect of ACE inhibitors - dry cough induced by bradykinin accumulation - is least common with perindopril. The incidence of cough associated with ACE inhibitors is as follows: perindopril - 5.4%, ramipril - 6.89%, and lisinopril - 8.82%. The overall incidence of dry cough when using three different ACE inhibitors was 7.0% [26].

Perindopril - a non-sulfhydryl group angiotensin-converting enzyme inhibitor, like enalapril, is a prodrug and is rapidly metabolized in the liver to the active substance perindoprilat. It is characterized by potent, long-lasting ACE inhibition, a 24-hour duration of action [27], and its effectiveness has been confirmed by numerous large-scale studies in various cardiovascular diseases, such as:

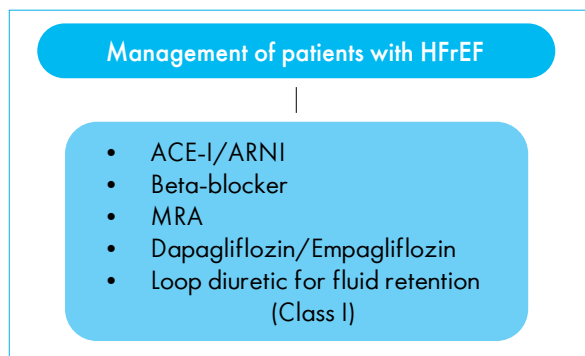


Figure 1. Algorithm for medical management of patients with HFrEF

1. **ASCOT11 -Anglo-Scandinavian Cardiac Outcomes Trial** [28]. 19,257 patients were included in the study, with a mean follow-up of 5.4 years; the aim of the study was to determine the effectiveness of treatment with a new combination of a calcium antagonist and an ACE inhibitor compared with an older combination of a beta-blocker and a diuretic; the study demonstrated the proven superiority of perindopril-amlodipine over the combination of atenolol-hydrochlorothiazide in arterial hypertension.
 2. **EUROPA12 -The EUROpean trial on reduction of Cardiac Events with Perindopril in Stable Coronary Artery disease** [29]. 12,218 patients were included in the study; mean follow-up period 3.7 years; Inclusion criteria and study cohort: myocardial infarction, PCI/CABG >6 months, angiographically determined stenosis ≥70%, patients with chest pain and a positive stress test; The aim of the study was to compare the efficacy of perindopril with placebo in groups of patients with coronary artery disease; The study found a reduced mortality compared to placebo in the perindopril group in stable coronary angina (figure 2).
 3. **PROGRESS13 Perindopril protection Against Recurrent Stroke Study** [30]. 6105 patients from 172 centers worldwide participated in the study. The study design compared placebo and active treatment (perindopril + indapamide) in patients with stroke or transient ischemic attack, with the primary endpoint being the incidence of recurrent stroke in these groups; over a 4-year follow-up period, recurrent neurological events occurred in 307 (10%) patients in the active treatment group and 420 (14%) patients in the placebo group (95% confidence interval 17-38), $P < 0.0001$. Active treatment also reduced the risk of MACE [26% (16-34)], non-fatal myocardial infarction [38% (14-55)], severe cognitive impairment [19% (4-32)], stroke-associated dementia [34% (3-55)], and disability [18% (8-28)]. The perindopril-indapamide combination reduced blood pressure by 12/5 mmHg and stroke risk by 43%.
 4. **PREAMI28 Perindopril and Re-modelling in Elderly with Acute Myocardial Infarction study** [30]. 1252 patients participated, observation period 1 year, patients over 65 years of age with acute myocardial infarction participated in the study; primary endpoints were obtained - reduction in mortality, morbidity, hospitalization in the post-myocardial infarction period in the perindopril group, compared with placebo.
 5. **ADVANCE6 Action in Diabetes and Vascular Disease: Preterax and Diamicon MR Controlled Evaluation Trial** [31]. 11,140 patients participated; primary endpoints were reduced mortality, morbidity, type II diabetes mellitus, and arterial hypertension.
- According to Georgian statistics for 2021-2022 (pharmacy.moh.gov.ge), perindopril is the undisputed leader among imported ACE inhibitors, with 15% more perindopril and its combinations imported in 2021 than enalapril and its combinations (which ranked second in terms of quantity imported), and 31% more in 2022. This indicates the high frequency of use of perindopril in the country compared to other ACE inhibitors. In addition, perindopril is included on the state list of free medicines, further increasing its availability and prescribing [32] (Picture 3).
- Based on all of the above, the role of perindopril in the management of cardiovascular diseases is clear, and it is worth noting its particular popularity in Georgia, driven by its effectiveness, price, and availability.
- However, one issue remains open in the evidence for perindopril. To date, no study has specifically investigated its efficacy in patients with heart failure and reduced ejection fraction, and this is a very large cohort. As noted above, heart failure with reduced ejection fraction is a syndromic disease and is a complication of other cardiovascular diseases. The efficacy of perindopril in this cardiovascular disease suggests that, in appropriate study settings, the drug should reduce the primary endpoints—mortality, morbidity, and hospitalization—in patients with HFrEF.

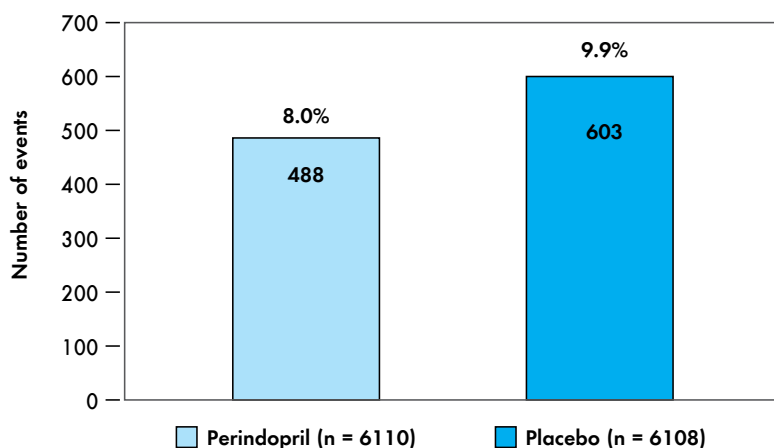


Figure 2. EUROPA: primary endpoint (cardiovascular death, MI, or cardiac arrest). RRR: 20% [95% CI, 9-29].

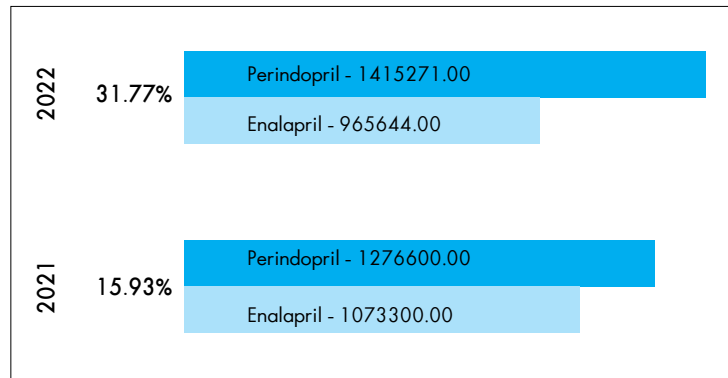


Figure 3. Imported medicines 2020-2022 years

DISCUSSION

Chronic heart failure has not lost its relevance for years; moreover, it is increasingly becoming a subject of research, it is a growing nosology, the second most common among cardiovascular diseases, and the first in terms of hospitalization. Properly selected drug treatment for patients is the cornerstone of managing this nosology. Studies show that in the event of discontinuation of drugs for 6 months, most patients developed a relapse, decreased contractile function, and required inpatient treatment [33]. That is why the 2021 European and 2022 American guidelines for heart failure urge us to continue

the medications that led to improvement, even in cases of heart failure that have improved with treatment [14, 24].

Heart failure requires increased awareness among the patient, their family members, and those around them, and the doctor is obliged to develop an appropriate medication regimen for each patient after making a timely, accurate diagnosis to achieve the best possible results.

Chronic heart failure is often associated with other non-cardiological diseases [34] - chronic kidney failure, chronic lung diseases, anemia, etc. - therefore, collaboration between cardiologists and doctors from other fields is very important in the management of heart failure.

References:

1. Bianucci, R., Loynes, R. D., Sutherland, M. L., Lallo, R., Kay, G. L., Froesch, P., Pallen, M. J., Charlier, P., & Nerlich, A. G. (2016). Forensic analysis reveals acute decompensation of chronic heart failure in a 3500-year-old Egyptian dignitary. *Journal of Forensic Sciences*, 61, 1378–1381.
2. Chamsi-Pasha, M. A. R., & Chamsi-Pasha, H. (2014). Avicenna's contribution to cardiology. *Avicenna Journal of Medicine*, 4, 9–12.
3. Harvey, W. (1628). *Exercitatio anatomica de motu cordis et sanguinis in animalibus*. William Fitzer.
4. Davis, R. C., Hobbs, F. D., & Lip, G. Y. (2000). ABC of heart failure: History and epidemiology. *BMJ*, 320(7226), 39–42.
5. Starling, E. H. (1918). *The Linacre lecture on the law of the heart*. Longmans Green & Co.
6. Garg, R., & Yusuf, S. (1995). Overview of randomized trials of angiotensin converting enzyme inhibitors on mortality and morbidity in patients with heart failure. *JAMA*, 273, 1450–1456.
7. Ferrari, R., Balla, C., & Fucili, A. (2016). Heart failure: An historical perspective. *European Heart Journal Supplements*, 18(Suppl G), G3–G10.
8. Groenewegen, A., Rutten, F. H., Mosterd, A., & Hoes, A. W. (2020). Epidemiology of heart failure. *European Journal of Heart Failure*, 22(8), 1342–1356. <https://doi.org/10.1002/ehf.1858>
9. Roger, V. L. (2021). Epidemiology of heart failure: A contemporary perspective. *Circulation Research*, 128(10), 1421–1434. <https://doi.org/10.1161/CIRCRESAHA.121.318172>
10. Heart failure is one of the leading causes of hospitalizations — but it doesn't have to be - <https://www.statnews.com/sponsor/2019/10/21/heart-failure-one-of-the-leading-causes-f-hospitalizations-%e2%81%a0but-it-doesnt-have-to-be>
11. McDonagh, T. A., Metra, M., Adamo, M., Gardner, R. S., Baumbach, A., Böhm, M., Burri, H., Butler, J., Čelutkienė, J., Chioncel, O., Cleland, J. G. F., et al. (2021). 2021 ESC Guidelines for the diagnosis and treatment of acute and chronic heart failure. *European Heart Journal*, 42(36), 3599–3726. <https://doi.org/10.1093/eurheartj/ehab368>
12. Opie, L. H., Commerford, P. J., Gersh, B. J., & Pfeffer, M. A. (2006). Controversies in ventricular remodeling. *The Lancet*, 367(9507), 356–367.
13. CONSENSUS Trial Study Group. (1987). Effects of enalapril on mortality in severe congestive heart failure. *New England Journal of Medicine*, 316(23), 1429–1435.
14. Kemp, C. D., & Conte, J. V. (2012). The pathophysiology of heart failure. *Cardiovascular Pathology*, 21(5), 365–371.
15. Engeli, S., Negrel, R., & Sharma, A. M. (2000). Physiology and pathophysiology of the adipose tissue renin-angiotensin system. *Hypertension*, 35(6), 1270–1277.
16. Atlas, S. A. (2007). The renin-angiotensin aldosterone system: Pathophysiological role and pharmacologic inhibition. *Journal of Managed Care Pharmacy*, 13(8 Suppl B), 9–20.
17. Reudelhuber, T. L., Ramla, D., Chiu, L., Mercure, C., & Seidah, N. G. (1994). Proteolytic processing of human prorenin. *Kidney International*, 46(6), 1522–1524.

18. Schweda, F., Friis, U., Wagner, C., Skott, O., & Kurtz, A. (2007). Renin release. *Physiology*, 22, 310–319.
19. Skrabal, F. (1974). Half-life of plasma renin activity in normal subjects and in malignant hypertension. *Klinische Wochenschrift*, 52(24), 1173–1174.
20. Harrison-Bernard, L. M. (2009). The renal renin-angiotensin system. *Advances in Physiology Education*, 33(4), 270–274.
21. Cano, A., Miller, R. T., Alpern, R. J., & Preisig, P. A. (1994). Angiotensin II stimulation of Na-H antiporter activity. *American Journal of Physiology*, 266, C1603–C1608.
22. Schieffer, B., Schieffer, E., Hilfiker-Kleiner, D., Hilfiker, A., Kovanen, P. T., Kaartinen, M., Nussberger, J., Harringer, W., & Drexler, H. (2000). Expression of angiotensin II and interleukin 6 in plaques. *Circulation*, 101(12), 1372–1378.
23. Jia, G., Aroor, A. R., Hill, M. A., & Sowers, J. R. (2018). Role of RAAS in cardiovascular fibrosis. *Hypertension*, 72(3), 537–548. <https://doi.org/10.1161/HYPERTENSIONAHA.118.11065>.
24. Heidenreich, P. A., Bozkurt, B., Aguilar, D., Allen, L. A., Byun, J. J., Colvin, M. M., Deswal, A., Drazner, M. H., Dunlay, S. M., et al. (2022). 2022 AHA/ACC/HFSA guideline for heart failure. *Circulation*, 145(18), e895–e1032.
25. Schwinger, R. H. G. (2021). Pathophysiology of heart failure. *Cardiovascular Diagnosis and Therapy*, 11(1), 263–276.
26. Nazir, A., Sheikh, F. M., Aslam, S., & Javaid, U. (2016). ACE inhibitors comparison. *The Professional Medical Journal*, 23(9), 1145–1148.
27. Todd, P. A., & Fitton, A. (1991). Perindopril: Pharmacological review. *Drugs*, 42(1), 90–114.
28. <https://www.acc.org/Latest-in-Cardiology/Clinical-Trials/2010/11/17/12/05/ASCOT--Blood-Pressure-Arm>
29. Fox, K. M., Henderson, J. R., Bertrand, M. E., Ferrari, R., Remme, W. J., & Simons, M. L. (1998). EUROPE trial. *European Heart Journal*, 19(Suppl J), J52–J55.
30. Chalmers, J., & MacMahon, S. (2003). PROGRESS study interpretation. *Journal of Hypertension*, 21, S9–S14.
31. ADVANCE Management Committee. (2001). Study design of ADVANCE. *Diabetologia*, 44(9), 1118–1120.
32. <https://pharmacy.moh.gov.ge>
33. Halliday, B. P., Wassall, R., Lota, A. S., Khalique, Z., Gregson, J., Newsome, S., Jackson, R., & Prasad, S. K. (2019). TRED-HF trial. *The Lancet*, 393(10166), 61–73.
34. van der Wal, H. H., van Deursen, V. M., van der Meer, P., & Voors, A. A. (2017). Comorbidities in heart failure. *Handbook of Experimental Pharmacology*, 243, 35–66.

პერინდოპრილი გულის უკმარისობის მქონე პაციენტებში შემცირებული განდევნის ფრაქციით - HFrEF

ნათია ნაზღაიძე¹, სოლომონ ზეიკიძე¹, არჩილ ჩუხრაძე³,
ზვიად კერესელიძე³, შალვა პეტრიაშვილი²

¹საქართველოს დავით აღმაშენებლის სახ. უნივერსიტეტი, ²ალმოსავლეთ-დასავლეთ უნივერსიტეტი,
³თბილისის გულის ცენტრი

პასუხისმგებელი პირი: ნათია ნაზღაიძე, natia.nazghaidze@yahoo.com

DOI: <https://doi.org/10.48412/GTBGS.2026.14-15.100-106>

რეზიუმე გულის უკმარისობა (გუ) მზარდი გლობალური პრობლემაა, გულ-სისხლძარღვთა დაავადებებს შორის სიხშირით მეორე ადგილზეა და ჰოსპიტალიზაციის მთავარ მიზეზს წარმოადგენს. პაციენტებისთვის სწორად შერჩეული მედიკამენტური მკურნალობა ამ ნოზოლოგიის მართვის ქვაკუთხედი — კვლევები აჩვენებს, რომ მედიკამენტების მიღების შეწყვეტიდან რ თვის შემდეგ პაციენტთა უმრავლესობაში ვლინდება რეციდივი, მცირდება კუმულირებული ფუნქცია, და საჭირო ხდება ჰოსპიტალიზაცია. ეს, კიდევ ერთხელ, ხაზს უსვამს მართებულად შერჩეული და უწყვეტი თერაპიის მნიშვნელობას. სიმპტომური ნერვული და რენინ-ანგიოტენზინ-ალდოსტერონის სისტემები წამყვან როლს ასრულებენ გუ-ს პათოგენეზში, მათი აქტივაცია ხელს უწყობს ჰემოდინამიკურ დარღვევებს, გულის რემოდელირებას და ქრონიკულ დისფუნქციას. კლასიფიკაციის მიხედვით, გულის უკმარისობა განდევნის ფრაქციის მიხედვით იყოფა: HFrEF - შემცირებული (EF < 40%); HFmrEF - ზომიერად შემცირებული (EF 41–49%); HFpEF - შენარჩუნებული (EF ≥ 50%). შემცირებული განდევნის ფრაქციის დროს გულის უკმარისობა ხასიათდება ხშირი გამწვავებებით და მაღალი სიკვდილობით. მკურნალობის მთავარი მიზნებია: სიკვდილობის შემცირება, ჰოსპიტალიზაციების შემცირება და ცხოვრების ხარისხის გაუმჯობესება. თერაპიული სტანდარტის თანახმად, HFrEF-ის პირველი რიგის მედიკამენტებს მიეკუთვნება აგვ ინჰიბიტორები, ARNI, ბეტა-ბლოკერებთან, სპირონოლაქტონთან, SGLT2 ინჰიბიტორებთან და დიურეტიკებთან ერთად. პერინდოპრილი — აგვ ინჰიბიტორი, რომელიც ხასიათდება ხანგრძლივი მოქმედებით და შედარებით დაბალი გვერდითი მოვლენებით (მაგ., მშრალი ხველა). მის ეფექტურობა დამტკიცებულია კლინიკური კვლევებში: ASCOT, EUROPA, PROGRESS, PREAMI, ADVANCE. აღსანიშნავია, რომ დღეის მდგომარეობით არ არსებობს სპეციფიკური, მაღალი ხარისხის კვლევა, რომელიც შეაფასებდა პერინდოპრილის პირდაპირ ეფექტურობას მხოლოდ HFrEF-ის მქონე პაციენტებში. არსებული მონაცემების ანალიზი მიუთითებს მის პოტენციურ სარგებელზე ამ ჯგუფშიც, თუმცა, მტკიცებულებებზე დაფუძნებული მედიცინის მოთხოვნების გათვალისწინებით, საჭიროა მიზნობრივი კვლევები.

საკვანძო სიტყვები: გულის უკმარისობა; შემცირებული განდევნის ფრაქცია; HFrEF

HEART FAILURE AND ISCHEMIA

George Shaburishvili¹, Nikoloz Shaburishvili², Solomon Zeikidze¹

¹David Agmashenebeli University of Georgia, ²Ilia State University, Tbilisi, Georgia

Contact person: George Shaburishvili, gigishab94@gmail.com

DOI: <https://doi.org/10.48412/GTBGS.2026.14-15.107-115>

Rezume | Heart failure is a complex and progressive syndrome. It is marked by the heart's inability to pump enough blood to meet the body's metabolic needs. Ischemia, a condition where blood and oxygen supply are restricted, is a major factor in the development and worsening of heart failure. Over 64 million people worldwide live with congestive heart failure. Ischemic heart disease is a factor in 41.5% of men and 22.1% of women with this condition. Chronic or repeated myocardial ischemia leads to cell death, scar tissue, and weaker heart muscle function. These changes can start heart failure. The chance of heart failure after a heart attack ranges from 14% to 36%. Ischemia in patients with existing heart failure can worsen symptoms, raise hospital admission rates, and lower prognosis. Knowing how ischemia contributes to heart failure is crucial for better diagnosis, more targeted treatments, and improved patient health.

Key words: Heart Failure; Coronary artery disease; Ischemia; Myocardial Infarction; Antianginal Drugs; Myocardial Hypertension.

INTRODUCTION

Heart failure is a clinical syndrome that develops when the heart fails to supply the body with a sufficient amount of blood to meet its metabolic demands. This change may be accompanied by structural and/or functional pathology manifested by a reduced cardiac output and/or increased intracardiac pressure. Heart failure is characterized by multiple symptoms that reduce a person's quality of life and decrease life expectancy: shortness of breath, lower leg edema, dyspnea, fatigue, pulmonary edema, ascites, hepatjugular reflux, etc [1, 2].

Based on modern data, more than 64 million people worldwide have heart failure [3, 4]. Echocardiographic screening has revealed that the prevalence of any heart failure in developed countries is 11.8% [5].

Heart failure can be divided into three classes based on left ventricular ejection fraction (LVEF), which measures the percentage of blood pumped from the left ventricle with each heartbeat. These are: heart failure with reduced ejection fraction (LVEF less than 40%), heart failure with moderately reduced ejection fraction (LVEF 40–49%), and heart failure with preserved ejection fraction (LVEF 50% or greater) [6].

Patients with heart failure can be assigned different classes and/or stages of heart failure. The New York Heart Association (NYHA) defines four classes of heart failure:

Class I: No physical limitation; ordinary physical activity does not cause symptoms of heart failure;

Class II: No symptoms at rest, but ordinary physical activities cause symptoms of heart failure;

Class III: No symptoms at rest, but less than ordinary physical activity causes symptoms of heart failure;

Class IV: Symptoms of heart failure at rest [7].

The prognosis worsens over time. In a study of 900,000 heart failure patients, survival rates were 81.3% at 1 year, 51.5% at 5 years, and 29.5% at 10 years [8]. This sharp decline highlights the need for timely and adequate treatment.

One of the main factors linked to heart failure and its worsening over time is ischemia. Ischemia means the heart muscle does not get enough blood or oxygen. The biggest cause is coronary artery disease (CAD).

Congestive heart failure is a common problem caused by ischemic heart disease. After high blood pressure, ischemic heart disease is the next biggest cause of congestive heart failure. Ischemic heart disease appears in 41.5% of men and 22.1% of women with congestive heart failure [9].

In ischemic heart disease, there is often a problem with the heart's ability to pump blood (pump function). This can be caused by several diseases or disorders, including: heart attack (myocardial infarction), brief episodes of reduced blood supply (acute transient ischemia), right ventricular dysfunction (problems with the right lower heart chamber), cardiogenic shock (severely reduced heart pumping leading to low blood pressure), sudden severe leakage of the mitral valve (acute mitral regurgitation), hole in the wall between the lower chambers (ventricular septal perforation), rupture of the heart wall (ventricular wall rupture), weakened heart muscle due to ongoing poor blood supply (ischemic cardiomyopathy), bulging of the heart wall (ventricular aneurysm), and complications from medical interventions (iatrogenic interventions) [10].

Myocardial ischemia decreases intracellular concentrations of high-energy phosphates and reduces calcium volume in the sarcoplasmic reticulum. This results in slowed and incomplete relaxation, reduced strength, and, therefore, the ischemic area stretches less. The left ventricular

filling pressure increases [11]. The ischemic region stretches less, and the non-ischemic region stretches more. According to the Frank-Starling law, the regional contractility of the latter is greater. In other words, the non-ischemic area tries to compensate for and "maintain" stroke volume [12].

When blood supply to the heart is reduced (ischemia), heart failure can begin to develop within a few hours (see Figure 1).

MYOCARDIAL HIBERNATION

Research now shows that when the heart muscle experiences deep ischemia, it can enter a state of hibernation. In the right conditions, the muscle can then recover its function. This discovery is a major advance in understanding ischemic heart disease, but, despite this progress, many questions about myocardial hibernation remain [13,14,15]. We still do not fully understand the biological processes involved, nor do we have a complete picture of the biochemical and ultrastructural changes that occur. The full extent and duration of functional recovery after restoring blood flow to the hibernating heart muscle are also only partially understood.

We have learned more about how the heart works during both "silent" and painful ischemia. Pain happens late in ischemia. The first signs are problems with the heart relaxing, followed by trouble with pumping. Only after these changes do pain and ECG changes appear.

This sequence is supported by clinical studies using exercise testing to induce ischemia. The early indicators are often shortness of breath (dyspnea) and a distinct atrial gallop, followed by hypotension and ST-segment depres-

sion. In some cases, pulmonary edema and ventricular arrhythmias may occur before any pain is felt. The presence of a strong collateral network—a system of alternative blood vessels—can sometimes contain the ischemia, preventing ST-segment depression and myocardial dysfunction altogether.

Hibernation is a protective mechanism the heart uses in response to long-term and severe ischemia (lack of blood supply). The purpose of hibernation is to help preserve the heart muscle during reduced coronary perfusion (blood flow through the heart's arteries). This is different from the body's quick adjustment responses. During ischemia, the heart changes its movement to use less energy, allowing it to maintain basic metabolic functions. It is very difficult to measure the levels of energy-storage molecules (phosphocreatine and adenosine triphosphate) in the hearts of living patients. One promising method is nuclear magnetic resonance imaging. Glucose (sugar) handling by the heart muscle can be studied with positron emission tomography (PET). In the hibernating heart muscle, glucose metabolism continues, and there are still energy reserves of adenosine triphosphate.

The discovery of myocardial hibernation, a tissue with the potential to recover function, is a significant issue and is essential for determining the indications for aortocoronary bypass surgery.

The period from reperfusion to functional recovery depends on the content of inorganic phosphorus in cardiomyocytes. The recovery of function in an exhausted segment is a long process [16]. Clinical observations show that this dysfunction is dynamic. Non-fibrotic myocardial

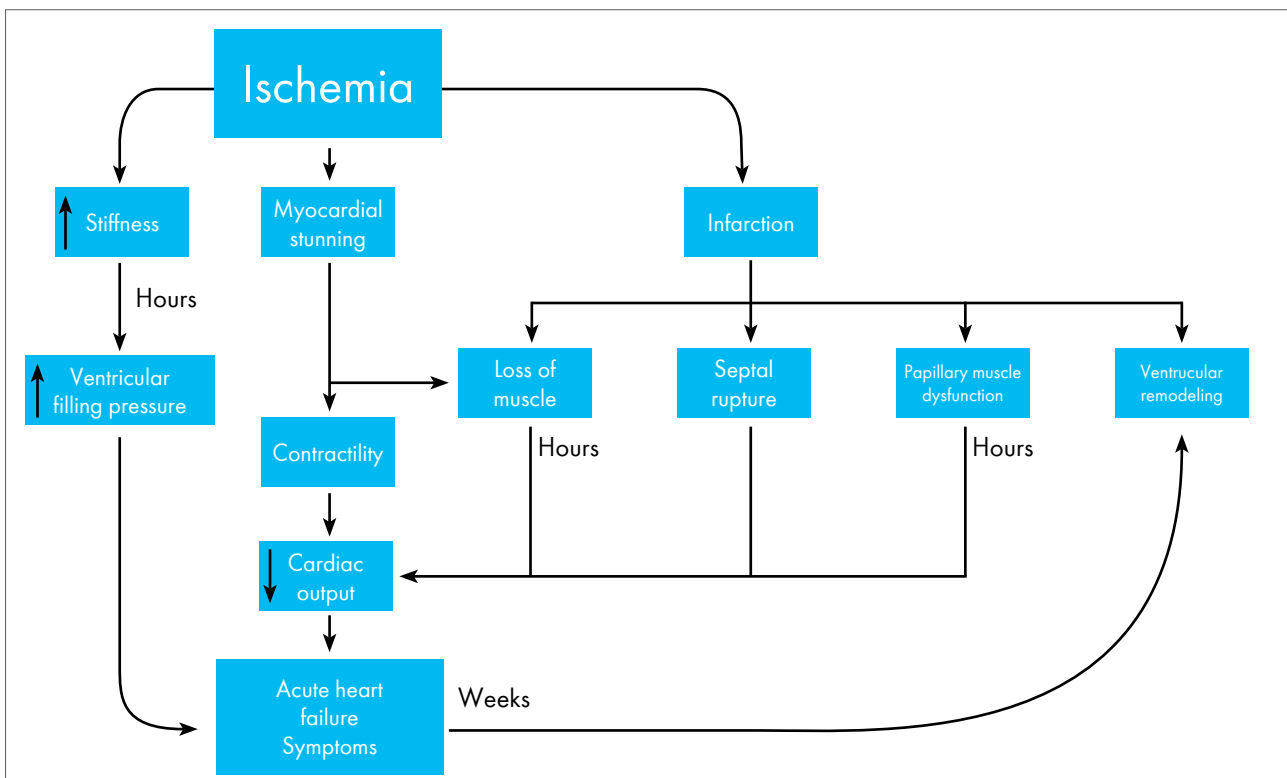


Figure 1. Factors contributing to the development of heart failure during ischemia

segments with normal histology but irreversible changes in the energy supply system may be in a state of permanent hibernation. This explains the discrepancy between the prevalence of the Q-wave and the zone of dysfunction. For example, it is known that the zone of dysfunction can be much more extensive than its corresponding Q-wave spread on the ECG. This has been demonstrated by positron emission tomography [17]. This same mechanism can explain the similar response of hibernating segments to the nitroglycerin test and revascularization processes [18]. The diagnosis of irreversible hibernation must be made with great caution, as functional recovery is possible long after reperfusion. The possibility of phased recovery has also been shown in animal experiments [13]. At the same time, it should be noted that the recovery of segments containing adenosine triphosphate is possible much sooner, which has been demonstrated by the results of transesophageal echocardiography performed during intraoperative examinations [19].

After blood flow is restored, the myocardium either recovers very quickly or remains stunned for a certain period, sometimes for a year or more. For reasons currently unknown, the myocardium lacks the ability to access the necessary substrate "within itself" to overcome total inactivation. The cause of this may be defects in enzymatic mechanisms or ultrastructural changes in the myocardium. The stages of development of dysfunctional myocardium are: [20, 21].

1) Myocardial Stunning

a) Myocardial stunning is a temporary dysfunction of the heart muscle that develops after a period of ischemia (reduced blood flow) but disappears once blood flow is restored.

b) This is similar to a skeletal muscle temporarily losing strength due to lack of oxygen and nutrients, but regaining strength when conditions improve.

c) Stunning is usually reversible within a few days, but repeated episodes can lead to hibernation.

2) Myocardial Hibernation

a) Myocardial hibernation is a condition in which the heart muscle is chronically underperfused, and its function at rest is persistently reduced.

b) This reduced function is a way for the heart muscle to adapt to the reduced blood supply and a survival attempt.

c) Myocardial hibernation can be reversed by revascularization (restoring blood flow).

d) If left unchanged, hibernating myocardium may turn into scar tissue.

3) Scar Formation (as a result of infarction)

a) Infarction is the irreversible death of heart muscle cells due to prolonged ischemia.

b) The damaged tissue is replaced by non-contractile scar tissue.

c) This is a permanent form of myocardial dysfunction.

d) Infarction can lead to heart failure if a sufficiently large area of the heart is damaged.

Myocardial hibernation can also occur in the presence of normal coronary arteries, due to toxic, inflammatory, or infiltrative processes, or as a result of long-term volume or pressure overload. This mechanism underlies secondary cardiomyopathies. The process of reducing the ejection fraction may later progress rapidly in cases of increasing aortic stenosis or insufficiency. Sometimes, an improvement in systolic function is noted long after surgical correction of the valvular apparatus. It is also possible to assume that hibernation occurs to limit myocardial oxygen consumption and restore the balance between oxygen supply and demand. Hibernation can also develop in hypertrophied myocardium when there is an imbalance between oxygen supply and consumption [22].

The issue of hibernation is a topic currently under discussion, with insufficient information available.

HEART FAILURE AND MYOCARDIAL INFARCTION

The probability of heart failure occurring after myocardial infarction ranges from 14% to 36% [23], and it significantly impacts patient survival. Myocardial ischemia, infarct size, left ventricular remodeling, and myocardial hibernation all play a crucial role in the development of left ventricular systolic dysfunction and reduced ejection fraction [23].

A study involving 4825 patients showed that in-hospital mortality was 1.87 times higher in patients with newly developed myocardial infarction who also had symptoms of heart failure [25].

The Global Registry of Acute Coronary Events (GRACE) collected data on patients with acute coronary syndromes (ACS) from 1999 to 2009. The registry's main goal was to provide a comprehensive, real-world understanding of the management and outcomes for the full spectrum of ACS, including unstable angina, non-ST-segment elevation myocardial infarction (NSTEMI), and ST-segment elevation myocardial infarction (STEMI). A study involving 13707 hospitalized patients in the registry with symptoms of heart failure found that they had a 2.2 times higher mortality rate compared to patients without these symptoms [26]. Based on this registry, the Killip classification system was developed to assess the risk of mortality from heart failure (see Table 1).

The FAST-MI registry showed similar results: in patients hospitalized for myocardial infarction, the presence of heart failure symptoms increased the risk of in-hospital mortality from 3% to 12.2%, and this risk increased from 5.2% to 26.6% over one year. It is also worth noting that 37.5% of hospitalized patients in this registry had symptoms of heart failure [27].

During hospitalization for myocardial infarction, symptoms of heart failure can be triggered by fluid and/or contrast overload, existing kidney damage, cardiac tamponade, or taking a prolonged horizontal position in the catheterization laboratory. The primary cause of heart

Table 1. Killip System Classes and Their Associated Risk of In-Hospital Mortality

Killip class	Symptoms	In-hospital mortality risk (%)
1	No symptoms of heart failure are observed	6
2	Auscultation revealed S3 heart sound and wheezing	17
3	Pulmonary edema	38
4	Cardiogenic shock	81

failure symptoms resulting from these factors is the death of cardiomyocytes and the development of scar tissue.

The acute decrease in heart contractility following an infarction can be caused by oxidative stress that develops in the presence of a blocked or narrowed coronary artery. In such conditions, restoring blood flow can improve heart contractility. However, if reperfusion is delayed by more than three hours, restoring blood flow can cause secondary damage due to the release of reactive oxygen species (ROS) [28].

The events that follow a myocardial infarction can be divided into two broad classes:

- Rapidly developing events that play a beneficial/compensatory role and
- later-developing events, where compensatory mechanisms play an active role in the development of heart failure symptoms.

The rapidly evolving events following an infarction aim to restore cardiac output and blood pressure and involve three compensatory mechanisms: the Frank-Starling mechanism, hyperactivation of the neurohumoral system, and activation of the renin-angiotensin-aldosterone system.

The Frank-Starling mechanism helps restore reduced cardiac output after an acute infarction. It is known that heart contractility changes with tissue stretch: when the tissue stretches, contractility increases; when it stretches too little or too much, contractility decreases. When the heart's pump function is disrupted and the ejection fraction is reduced due to a myocardial infarction, cardiac output also decreases, and left ventricular end-diastolic volume increases. Thanks to this change, the high end-diastolic volume activates the Frank-Starling mechanism, leading to an increase in the force of the subsequent contraction to restore cardiac output [29].

Hyperactivation of the neurohumoral system occurs due to baroreceptor stimulation from reduced systolic pressure. It includes the Bowditch effect, peripheral vasoconstriction, and blood redistribution. The Bowditch effect, also known as the Treppe phenomenon, is an increase in cytosolic calcium ion concentration associated with increased heart rate. This increase in calcium leads to increased contraction. In other words, each new contraction after a previous one is stronger, and as a result, this increased contractility is reflected as an increased cardiac output [30, 31]. The narrowing of peripheral blood vessels (both arteries and veins) leads to an increase in peripheral resistance, which increases blood pressure. This vasocon-

striction also centralizes blood flow, increasing blood supply to vital organs [32, 33].

Activation of the renin-angiotensin-aldosterone system occurs somewhat later than the two mechanisms mentioned above because it involves protein synthesis. Upon activation of this system, the body's retention of sodium increases, leading to an antidiuretic effect [34].

The rapidly evolving events that follow a myocardial infarction help stabilize the body hemodynamically. However, these mechanisms are not designed for long-term effects, and their hyperactivation can lead to more detrimental later-emerging events. The prolongation of these mechanisms over time gradually leads to the development of heart failure and is directed toward the complete collapse of the cardiovascular system [35]. These mechanisms include: hyperactivation of the neurohumoral system, hyperactivation of the renin-angiotensin-aldosterone system, the formation of fibrous tissue, oxidative stress, heart remodeling, and heart hypertrophy [36, 37, 38].

Long-term hyperactivation of the neurohumoral system leads to progressive desensitization of beta-adrenergic receptors and a decrease in their concentration in the heart. The synthesis of specific proteins responsible for excitation-contraction coupling and intracellular calcium regulation is also inhibited. As a result, the contractile force of the tissue and cardiac output are reduced [39].

The angiotensin II released due to hyperactivation of the renin-angiotensin-aldosterone system activates AT1 receptors, causes cardiac hypertrophy, and promotes the synthesis of fibrosis-promoting substances (cytokines, collagen) [40, 41].

Collectively, long-term hyperactivation of these systems can lead to water retention in the body, increased left ventricular end-diastolic pressure, increased left ventricular wall stress, increased left ventricular filling pressure, the formation of fibrous tissue, cardiac hypertrophy, and reduced cardiac output, all of which are factors contributing to the development of heart failure.

IMPACT OF ANTIANGINAL DRUGS ON LEFT VENTRICULAR SYSTOLIC FUNCTION

Antianginal drugs can be divided into three main groups:

1. Medications that reduce myocardial oxygen consumption by altering myocardial function (beta-blockers).
2. Medications that reduce myocardial oxygen consumption by regulating preload and afterload (nitrates).

3. Medications that improve myocardial blood supply by blocking the development of spasms and reducing myocardial oxygen consumption through changes in peripheral circulation (Ca²⁺ antagonists).

Beta-adrenergic receptor blockers reduce myocardial oxygen consumption by decreasing myocardial contractility, heart rate, and systolic pressure and by prolonging diastole. We know that in cases of acute coronary occlusion, propranolol reduces intraventricular pressure in both ischemic and non-ischemic areas. Intraventricular pressure decreases more sharply in normal areas than in ischemic areas [42]. It is also worth noting that the use of beta-adrenergic receptor blockers improves the contractility of ischemic myocardial areas during acute total coronary occlusion (see Table 2) [43].

A study involving 28039 patients with angiographically confirmed stable coronary artery disease, without heart failure or recent myocardial infarction, showed that beta-blockers were associated with a small but significant reduction in cardiovascular events after 5 years [44].

Research indicates that propranolol improves blood flow to the ischemic zone. The cardiodepressive effects of combined use of beta-blockers with glycosides and beta-blockers with nitroglycerin have been shown in patients with coronary occlusion [45]. It is also known that the cardiodepressive effect of beta-blockers is mediated by inhibiting endogenous sympathetic substances [46].

One study examined the results of intravenous administration of 5 mg of propranolol during cardiac catheterization in 10 patients. Four of them had angiographically confirmed coronary artery disease, while six did not have this pathology. Propranolol reduced the heart rate and cardiac index in all of them. In patients whose heart rate was under atrial stimulation control, the effect on end-diastolic pressure was variable. Two of the four patients with coronary disease and one patient with normal coronary arteries had an increase in end-diastolic pressure. End-diastolic pressure primarily increased, while the ejection fraction and the percentage of circumferential fiber shortening primarily decreased [47].

Studies also show that the ratio of the anginal period to the ejection period increased in patients with myocardial infarction under propranolol, from 0.377±0.1 to 0.409±0.03 (P<0.001) [48]. This effect is not exclusive to propranolol but is a general result of using beta-blockers [49].

The effect of beta-blockers on left ventricular hemodynamics is more pronounced during their acute use.

Radionuclide angiocardiology has shown that using increasing doses of propranolol (165 ± 13 mg) does not lead to a sharp change in the regional contractility of the left ventricular wall and ejection fraction [50]. It is also known that the ejection fraction and regional wall contractility do not change significantly after discontinuing propranolol before aortocoronary bypass surgery, at the peak of the drug action, and when it is used at an average dose [51].

The effect of labetalol on cardiovascular hemodynamics at rest and during physical exertion has also been studied in patients receiving long-term beta-blocker therapy. During the acute trial, there was a decrease in mean arterial pressure, heart rate, and cardiac index. The changes were even more pronounced during physical exertion. After 20 months of labetalol use, peripheral resistance was further reduced, while cardiac output improved (due to a relative increase in heart rate and an increase in stroke volume) [52].

Regarding nitrates, studies have shown that nitroglycerin does not alter or reduce stroke volume or cardiac output in patients with ischemic heart disease or healthy individuals (see Table 3) [53, 54, 55, 56].

The improvement in hemodynamics (stroke volume and cardiac output) with nitroglycerin is mainly dependent on the presence of left ventricular asynergy [56]. Hemodynamic improvement has been shown due to the disappearance of asynergic areas. The effect of nitroglycerin, like all other nitrates, is highly dependent on preload and afterload.

The effect of nitroglycerin on the global function of the left ventricle is variable. During oral administration, the hemodynamic effects of nitroglycerin are as follows:

Table 2. Effects of taking beta-blockers

General Parameter	Specific Parameter	Effect
Hemodynamic indicators	Heart rate	Decreases
	Left ventricular systolic pressure	Decreases
	Left ventricular end-diastolic pressure	Increases or does not change
	Stroke volume	Decreases
	Cardiac index	Decreases
Global functions of the left ventricle	Heart dimensions	Increases or does not change
	End-diastolic volume	Decreases
	Ejection fraction	Decreases
Regional functions of the left ventricle	Non-ischemic zone	Decreases
	Ischemic zone	Decreases or increases or does not change
	Left ventricular asynergy	Increases or does not change

Table 3. Effects of taking nitrates. The effect depends on the presence of congestive heart failure, left ventricular end-diastolic pressure, and reversed zones of asymptomatic

General Parameter	Specific Parameter	Effect
Hemodynamic indicators	Heart rate	Increases or does not change
	Left ventricular systolic pressure	Decreases
	Left ventricular end-diastolic pressure	Decreases
	Stroke volume	Decreases or increases or does not change
	Cardiac index	Decreases or increases or does not change
Global functions of the left ventricle	Heart dimensions	Decreases
	End-diastolic volume	Decreases or increases or does not change
	Ejection fraction	Decreases
Regional functions of the left ventricle	Non-ischemic zone	Decreases or increases or does not change
	Ischemic zone	Decreases
	Left ventricular asynergy	Increases or does not change

within the first 2 minutes, it decreases total peripheral resistance and cardiac output due to significant changes in left ventricular filling pressure and systemic arterial pressure. Then the heart rate increases. A decrease in filling pressure characterizes the second phase and, later, after 5 minutes, a decrease in arterial pressure. The heart rate reaches its peak, cardiac output decreases, and systemic arterial pressure returns to control values [54, 57].

The effects of nitroglycerin and other nitrates on regional left ventricular function are of interest for the treatment of coronary disease [58, 59]. In patients with angiographically confirmed coronary artery disease, zones of local contractility disorders and asynergic areas were found in 60-75% of cases in the left ventricle [60]. Nitroglycerin causes an improvement in myocardial contractility and the disappearance of asynergic zones. This is explained by the fact that nitroglycerin reduces preload, thereby eliminating the imbalance between myocardial oxygen consumption and supply. This is used as a test during ventriculography [61]. The nitroglycerin test can be used to predict the potential improvement of contractility in dyskinetic and akinetic areas after aortocoronary bypass surgery [62]. The effect of nitroglycerin on the asynergic regions of the ventricle that developed during a physical exercise test in patients with ischemic heart disease is also known—under the control of radionuclide angiography, it is known that nitroglycerin eliminates these areas and improves contrac-

tility [63]. Similar results have been obtained with patients who took prolonged nitrates, e.g., isosorbide dinitrate and pentaerythritol tetranitrate [64].

Based on studies, we know that Ca²⁺ antagonists reduce the zone of myocardial necrosis and improve systolic function after experimental coronary artery occlusion [65]. This fact is realized by reducing afterload, reducing myocardial oxygen consumption, improving coronary blood circulation due to the expansion of the coronary arteries, and also by reducing myocardial damage during ischemia by reducing the increased concentration of intracellular Ca²⁺ [66].

Ca²⁺ antagonists are the drugs of choice for coronary spasms, for example, Prinzmetal angina. These drugs are also prescribed for atherosclerotic narrowing of the coronary arteries to prevent coronary spasm and for their antiatherogenic action (see Table 4; Table 5; Table 6) [67].

In vitro, nifedipine has a negative inotropic effect. However, it has been shown to increase contractility during ischemia. During partial coronary occlusion, intravenous or intracoronary administration of nifedipine improves segmental subendocardial contractility in the ischemic zone. The mechanism behind this lies in the reduction of afterload through vasodilation and/or increased coronary blood flow, as well as reduced ischemia.

It is known that Ca²⁺ accumulates in mitochondria. Nifedipine improves myocardial contractility in the isch-

Table 4. Effects of taking nifedipine

General Parameter	Specific Parameter	Effect
Hemodynamic indicators	Heart rate	Increases or does not change
	Left ventricular systolic pressure	Decreases
	Left ventricular end-diastolic pressure	Decreases
	Stroke volume	Decreases or increases or does not change
	Cardiac index	Decreases or increases or does not change
Global functions of the left ventricle	Ejection fraction	Decreases
Regional functions of the left ventricle	Non-ischemic zone	Decreases or increases or does not change
	Ischemic zone	Decreases

Table 5. Effects of taking verapamil

General Parameter	Specific Parameter	Effect
Hemodynamic indicators	Heart rate	Does not change
	Left ventricular systolic pressure	Decreases
	Left ventricular end-diastolic pressure	Decreases or does not change
	Stroke volume	Increases
	Cardiac index	Increases
Global functions of the left ventricle	Ejection fraction	Decreases or does not change
Regional functions of the left ventricle	Non-ischemic zone	Decreases
	Ischemic zone	Not studied

Table 5. Effects of taking Diltiazem

General Parameter	Specific Parameter	Effect
Hemodynamic indicators	Heart rate	Decreases
	Left ventricular systolic pressure	Decreases
	Left ventricular end-diastolic pressure	Decreases or does not change
	Stroke volume	Increases
	Cardiac index	Decreases or increases
Global functions of the left ventricle	Ejection fraction	Not studied
Regional functions of the left ventricle	Non-ischemic zone	Not studied
	Ischemic zone	Increases

emic zone due to Ca²⁺ blockade in the mitochondria. This effect is dose-dependent. The effect of nifedipine on normal, non-ischemic myocardium is different.

It is also known that Diltiazem increases stroke volume and cardiac output and decreases total peripheral resistance and systemic arterial pressure [68]. These facts are dependent on the dose of the drug. Compared to verapamil and nifedipine, Diltiazem has a more pronounced vasodilatory effect and a less pronounced negative inotropic effect [69].

In summary, the interplay between ischemia and heart failure is a dynamic process involving a spectrum of myocardial responses, from temporary stunning to irreversible infarction. A comprehensive understanding of these mechanisms is vital for effective diagnosis and the development of targeted therapeutic strategies, including antianginal drugs, to improve the prognosis and quality of life for millions of people worldwide.

References:

- Kemp, C. D., & Conte, J. V. (2012). The pathophysiology of heart failure. *Cardiovascular Pathology*, 21(5), 365–371.
- Bozkurt, B., Coats, A. J. S., Tsutsui, H., Abdelhamid, M., Adamopoulos, S., Albert, N., Anker, S. D., Atherton, J., Bohm, M., Butler, J., & Drazner, M. H. (2021). Universal definition and classification of heart failure. *Journal of Cardiac Failure*, 27(4), 387–413.
- GBD Collaborators. (2017). Global, regional, and national incidence, prevalence, and years lived with disability for 354 diseases and injuries.
- Brauer, M. (2017). *The Global Burden of Disease Study 2017*.
- van Riet, E. E. S., Hoes, A. W., Wagenaar, K. P., Limburg, A., Landman, M. A. J., & Rutten, F. H. (2016). Epidemiology of heart failure. *European Journal of Heart Failure*, 18(3), 242–252.
- Paulus, W. J., & Tschöpe, C. (2013). A novel paradigm for heart failure with preserved ejection fraction. *Journal of the American College of Cardiology*, 62(4), 263–271.
- Yancy, C. W., Jessup, M., Bozkurt, B., Butler, J., Casey, D. E., Drazner, M. H., Fonarow, G. C., Geraci, S. A., Horwich, T., Januzzi, J. L., & Johnson, M. R. (2013). 2013 ACCF/AHA guideline for the management of heart failure. *Circulation*, 128(16), e240–e327.
- Jones, N. R., Roalfe, A. K., Adoki, I., Hobbs, F. D. R., & Taylor, C. J. (2019). Survival of patients with chronic heart failure. *European Journal of Heart Failure*, 21(11), 1306–1325.
- Vicent, L., Guerra, J., Vázquez-García, R., Gonzalez-Juanatey, J. R., Dolz, L. M., Segovia, J., Pascual-Figal, D., Bover, R., Worner, F., Delgado, J., & Fernandez-Aviles, F. (2021). Ischemic etiology and prognosis in men and women with acute heart failure. *Journal of Clinical Medicine*, 10(8), 1713.
- Cleland, J. G. F., & McGowan, J. (1999). Heart failure due to ischaemic heart disease. *Journal of Cardiovascular Pharmacology*, 33, S17–S29.
- Ingwall, J. S., Kramer, M. F., Fifer, M. A., Lorell, B. H., Shemin, R., Grossman, W., & Allen, P. D. (1985). The creatine kinase system in human myocardium. *New England Journal of Medicine*, 313(17), 1050–1054.
- Sasayama, S., Nonogi, H., Miyazaki, S., Sakurai, T., Kawai, C., Eiho, S., & Kuwahara, M. (1985). Changes in diastolic properties during ischemia. *Journal of the American College of Cardiology*, 5(3), 599–606.
- Heusch, G. (2021). Myocardial stunning and hibernation revisited. *Nature Reviews Cardiology*, 18(7), 522–536.

14. Bashour, T. T., Hanna, E. S., & Mason, D. T. (1986). Myocardial revascularization with internal mammary artery bypass: An emerging treatment of choice. *American Heart Journal*, 111(1), 143-151. [https://doi.org/10.1016/S0002-8703\(86\)80012-9](https://doi.org/10.1016/S0002-8703(86)80012-9)
15. Rahimtoola, S. H. (1989). The hibernating myocardium. *American Heart Journal*, 117(1), 211-221.
16. Rahimtoola, S. H. (1982). Coronary bypass surgery for chronic angina—1981: A perspective. *Circulation*, 65(2), 225-241. <https://doi.org/10.1161/01.CIR.65.2.225>
17. Tillisch, J., Brunken, R., Marshall, R., Schwaiger, M., Mandelkern, M., Phelps, M., & Schelbert, H. (1986). Reversibility of cardiac wall-motion abnormalities. *New England Journal of Medicine*, 314(14), 884-888.
18. Mintz, L. J., Ingels Jr, N. B., Daughters II, G. T., Stinson, E. B., & Alderman, E. L. (1980). Sequential studies of left ventricular function and wall motion after coronary arterial bypass surgery. *The American Journal of Cardiology*, 45(2), 210-216. [https://doi.org/10.1016/S0002-9149\(80\)80068-1](https://doi.org/10.1016/S0002-9149(80)80068-1)
19. Topol, E. J., Weiss, J. L., Guzman, P. A., Dorsey-Lima, S., Blanck, T. J., Humphrey, L. S., Baumgartner, W. A., Flaherty, J. T., & Reitz, B. A. (1984). Improvement after coronary revascularization. *Journal of the American College of Cardiology*, 4(6), 1123-1134.
20. Vaidya, Y., Cavanaugh, S. M., & Dharmoon, A. S. (2023). Myocardial stunning and hibernation. In *StatPearls [Internet]*. StatPearls Publishing. <https://www.ncbi.nlm.nih.gov/books/NBK560604/>
21. Gowda, R. M., Khan, I. A., Vasavada, B. C., & Sacchi, T. J. (2004). Reversible myocardial dysfunction. *International Journal of Cardiology*, 97(3), 349-353.
22. Myler, R. K., Shaw, R. E., Stertz, S. H., Bashour, T. T., Ryan, C., Hecht, H. S., & Cumberland, D. C. (1990). Unstable angina and coronary angioplasty. *Circulation*, 82(3 Suppl), I188-I195. <https://doi.org/10.1161/01.CIR.82.3.I188>
23. Hellermann, J. P., Jacobsen, S. J., Gersh, B. J., Rodeheffer, R. J., & Reeder, G. S. (2002). Heart failure after myocardial infarction. *American Journal of Medicine*, 113(4), 324-330.
24. Cleland, J. G., Torabi, A., & Khan, N. K. (2005). Epidemiology and management of heart failure and left ventricular systolic dysfunction in the aftermath of a myocardial infarction. *Heart*, 91(Suppl 2), ii7-ii13. <https://doi.org/10.1136/hrt.2004.042068>
25. Segev, A., Strauss, B. H., Tan, M., Mendelsohn, A. A., Lai, K., Ashton, T., Fitchett, D., Grima, E., Langer, A., & Goodman, S. G. (2006). Prognostic significance of admission heart failure in patients with non-ST-elevation acute coronary syndromes (from the Canadian Acute Coronary Syndrome Registries). *The American Journal of Cardiology*, 98(4), 470-473. <https://doi.org/10.1016/j.amjcard.2006.04.022>
26. Steg, P. G., Dabbous, O. H., Feldman, L. J., Cohen-Solal, A., Aumont, M. C., Lopez-Sendón, J., Budaj, A., Goldberg, R. J., Klein, W., & Anderson, F. A. (2004). Prognostic impact of heart failure. *Circulation*, 109(4), 494-499.
27. Juilliere, Y., Cambou, J. P., Bataille, V., Mulak, G., Galinier, M., Gibelin, P., Benamer, H., Bouvaist, H., Meneveau, N., Tabone, X., & Simon, T. (2012). Heart failure in acute myocardial infarction: A comparison between patients with or without heart failure criteria from the FAST-MI registry. *Revista Española de Cardiología (English Edition)*, 65(4), 326-333. <https://doi.org/10.1016/j.rec.2011.12.006>
28. Wilson, R. F., Johnson, M. R., Marcus, M. L., Aylward, P. E., Skorton, D. J., Collins, S., & White, C. W. (1988). The effect of coronary angioplasty on coronary flow reserve. *Circulation*, 77(4), 873-885. <https://doi.org/10.1161/01.CIR.77.4.873>
29. Ertl, G., Gaudron, P., Eilles, C., Schorb, W., & Kochsiek, K. (1991). Compensatory mechanisms for cardiac dysfunction in myocardial infarction. *Current Topics in Heart Failure: Experimental and Clinical Aspects*, 159-165.
30. Usman, A., Gandhi, J., & Gupta, G. (2023). Physiology, Bowditch Effect. In *StatPearls [Internet]*. StatPearls Publishing. <https://www.ncbi.nlm.nih.gov/books/NBK573948/>
31. Sutton, M. G. S. J., & Sharpe, N. (2000). Ventricular remodeling after myocardial infarction. *Circulation*, 101(25), 2981-2988.
32. Francis, J., Weiss, R. M., Wei, S. G., Johnson, A. K., & Felder, R. B. (2001). Progression of heart failure after myocardial infarction in the rat. *American Journal of Physiology-Regulatory, Integrative and Comparative Physiology*, 281(5), R1734-R1745. <https://doi.org/10.1152/ajpregu.2001.281.5.R1734>
33. Piña, I. L., Apstein, C. S., Balady, G. J., Belardinelli, R., Chaitman, B. R., Duscha, B. D., Fletcher, B. J., Fleg, J. L., Myers, J. N., & Sullivan, M. J. (2003). Exercise and heart failure: A statement from the American Heart Association Committee on Exercise, Rehabilitation, and Prevention. *Circulation*, 107(8), 1210-1225. <https://doi.org/10.1161/01.CIR.0000052636.20123.34>
34. Chiong, J. R., & Cheung, R. J. (2010). Loop diuretic therapy in heart failure: The need for solid evidence on a fluid issue. *Clinical Cardiology*, 33(6), 345-352. <https://doi.org/10.1002/clc.20738>
35. Braunwald, E. (2013). Heart failure. *JACC Heart Fail*, 1(1), 1-20. <https://doi.org/10.1016/j.jchf.2012.10.002>
36. Dhalla, N. S., Rangi, S., Babick, A. P., Zieroth, S., & Elimban, V. (2012). Cardiac remodeling in heart failure. *Heart Failure Reviews*, 17(4), 671-681.
37. Fukushima, A., Milner, K., Gupta, A., & Lopaschuk, G. D. (2015). Myocardial energy substrate metabolism in heart failure: From pathways to therapeutic targets. *Current Pharmaceutical Design*, 21(25), 3654-3664. <https://doi.org/10.2174/138920151202150713152119>
38. Münzel, T., Gori, T., Keaney, J. F., Maack, C., & Daiber, A. (2015). Role of oxidative stress in heart failure. *European Heart Journal*, 36(38), 2555-2564.
39. Swynghedauw, B. (1999). Molecular mechanisms of myocardial remodeling. *Physiological Reviews*, 79(1), 215-262.
40. Ferrario, C. M., & Schiffrin, E. L. (2015). Mineralocorticoid receptor antagonists. *Circulation Research*, 116(1), 206-213.
41. Abareshi, A., Norouzi, F., Asgharzadeh, F., Beheshti, F., Hosseini, M., Farzadnia, M., & Khazaei, M. (2017). Effect of angiotensin-converting enzyme inhibitor on cardiac fibrosis and oxidative stress status in lipopolysaccharide-induced inflammation model in rats. *International Journal of Preventive Medicine*, 8(1), 69. <https://doi.org/10.4103/2008-7802.196158>
42. Vatner, S. F., Baig, H., Manders, W. T., Ochs, H., & Pagani, M. (1977). Effects of propranolol on regional myocardial function, electrograms, and blood flow in conscious dogs with myocardial ischemia. *The Journal of Clinical Investigation*, 60(2), 353-360. <https://doi.org/10.1172/JCI108170>
43. Lekven, J. (1975). Effect of practolol on left ventricular dimensions during coronary occlusion. *The American Journal of Cardiology*, 36(2), 179-184. [https://doi.org/10.1016/S0002-9149\(75\)80084-4](https://doi.org/10.1016/S0002-9149(75)80084-4)
44. Godoy, L. C., Farkouh, M. E., Austin, P. C., Shah, B. R., Qiu, F., Jackevicius, C. A., Wijeysondera, H. C., Krumholz, H. M., & Ko, D. T. (2023). Beta-blocker therapy outcomes. *Journal of the American College of Cardiology*, 81(24), 2299-2311.
45. Raina, S., Banka, V. S., Ramanathan, K., Bodenheimer, M. M., & Helfant, R. H. (1978). Beneficial effects of propranolol and digitalis on contraction and ST-segment elevation after acute coronary occlusion. *The American Journal of Cardiology*, 42(2), 226-233.
46. Liang, C. S., & Hood, W. B. (1974). The myocardial depressant effect of beta-receptor blocking agents: Comparative study of dl-propranolol, d-propranolol, and practolol in awake dogs with and without acute myocardial infarction. *Circulation Research*, 35(2), 272-280.
47. Helfant, R. H., Kemp, H. G., & Gorlin, R. (1970). Coronary atherosclerosis, coronary collaterals, and their relation to cardiac function. *Annals of Internal Medicine*, 73(2), 189-193.
48. Ludbrook, P., Karliner, J. S., Kostuk, W., & O'Rourke, R. A. (1973). Effects of intravenously administered propranolol on wall motion abnormalities. *The American Journal of Cardiology*, 31(6), 712-717.

49. Bourdillon, P. D., Canepa-Anson, R., & Rickards, A. F. (1979). Hemodynamic effects of intravenous metoprolol. *The American Journal of Cardiology*, 44(6), 1195–1200.
50. Marshall, R. C., Berger, H. J., Reduto, L. A., Gottschalk, A., & Zaret, B. L. (1978). Variability in sequential measures of left ventricular performance assessed with radionuclide angiography. *The American Journal of Cardiology*, 41(3), 531–536.
51. Reduto, L. A., Berger, H. J., Cohen, L. S., Gottschalk, A., & Zaret, B. L. (1978). Sequential radionuclide assessment of left and right ventricular performance after acute transmural myocardial infarction. *Annals of Internal Medicine*, 89(4), 441–447.
52. Koch, G. (1979). Haemodynamic adaptation at rest and during exercise to long-term antihypertensive treatment with combined alpha- and beta-adrenoreceptor blockade by labetalol. *British Heart Journal*, 41(2), 192–198.
53. Wiener, L., Dwyer, E. M., & Cox, J. W. (1969). Hemodynamic effects of nitroglycerin, propranolol, and their combination in coronary heart disease. *Circulation*, 39(5), 623–632.
54. Williams, D. O., Amsterdam, E. A., & Mason, D. T. (1975). Hemodynamic effects of nitroglycerin in acute myocardial infarction. *Circulation*, 51(3), 421–427.
55. Hardarson, T., & Wright, K. E. (1976). Effect of sublingual nitroglycerin on cardiac performance in patients with coronary artery disease and non-dyskinetic left ventricular contraction. *Heart*, 38(12), 1272–1277.
56. Shah, R., Bodenheimer, M. M., Banka, V. S., & Helfant, R. H. (1976). Nitroglycerin and ventricular performance: Differential effect in the presence of reversible and irreversible asynergy. *Chest*, 70(4), 473–479.
57. Abrams, J. (1985). Hemodynamic effects of nitroglycerin and long-acting nitrates. *American Heart Journal*, 110(1), 217–224.
58. Banka, V. S., Bodenheimer, M. M., & Helfant, R. H. (1975). Nitroglycerin in experimental myocardial infarction: Effects on regional left ventricular length and tension. *The American Journal of Cardiology*, 36(4), 453–458.
59. Ramanathan, K. B., Bodenheimer, M. M., Banka, V. S., & Helfant, R. H. (1979). Severity of contraction abnormalities after acute myocardial infarction in humans: Response to nitroglycerin. *Circulation*, 60(6), 1230–1237.
60. Baxley, W. A., Jones, W. B., & Dodge, H. T. (1971). Left ventricular anatomical and functional abnormalities in chronic postinfarction heart failure. *Annals of Internal Medicine*, 74(4), 499–508.
61. Bodenheimer, M. M., Banka, V. S., & Helfant, R. H. (1980). Nuclear cardiology: Radionuclide angiographic assessment of left ventricular contraction. *The American Journal of Cardiology*, 45(3), 661–673.
62. Chesebro, J. H., Ritman, E. L., Frye, R. L., Smith, H. C., Rutherford, B. D., Fulton, R. E., Pluth, J. R., & Barnhorst, D. A. (1978). Regional myocardial wall thickening response to nitroglycerin. *Circulation*, 57(5), 952–957.
63. Borer, J. S., Bacharach, S. L., Green, M. V., Kent, K. M., Johnston, G. S., & Epstein, S. E. (1978). Effect of nitroglycerin on exercise-induced abnormalities of left ventricular function. *Circulation*, 57(2), 314–320.
64. Armstrong, P. W., Armstrong, J. A., & Marks, G. S. (1980). Pharmacokinetic-hemodynamic studies of intravenous nitroglycerin in congestive cardiac failure. *Circulation*, 62(1), 160–166.
65. Nagao, T., Matlib, M. A., Franklin, D., Millard, R. W., & Schwartz, A. (1980). Effects of diltiazem on regional myocardial function and mitochondria. *Journal of Molecular and Cellular Cardiology*, 12(1), 29–43.
66. Held, P. H., Yusuf, S., & Furberg, C. D. (1989). Calcium channel blockers in acute myocardial infarction and unstable angina. *British Medical Journal*, 299(6709), 1187–1192.
67. Purcell, H., Waller, D. G., & Fox, K. (1989). Calcium antagonists in cardiovascular disease. *International Journal of Clinical Practice*, 43(10), 369–379.
68. Flaim, S. F., & Zelis, R. (1980). Regional distribution of cardiac output in rats during exercise: Effects of diltiazem. *Chest*, 78(1), 187–192.
69. Chaffman, M., & Brogden, R. N. (1985). Diltiazem: A review of its pharmacological properties and therapeutic efficacy. *Drugs*, 29(5), 387–454.

გულის უკმარისობა და იშემია

გიორგი შაბურიშვილი¹, ნიკოლოზ შაბურიშვილი², სოლომონ ზეიციძე¹

¹საქართველოს დავით აღმაშენებლის სახ. უნივერსიტეტი, ²ილიას სახელმწიფო უნივერსიტეტი

პასუხისმგებელი პირი: გიორგი შაბურიშვილი, gigishab94@gmail.com

DOI: <https://doi.org/10.48412/GTBGS.2026.14-15.107-115>

რეზიუმე | გულის უკმარისობა რთული და პროგრესირებადი სინდრომი, რომელიც ხასიათდება გულის უუნარობით, გადატუმბოს საკმარისი სისხლი ორგანიზმის მეტაბოლური მოთხოვნილებების დასაკმაყოფილებლად. იშემია, სისხლის მიმოქცევისა და უანგბადის მიწოდების შეზღუდვის მდგომარეობა, გულის უკმარისობის განვითარებისა და პროგრესირების ერთ-ერთი მთავარი ხელშემწყობი ფაქტორია. ბოლოდროინდელი ანალიზი აჩვენებს, რომ მსოფლიოში 64 მილიონზე მეტი ადამიანი გულის შეფუთვითი უკმარისობით ცხოვრობს. ამ პირებიდან გულის იშემიური დაავადება მამაკაცების 41.5%-ში და ქალების 22.1%-ში ხელშემწყობი ფაქტორია. ქრონიკული ან მორეციდივე მიოკარდიუმის იშემია იწვევს მიოციტების სიკვდილს, ფიბროზულ რემოდელირებას და პარკუჭების ფუნქციის დარღვევას, რაც საბოლოოდ გულის უკმარისობის განვითარებას იწვევს. მიოკარდიუმის ინფარქტის შემდეგ გულის უკმარისობის განვითარების ალბათობა 14%-დან 36%-მდე მერყეობს. გარდა ამისა, დადგენილი გულის უკმარისობის ფონზე იშემიას შეუძლია კიდევ უფრო გაამწვავოს სიმპტომები, გაზარდოს ჰოსპიტალიზაციის მაჩვენებლები და გააუარესოს პროგნოზი. გულის უკმარისობის პათოგენეზში იშემიის კრიტიკული როლის გაგება აუცილებელია დიაგნოზის გასაუმჯობესებლად, მიზნობრივი თერაპიის შემუშავებისთვის და საბოლოოდ პაციენტების მდგომარეობის გასაუმჯობესებლად.

საკვანძო სიტყვები: გულის უკმარისობა; კორონარული არტერიის დაავადება; იშემია; მიოკარდიუმის ინფარქტი; ანტიანგინალური პრეპარატები; მიოკარდიუმის ჰიბერნაცია



მოთხრობა

*რა სწრაფად გადის დრო...
უკვე ერთ წელზე მეტი გავიდა,
რაც ჩვენი ქვეყნის სამედიცინო საზოგადოებამ
უდიდესი დანაკლისი განიცადა –
მის რიგებს გამოაკლდა საამაყო მამულიშვილი,
ექიმი და საზოგადო მოღვაწე, ბატონი
ავთანდილ ჯორბენაძე.*

ავთანდილ ჯორბენაძე

ბატონი ავთანდილი დაიბადა 1950 წლის 31 ოქტომბერს ქალაქ ლანჩხუთში. 1974 წელს დაამთავრა თბილისის სახელმწიფო სამედიცინო ინსტიტუტის სამკურნალო ფაკულტეტი, რის შემდეგ პრაქტიკოს ექიმად მუშაობდა თბილისის 29-ე პოლიკლინიკაში, სამხედრო ნაწილში და თბილისის პირველი კლინიკურ საავადმყოფოში. 1982-1986 წლებში იყო თბილისის პირველი კლინიკური საავადმყოფოს მთავარი ექიმის მოადგილე სამკურნალო დარგში, 1986-1991 წლებში – თბილისის სახალხო დეპუტატთა საქალაქო საბჭოს აღმასკომის ჯანმრთელობის დაცვის სამმართველოს უფროსის პირველი მოადგილე, ხოლო 1991-1992 წლებში – ამავე სამმართველოს უფროსი. 1992-1993 წლებში ის იყო საქართველოს რესპუბლიკის ჯანმრთელობის დაცვის მინისტრის მოადგილე და ამავე პერიოდში, აფხაზეთის კონფლიქტის დროს ხელმძღვანელობდა ფრონტის სამხედრო-სამედიცინო სამსახურს. 1993 წლიდან 2001 წლებში მუშაობდა ჯერ საქართველოს ჯანმრთელობის დაცვის, ხოლო შემდეგ საქართველოს შრომის, ჯანმრთელობისა და სოციალური დაცვის მინისტრის თანამდებობაზე. 2001-2003 წლებში იყო საქართველოს სახელმწიფო მინისტრი. 2011 წლიდან სიცოცხლის ბოლომდე მუშაობდა აკად. გ.ჩაფიძის სახელობის გადაუდებელი კარდიოლოგიის ცენტრის სამეთვალყურეო საბჭოს თავმჯდომარედ.

ბატონმა ავთანდილმა მთელი თავისი ცხოვრება ადამიანების ჯანმრთელობაზე ზრუნვაში გაატარა, თავდაუზოგავად იბრძოდა სხვების დასახმარებლად. უსაზღვროდ უყვარდა თავისი საქმე. უდიდეს პატივს

სცემდა უფროს კოლეგებს და განუზომელ დახმარებას უწევდა ახალგაზრდებს. გაჭირვებაში გვერდით დგომაც განსაკუთრებული იცოდა, სხვა რომ ვერავინ ახერხებდა, ისეთი. ლხინსა და სიხარულში კი ლაღი და მოსიყვარულე იყო, საუბარს საოცრად დახვეწილი, მხოლოდ მისთვის ჩვეული თბილი იუმორით აფერადებდა.

ბატონი ავთანდილი უდიდესი ორგანიზაციული ნიჭით იყო დაჯილდოვებული, რომელიც განსაკუთრებით გამოადგა აფხაზეთის კონფლიქტის დროს. ვინ მოთვლის რამდენი დაჭრილი მეომრის გადარჩენა გახდა შესაძლებელი მის მიერ ორგანიზებული და კოორდინირებული სამხედრო-სამედიცინო სამსახურის მიერ. ბუნებით ნოვატორი, სირთულეების გადალახვის პროცესში, ის მუდამ ახალი მიდგომების ძიებაში იყო. ამის ერთ-ერთი მაგალითი იყო ბატონი ავთანდილის მიერ 1992 წლის მარტში სოხუმის პირველ საავადმყოფოში ჩატარებული სამხედრო-საველე ქირურგიის აქტუალური საკითხებისადმი მიძღვნილი სამეცნიერო-პრაქტიკული კონფერენცია. მასში მონაწილეობას იღებდნენ ქართველი და აფხაზი ქირურგები და სხვა პროფილის ექიმები. კონფერენციაზე განსაკუთრებული ყურადღება დაეთმო ანტიბიოტიკების მუდმივი დეფიციტის ფონზე, ჭრილობების ინფიცირებისგან დაცვის პრობლემას, რომლის მოგვარებაშიც სერიოზული წვლილი შეიტანა ცნობილი მიკრობიოლოგის, აკადემიკოს თამაზ კერესელიძის და საქართველოს მთავარი ქირურგის, პროფესორ გურამ გვასალიას მიერ სანგრებში გავრცელებული მიკროფლორის შეისწავლის საფუძველზე დამზადებულმა ფაგებმა.

ბატონი ავთანდილის მიერ იქნა პრაქტიკაში დანერგული „სამედიცინო დიპლომატია“, რომელსაც ხშირად იყენებდა პოსტკონფლიქტურ პერიოდში აფხაზეთისა და სამაჩაბლოს ოკუპირებულ ტერიტორიებზე მცხოვრები ყველა ეთნიკური ჯგუფის წარმომადგენელთა სამედიცინო მომსახურებით უზრუნველსაყოფად.

განუზომელია ბატონი ავთანდილის დამსახურება გაპარტახების პირას მისული საქართველოს ჯანმრთელობის დაცვის სისტემის გადარჩენისა და აღორძინების საქმეში. ჯანმრთელობის დაცვის სისტემაში გატარებული ცვლილებებისა და რეფორმების წყალობით, გახედული, ხშირად მტკივნეული, მაგრამ აუცილებელი ნაბიჯების გადადგმით საყოველთაო აღიარება ძალიან სწრაფად მოიპოვა. მის სახელს უკავშირდება ჯანმრთელობის დაცვის სისტემის საკანონმდებლო ბაზის ფორმირება, დაფინანსების პროგრამული და მიზნობრივ-პროგრამული მეთოდების დანერგვა, სადაზღვევო მედიცინის პრინციპებზე გადასვლა, საზოგადოებრივი ჯანდაცვის სამსახურის ჩამოყალიბება და პირველადი ჯანდაცვის სისტემის საოჯახო მედიცინის პრინციპებზე გადაყვანა, უმაღლესი სამედიცინო განათლების სისტემის რეფორმირება, რეზიდენტურისა და სერტიფიცირების შემოღება, სამედიცინო მეცნიერების გრანტული დაფინანსება, წამალპოლიტიკის რეფორმა, კერძო სექტორის ჩამოყალიბება, სამედიცინო საინფორმაციო სამსახურის რეფორმა.

ქვეყანაში არსებული მძიმე ეკონომიკური მდგომარეობის მიუხედავად, ბატონი ავთანდილის ძალისხმევით შესაძლებელი გახდა საქართველოში დიაგნოსტიკისა და მკურნალობის მაღალტექნოლოგიური მეთოდების დანერგვა. მისი განსაკუთრებული ყურადღების ობიექტი იყო კარდიოქირურგია. 1996 წლის 16 სექტემბერს თბილისის ბავშვთა მე-2 საავადმყოფოს ბაზაზე გაიხსნა ბავშვთა კარდიოქირურგიის ცენტრი, რომლის ფართის გამოყოფა და რემონტი საქართველოს მხარემ, ხოლო აღჭურვა და პერსონალის მომზადება აშშ-ის არასამთავრობო ორგანიზაციამ Global Healing-მა განახორციელა და მას მოგვიანებით ამ ორგანიზაციის პრეზიდენტის, ქალბატონ ჯო ენ მაკგოგენის სახელი მიენიჭა.

1997 წლიდან საქართველოს ჯანმრთელობის დაცვის სამინისტროს ორ დაწესებულებაში – გადაუდებელი კარდიოლოგიის ცენტრში (დირექტორი – აკადემიკოსი გულნარა ჩაფიძე) და აკადემიკოს კონსტანტინე ერისთავის სახელობის ექსპერიმენტული და კლინიკური ქირურგიის ინსტიტუტში (დირექტორი – პროფესორი ბაადურ მოსიძე), ასევე უცხოელი პარტნიორების, კერძოდ, გერმანიიდან – ბად კროცინგენის გულის ცენტრის (დირექტორი – პროფესორი ჰ.როსკამი), შვეიცარიიდან – ჟენევის „ჰოსპიტალ დე ლა ტურის“ (კარდიოქირურგიის დეპარტამენტის ხელმძღვანელი, პროფესორი ვ.ველეზიტი) და პოლონეთის სილეზიის აკადემიის კარდიოქირურგიის კლინიკის (დირექტორი – პროფესორი ზ.რელივა) დახმარებით გაიხსნა კარდიოქირურგიული განყოფილებები.

გასაგებია, რომ კარდიოქირურგიის ცენტრების ფუნქციონირებას მნიშვნელოვანი ფინანსური რესურსები ესაჭიროებადა, რომელთა გამონახვა, იმ პერიოდში არსებული ეკონომიკური მდგომარეობის ფონზე, არც

თუ ისე იოლი საქმე იყო. ბატონმა ავთანდილმა შეძლო ქვეყნის მთავრობისა და პარლამენტის დარწმუნება, რომ 1997 წლის ბიუჯეტში შეტანილი ყოფილიყო „ბავშვთა კარდიოქირურგიული დახმარების სახელმწიფო პროგრამა“, ხოლო 1998 წლის ბიუჯეტში მას „გულის იშემიური დაავადებების ქირურგიული მკურნალობისა და ორგანოთა ტრანსპლანტაციის სახელმწიფო პროგრამა“ დაემატა.

როგორც ამ უკანასკნელი პროგრამის სახელწოდება გვიჩვენებს, ბატონი ავთანდილის ყურადღების მიღმა არც ორგანოთა ტრანსპლანტაცია დარჩენილა და 1998 წელს უკვე შესაძლებელი გახდა თირკმლის გადანერგვის ოპერაციების დაწყება.

ბატონ ავთანდილის აღიარება და წარმატება თავდაუზოგავი შრომისა და განუზომელი შინაგანი ენერჯის ხარჯვის შედეგი იყო. მას არასოდეს ღალატობდა ღრმა მეცნიერულ კვლევებზე და ექსპერტთა მოსაზრებებზე დამყარებული ალლო და პროგნოზირების გასაოცარი უნარი. ამავე დროს ის იყო მეტად კომუნიკაბელური პიროვნება, რომელსაც შეეძლო მეგობრული ურთიერთობების დამყარება განვითარებული ქვეყნების მაღალი რანგის პოლიტიკოსებთან და საერთაშორისო ორგანიზაციების ხელმძღვანელებთან, რომელთა ფინანსური და ტექნიკური დახმარება მეტად მნიშვნელოვანი იყო საქართველოს ჯანმრთელობის დაცვის სისტემის განვითარებისა და სამედიცინო მომსახურების ხარისხის გაუმჯობესებაში.

ბატონი ავთანდილი მაქსიმალურად უწყობდა ხელს სამედიცინო მეცნიერებისა და ტექნოლოგიების საქართველოში დანერგვას. სწორედ მისი მინისტრობის პერიოდში განვითარდა ისეთი მიმართულებები, როგორცაა ენდოსკოპიური ქირურგია, ინტერვენციული მედიცინა, ენდოვასკულური ქირურგია, ხელოვნური სახსრების ინპლანტაცია, ლითოტრიფსია და მრავალი სხვა. ის თვლიდა, რომ საქართველოს მოქალაქეები იმსახურებენ მაღალი ხარისხის, კვალიფიციური სამედიცინო დახმარების მიღების უფლებას და ამის მისაღწევად ძალ-ღონეს არ იშურებდა მთელი თავისი შეგნებული ცხოვრების განმავლობაში.





IN MEMORIAM

AVTANDIL JORBENADZE

Time passes quickly. Over a year has passed since the Georgian medical community lost Mr. Avtandil Jorbenadze, a respected physician and public figure.

Avtandil Jorbenadze was born on 31 October 1950 in Lanchkhuti. In 1974, he graduated from the Faculty of General Medicine of the Tbilisi State Medical Institute, after which he worked as a practicing physician at Tbilisi Polyclinic No. 29, in a military unit, and at the First Clinical Hospital of Tbilisi. From 1982 to 1986, he served as Deputy Chief Physician for Clinical Affairs at the First Clinical Hospital of Tbilisi. Between 1986 and 1991, he was First Deputy Head of the Health Protection Department of the Executive Committee of the Tbilisi City Council of People's Deputies, and from 1991 to 1992, he headed that same department. In 1992–1993, he served as Deputy Minister of Health of the Republic of Georgia and, during that same period — the time of the Abkhazian conflict — led the military medical service of the front. From 1993 to 2001, he served first as Minister of Health and subsequently as Minister of Labor, Health, and Social Affairs of Georgia. In 2001–2003, he served as Georgia's State Minister. From 2011 until his death, he served as Chairman of the Supervisory Board of the Acad. G. Chapidze Emergency Cardiology Center.

Mr. Avtandil dedicated his life to helping others. He is fully committed to his work. He deeply respected his senior colleagues and supported younger ones. In hard times, he stood by others. In good times, he shared warmth and humor.

Mr. Avtandil had strong organizational skills, which were vital during the Abkhazian conflict. He organized the military medical service that saved many wounded soldiers. Always seeking solutions, he organized a major 1992 conference on military field surgery in Sukhumi. There, Georgian and Abkhazian surgeons discussed wound infections and antibiotic shortages. Bacteriophage preparations, developed by Academician Tamaz Kereselidze and Professor Guram Gvasalia, addressed this challenge.

Mr. Avtandil introduced „medical diplomacy“ to deliver medical care to all ethnic groups in Abkhazia and South Ossetia after the conflict.

Mr. Avtandil helped save and rebuild Georgia's healthcare system. Through his reforms and necessary but difficult decisions, he earned wide recognition. He shaped healthcare legislation, introduced new financing methods, established public health services, and reformed medical education, science funding, pharmaceutical policy, and medical information services.

Despite the country's severe economic problems, Mr. Avtandil helped introduce high-tech medical methods in Georgia. He focused on cardiac surgery. On 16 September 1996, Georgia opened a Pediatric Cardiac Surgery Center at the Second Children's Hospital, with local support and equipment and training from Global Healing. The center was named after Jo Ann McGowan.

From 1997, cardiac surgery departments were established at two institutions of the Georgian Ministry of Health: the Emergency Cardiology Center (Director: Academician Gulnara Chapidze) and the Acad. Konstantin Eristavi Institute of Experimental and Clinical Surgery (Director: Professor Baadur Mosidze). Both benefited from international partners' assistance. These included the „Herz-Zentrum Bad Krozingen“ in Germany (Director: Prof. Dr. Helmut Roskamm), the Hôpital de la Tour in Geneva, Switzerland (Head of the Department of Cardiac Surgery: Prof. Vladimir Velebit, MD), and the Cardiac Surgery Clinic of the Silesian Academy of Medicine in Poland (Director: Prof. Zbigniew Religa).

Operating cardiac surgery centers required major funding, which was difficult to obtain. Mr. Avtandil convinced the government and parliament to fund the State Program for Pediatric Cardiac Surgery in 1997. In 1998, funding expanded to cover surgical treatment of ischaemic heart disease and organ transplantation. By 1998, Georgia began kidney transplantation.

Mr. Avtandil's tireless work and strong energy led to his success. He used analytical skills and provided guidance to inform decisions. He built effective relationships with politicians and international leaders, which brought important assistance to Georgia's healthcare system.

Mr. Avtandil strongly supported the spread of medical science and technology in Georgia. As Minister, he developed fields like endoscopic surgery, interventional medicine, endovascular surgery, joint replacement, and lithotripsy. He believed Georgians deserved high-quality care and worked hard to provide it.

The memory of Avtandil Jorbenadze—physician, statesman, and public servant—remains with everyone who knew and worked with him.

Gr. Mukhadze Georgian Association of Surgeons

აკადემიკოსი
მიხეილ ივანეს ძე დავიძოვი

АКАДЕМИК ДАВЫДОВ МИХАИЛ ИВАНЫЧ
ACADEMICIAN MIKHAIL IVANOVICH DAVYDOV

1947 - 2025



სამკიბრის წერილი

მინდა გამოვხატო ჩემი ღრმა მწუხარება ჭეშმარიტად ლეგენდარული პიროვნების – აკადემიკოს მიხეილ ივანეს ძე დავიძოვის გარდაცვალებას გამო. დანაკარგი განუზომელია არა მხოლოდ მისი კოლეგების, პაციენტებისა და ახლობლებისთვის, არამედ მთლიანად სამედიცინო საზოგადოებისთვის, თითოეული ჩვენთაგანისთვის. ბატონი მიხეილი ქირურგიის ისტორიაში ნამდვილად არაჩვეულებრივი ფიგურა იყო: ბრწყინვალე დასტაქარი, რომლისთვისაც ქირურგიაში არ არსებობდა საზღვრები, ნიჭიერი მეცნიერი, საოცარი მასწავლებელი და არასტანდარტული ხელმძღვანელი.

მე დავალეული ვარ მისგან და თავს ბედნიერად ვთვლი, რომ 5 წელი ვიმუშავე ბატონი მიხეილის ხელმძღვანელობით სსრკ მედიცინის მეცნიერებათა აკადემიის ონკოლოგიის საკავშირო სამეცნიერო ცენტრში, ჩემი დოქტორანტურის პერიოდში. ის გაცილებით მეტი იყო, ვიდრე უბრალოდ სამეცნიერო ხელმძღვანელი – ის იყო ცხოვრების მეგობარი, ნამდვილი მეგობარი და პროფესიონალიზმის მაგალითი. არასდროს დამავიწყებდა მისი მამობრივი მზრუნველობა ჩემს მიმართ, არც მისი გამოსვლა აკადემიურ საბჭოში ჩემი სადოქტორო დისერტაციის დაცვის. კიდევ ბევრი რამის თქმა შემიძლია...

დაგვიანებული, მაგრამ გულწრფელი მადლობა ყველაფრისთვის, ძვირფასო მიხეილ ივანეს ძე. მშვიდად განისვენე.
მარად შენი მერაბი (ყველაზე საყვარელი დოქტორანტი, როგორც მეძახდი).

ღრმა პატივისცემით,
პროფესორი მერაბ კილაძე (თბილისი, საქართველო)
ივანე ჯავახიშვილის სახელობის თბილისის სახელმწიფო უნივერსიტეტის
კლინიკური ქირურგიის დეპარტამენტის ხელმძღვანელი,
„ამერიკული ჰოსპიტალი თბილისის“ ქირურგიის დეპარტამენტის ხელმძღვანელი

ПИСЬМО - СОБОЛЕЗНОВАНИЕ

Выражаю свои самые глубокие соболезнования по поводу смерти легендарной личности – академика Давыдова Михаил Ивановича! Его смерть – невосполнимая утрата не только для многочисленных коллег, пациентов, близких, для всей системы здравоохранения, но и для всех нас. Это была действительно необыкновенная личность в истории хирургии. Блестящий хирург, для которого не существовало границ и ограничений в хирургии, талантливый ученый, прекрасный педагог и нестандартный руководитель. Я многим ему обязан и счастлив, что 5 лет довелось работать под его началом в ВОНЦ АМН СССР во время докторантуры. Он был не только моим научным руководителем, но и руководителем по жизни, по дружбе, по профессии. Никогда не забуду его отеческую заботу обо мне и его выступление на совете при защите моей докторской диссертации. Много чего могу вспомнить...

Запоздалое спасибо за все дорогой Михаил Иванович! Пусть земля будет тебе пухом!
Твой Мераб (самый любимый докторант, как ты называл меня).

С уважением,
Профессор Мераб Киладзе (Тбилиси, Грузия)
Зав.кафедрой клинической хирургии ТГУ им.И.Джавახишвили
Руководитель Департамента Хирургии "Американский Госпиталь Тбилиси"

LETTER OF CONDOLENCE

I wish to express my deepest condolences on the passing of a truly legendary figure — Academician Mikhail Ivanovich Davydov. His loss is immeasurable — not only for his countless colleagues, patients, and loved ones, or for the medical community as a whole, but for all of us who had the privilege of knowing him. He was a genuinely extraordinary presence in the history of surgery: a brilliant surgeon who recognized no boundaries in his craft, a gifted scientist, an inspiring teacher, and a remarkably unconventional leader.

I owe him more than words can express, and I consider myself fortunate to have spent five years working under his mentorship at the Cancer Research Center of the USSR Academy of Medical Sciences during my doctoral studies. He was far more than a scientific supervisor — he was a guide in life, a true friend, and a model of what it means to be a professional. I will never forget his fatherly care for me, nor his words at the academic council during the defense of my doctoral dissertation. There is so much more I could say...

A belated, but heartfelt thank you for everything, dear Mikhail Ivanovich. May you rest in peace.
Yours always, Merab — your most beloved doctoral student, as you used to call me.

With deepest respect,
Professor Merab Kiladze (Tbilisi, Georgia)
Head of Department of Clinical Surgery, Ivane Javakhishvili Tbilisi State University
Head of Department of Surgery, "American Hospital Tbilisi"

THE RULES OF SUBMITTING AN ARTICLE TO THE JOURNAL "GURAM TATISHVILI BULLETIN OF GEORGIA SURGERY":

1. An article shall be submitted in printed form, two copies, in the Georgian (English or Russian) language together with an e-version of an article on electronic media (CD, DVD, flash memory).
2. Printed version shall be on one page of a standard sheet of paper (A4), by maintaining 2,5 cm left field width, 2-2 cm upper and bottom fields and 1,5 cm right field width. Space between lines 1,5.
3. An article shall be typed in MS Word by Sylfaen Unicode font, both Georgian main text and Georgian and English reviews. Font size shall be 11.
4. Submitted material volume shall not be less than 7 pages and more than 20 pages including tables, diagrams, illustrating material, reference list and reviews (in the Georgian and English languages).
5. A research article shall include the following sections: urgency of the research, research objective, research material and applied methods, obtained results and their discussion.
6. When submitting results of experimental researches, it is mandatory to point out and describe types of experimental animals and quantity; methods of anaesthesia (in conditions of acute experiments).
7. An article in Georgian language shall be enclosed with review in the Georgian and English languages. In case of an article in foreign language – only in the English language. Volume of a review shall not be less than 130 and not more than 250 words. In the English review, it is mandatory to mention: title, authors' surnames with initials, representing institution or work institutions of authors (an author's connection with an institution in case of several authors or institutions shall be interpreted by figure). A review shall include the following sections (highlighted in text): objective, material and methods, results and conclusions; key words.
8. Rules of illustrating an article:
 - Tables shall be submitted in printed and e-form (and not in any of an image formats – e.g. jpg, tiff, pdf). A table shall be drawn up in MS Word or MS Excel formats, can be inserted in text or submitted as a separate file, in this case the file shall be named: table p...; all digital, summing and percentage data shall correspond with the ones mentioned in text.
 - Diagrams shall be titled, numbered and pointed out in corresponding place in text. Diagrams can be submitted both in MS Word or MS Excel formats, as well as in jpg, tiff, pdf formats. Diagram inscriptions shall be made in the Georgian language.
 - Photographs, pictures, drawings shall be submitted as contrast file, in jpg, tiff, pdf formats. Resolution degree not less than 200dpi.
 - Photocopies shall be submitted with positive image in jpg, tiff, pdf format, titled, numbered and pointed out in the corresponding place in text. Resolution degree not less than 200dpi.
 - In inscriptions of microphotographies, it is necessary to point out zooming degree by eyepiece or lens, dying or impregnation method of slices and note upper and lower parts of an image.
9. Authors' surnames in an article are mentioned by enclosing initials.
10. An article shall be enclosed with bibliographic list of used works (with depth of 5-8 years).
 - Bibliographic list shall be sorted by alphabetic order;
 - Authors (surname, initials, title of an article, journal name, year, journal p, the first and the last pages) are pointed out. Use the APA style. <https://apastyle.apa.org/style-grammar-guidelines/references/examples>
 - In case of monography point out publishing year, place an total quantity of pages.
 - In text, in round brackets shall be pointed out an author's corresponding p, according the reference list.
11. The editorial team keep the right to correct an article. Working on text and summing is done in accordance with the copyright original.
12. It is not allowed to submit an article published in other publications.
13. In case of violating the mentioned rules, articles are not reviewed.

Editorial team of "Guram Tatishvili Bulletin of Georgia Surgery"